B-cell acute lymphoblastic leukemia and juvenile xanthogranuloma in a patient with *ETV6* thrombocytopenia and leukemia predisposition syndrome: novel clinical presentation and perspective

ETV6-thrombocytopenia predisposition syndrome is a rare cancer predisposition with varying penetrance, which portends increased risk of hematologic malignancy. Here we present the unusual case of a patient with a novel pathogenic variant in *ETV6* who developed both B-cell acute lymphoblastic leukemia (B-ALL) and an intracranial non-Langerhans cell histiocytic neoplasm.

Case

A 7-year-old Hispanic girl with fever and leg pain was diagnosed with standard-risk B-ALL. Diagnostic leukemia karyotype revealed hyperdiploid ALL with favorable trisomies (55, XX, +X, +4, +10, del(12)(p11.2), +add(12)(p13),+14, +add(17)(q25),+18,+20,+21[4]/46,XX[18]). She was treated on the Children's Oncology Group (COG) clinical trial AALL0932[1] with negative minimal residual disease (MRD) at the end of induction. Unfortunately, 10 months off therapy she experienced a combined bone marrow and central nervous system relapse. Chromosomal microarray redemonstrated hyperdiploid ALL with similar trisomies as observed at diagnosis. She was subsequently treated on COG AALL1331,[2] randomized to the low-risk arm with blinatumomab.[3] She underwent whole brain radiation therapy (1,800 cGY) administered in ten fractions at month 12, with total duration of relapsed ALL therapy of 2 years.

At age 15, she presented to our Emergency Department with 2 weeks of headache and right eye pain, as well as fever and myalgias. Her vital signs and physical exam were reassuring, notable only for a baseline non-reactive right pupil and disconjugate gaze. Laboratory studies revealed a normal complete blood count, including normal platelet count of 180×10^9/L. A head computerized tomography scan and subsequent magnetic resonance imaging (MRI) demonstrated a well-circumscribed area of hyperattenuation within the left temporal lobe (1.7x1.4x1.4 cm) with surrounding edema and regional mass effect (Figure 1A). The patient subsequently underwent a bone marrow biopsy and lumbar puncture, revealing no evidence of recurrent leukemia. Temporal lobe biopsy demonstrated sheets of histiocytic cells, including frequent giant cell forms with occasional Touton-type giant cells. Immunohistochemical stains showed that the histiocytic cells expressed CD68, CD163 and Factor XIII and were associated with a low Ki67 proliferation index (<5%). A diagnosis of intraparenchymal juvenile xanthogranuloma (JXG) was rendered. Next-generation sequencing (NGS) analysis of the tumor detected *ARHGEF2::NTRK1* fusion (Figure 2), which has been previously reported in other central nervous system (CNS) tumors.[4] A skeletal survey revealed no bony disease. Tumor/normal (blood) NGS panel of 238 cancer genes[5] demonstrated a

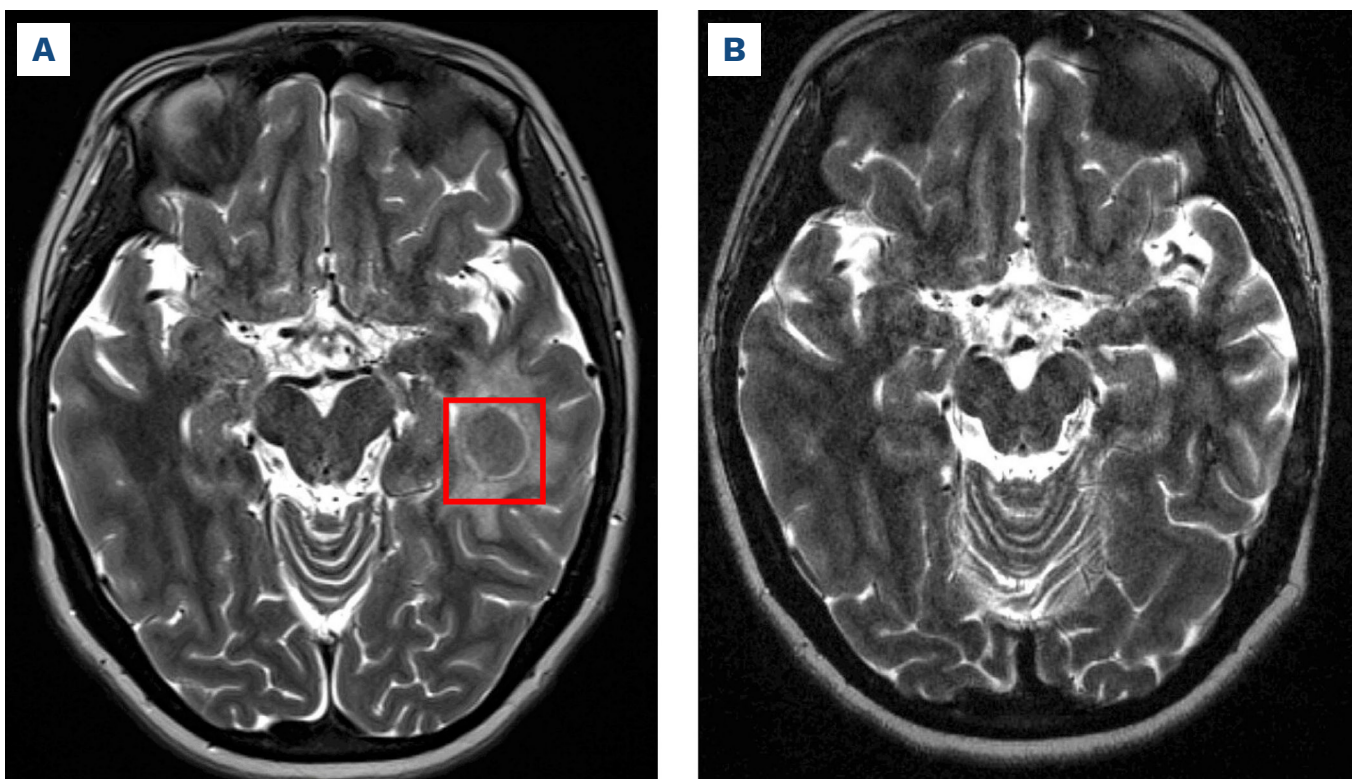

Figure 1. Magnetic resonance imaging of patient's intraparenchymal juvenile xanthogranuloma before and after initiation of larotrectinib. (A) Magnetic resonance imaging at time of diagnosis. (B) Follow-up magnetic resonance imaging 10 months after initiation of larotrectinib.

germline pathogenic nonsense variant in both tumor and blood specimens: *ETV6* c.1062C>A (p.Tyr354*) with variant allele frequencies of 0.49 and 0.40, respectively.

Given the targetable *NTRK1* fusion, the patient was initiated on larotrectinib for JXG therapy given data on rapid, durable responses and safety of larotrectinib in TRK fusion-positive CNS tumors.[6] She was initiated on standard adult dosing (100 mg twice daily), but due to a common side effect of generalized body aches was transitioned to three times daily dosing (75/50/75 mg) which was well tolerated. Within 2 months she had improvement in headaches and on follow-up MRI 10 months after drug initiation there was significant decrease in mass size with reduction of surrounding signal abnormality (Figure 1B).

The patient had no known family history of hematologic malignancies, thrombocytopenia, immune dysregulation, or other childhood cancers. However, cascade testing was performed for the identified pathogenic *ETV6* variant and revealed that this variant was inherited from her father and is also carried by her younger sister, neither of whom have been diagnosed with cancer or experienced bleeding symptoms.

Germline pathogenic variants in ETV6 have been described in multiple kindreds of patients with ALL.[7,8] The *ETV6* gene is located on chromosome 12p13.2 and encodes the essential hematopoietic transcriptional repressor erythroblast transformation specific variant 6 (ETV6) protein, which functions primarily as a transcriptional repressor and is essential for bone marrow hematopoiesis and thrombopoiesis.[9] The ETV6 protein has two highly conserved DNA-binding domains, PNT and ETS, and the majority of reported germline variants are missense mutations within these domains, although nonsense and frameshift variants are also observed. This patient's nonsense variant in exon 6 results in a premature stop codon predicted to cause an absent or truncated protein product, indicating pathogenicity. Many *ETV6* pathogenic variants are thought to exhibit dominant-negative activity by dimerizing with wild-type ETV6 and sequestering in the cytoplasm;[8] however, some experiments have demonstrated truncating and missense variants lose transcriptional repressor function, but have minimal dimerization effect.[10] To our knowledge, the specific alteration in our patient has not been previously reported.

ETV6-related predisposition was initially recognized in pedigrees as an autosomal-dominant condition of thrombocytopenia and leukemia preponderance.[7] Many families demonstrate complete penetrance of thrombocytopenia, although individuals with normal platelet counts have been reported, as seen in our patient. Among individuals with *ETV6* variants with associated thrombocytopenia, bleeding phenotype is variable; some patients experiencing bleeding even with normal platelet counts and others have no bleeding despite thrombocytopenia.[11]

Approximately 30% of individuals with *ETV6* germline pathogenic variants will develop hematologic malignancy, with B-ALL being the most common.[11] Other malignancies include myelodysplastic syndrome and acute myeloid leukemia. There are also case reports of individuals developing solid tumors under age 50.

Unselected analysis of pooled pediatric ALL cohorts demonstrated approximately 0.5-1% incidence of germline

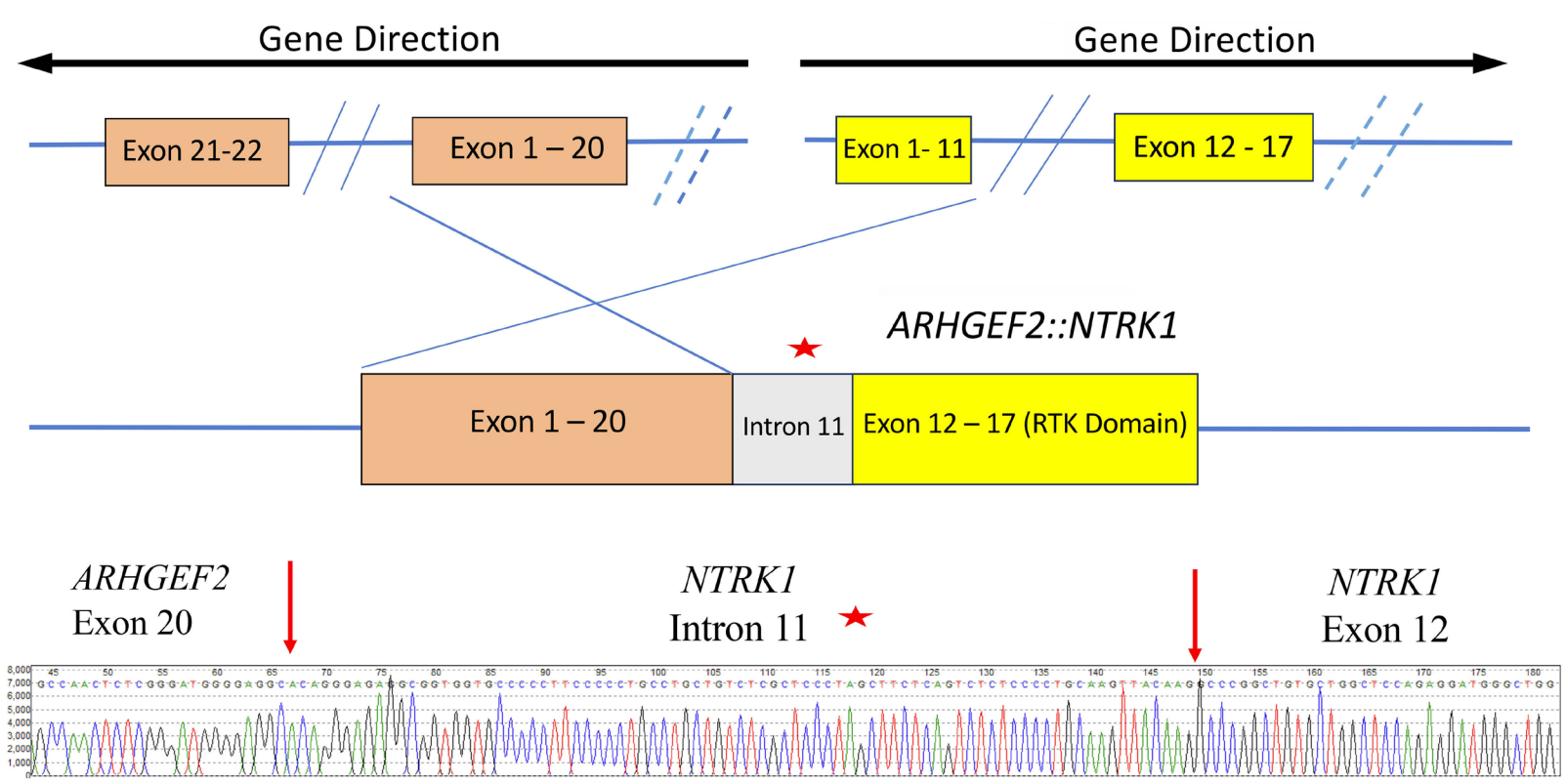

Figure 2. Schematic of *ARHGEF2::NTRK1* fusion. Top: local inversion or inverted fusion event resulted in the *ARHGEF2::NTRK1* fusion. Dashed lines represent possible alternative inverted fusion events. A portion of intron 11 sequence was included in the fusion product (red star). Bottom: Sanger sequencing confirmation results on cDNA showing the fusion gene sequence near the junction point. The red arrows indicate the junction point.

pathogenic *ETV6* variants.[10,12] Affected children are generally older at the time of diagnosis compared to children without germline *ETV6* predisposition, and demonstrate an overrepresentation of hyperdiploid karyotype which was observed in this patient. There is no observed association with end-induction MRD or relapse risk, although further research is warranted.

To our knowledge, this is the first case report of a patient with a pathogenic germline *ETV6* variant presenting with a xanthogranulomatous neoplasm. There is a single case report of a patient with disseminated JXG involving skin and bone marrow, concurrent with severe hemophagocytic lymphohistiocytosis during therapy for B-ALL; however, this patient had no identified germline predisposition.[13]

JXG are rare, benign tumors composed of non-Langerhans cell histiocytes. They often manifest as cutaneous lesions but can involve any organ system. Intracranial disease is only observed in about 7% of cases.[14] JXG have previously been described in patients with Noonan Syndrome with *PTPN11* pathogenic variants, and in Neurofibromatosis Type 1. Additionally, there are reports of histiocytic tumors co-occurring with B-ALL and T-ALL with shared B-cell and/or T-cell receptor gene rearrangements, suggesting a shared clonal cell of origin.[15] There was insufficient tissue available on our patient's JXG to perform gene rearrangement studies. It is possible the pathogenic *ETV6* variant described may contribute to JXG pathogenesis, and this risk may have been amplified by exposure to whole brain radiation 3.5 years prior to JXG presentation. However, the JXG may also be unrelated to her cancer predisposition syndrome.

This case adds to the growing literature describing leukemia predisposition in children with *ETV6* predisposition syndrome. We add the unique finding of intracranial non-Langerhans cell histiocytic neoplasm with *NTRK1* fusion in a patient with a prior history of B-ALL. Germline predisposition is thought to account for approximately 10-15% of childhood cancers. As paired tumor/normal testing with NGS becomes more prevalent, this percentage is likely to increase over time. Here we highlight a patient whose predisposition went undiagnosed with somatic testing alone and required paired diagnostics. Providers should have a particularly high index of suspicion and consider germline testing in children and adolescents presenting with multiple independent neoplasms.

Authors

Haley Newman,[1] Suzanne P. MacFarland,[1,2] Garrett M. Brodeur,[1,2] Timothy Olson,[1,2] Deepa Bhojwani,[3,4] Jamie Stokke,[3,4] Alexandra E. Kovach,[4,5] Mary Egan Clark,[1] Minjie Luo,[6] Marilyn Li,[2,6] Amish Shah[1,2] and Stephen P. Hunger[1,2]

[1]Division of Oncology, Department of Pediatrics, Children's Hospital of Philadelphia, Philadelphia, PA; [2]Center for Childhood Cancer Research, Children's Hospital of Philadelphia, Philadelphia, PA; [3]Cancer and Blood Disease Institute, Children's Hospital Los Angeles, Los Angeles, CA; [4]Keck School of Medicine of University of Southern California, Los Angeles, CA; [5]Department of Pathology and Laboratory Medicine, Children's Hospital Los Angeles, Los Angeles, CA and [6]Department of Pathology and Laboratory Medicine, Children's Hospital of Philadelphia, Philadelphia, PA, USA

Correspondence:
H. NEWMAN - newmanh@chop.edu

https://doi.org/10.3324/haematol.2023.284151

Received: August 23, 2023.
Accepted: November 22, 2023.
Early view: November 30, 2023.

©2024 Ferrata Storti Foundation
Published under a CC BY-NC license

Disclosures

No conflicts of interest to disclose.

Contributions

All authors contributed to the writing and editing of this case report.

Data-sharing statement

Original de-identified data is available upon request by contacting the corresponding author.

References

1. Angiolillo AL, Schore RJ, Kairalla JA, et al. Excellent outcomes with reduced frequency of vincristine and dexamethasone pulses in standard-risk B-lymphoblastic leukemia: results from Children's Oncology Group AALL0932. J Clin Oncol. 2021;39(13):1437-1447.
2. Brown PA, Ji L, Xu X, et al. A Randomized phase 3 trial of blinatumomab vs. chemotherapy as post-reinduction therapy in low risk (LR) first relapse of B-acute lymphoblastic leukemia (B-ALL) in children and adolescents/young adults (AYAs): a report from Children's Oncology Group study AALL1331. Blood. 2021;138(Suppl 1):363.
3. Hogan LE, Brown PA, Ji L, et al. Children's Oncology Group AALL1331: phase III trial of blinatumomab in children, adolescents, and young adults with low-risk B-cell ALL in first relapse. J Clin Oncol. 2023;41(25):4118-4129.
4. Kurozumi K, Nakano Y, Ishida J, et al. High-grade glioneuronal tumor with an ARHGEF2-NTRK1 fusion gene. Brain Tumor Pathol. 2019;36(3):121-128.

5. Surrey LF, MacFarland SP, Chang F, et al. Clinical utility of custom-designed NGS panel testing in pediatric tumors. Genome Med. 2019;11(1):32.
6. Doz F, van Tilburg CM, Geoerger B, et al. Efficacy and safety of larotrectinib in TRK fusion-positive primary central nervous system tumors. Neuro Oncol. 2022;24(6):997-1007.
7. Zhang MY, Churpek JE, Keel SB, et al. Germline ETV6 mutations in familial thrombocytopenia and hematologic malignancy. Nat Genet. 2015;47(2):180-185.
8. Noetzli L, Lo RW, Lee-Sherick AB, et al. Germline mutations in ETV6 are associated with thrombocytopenia, red cell macrocytosis and predisposition to lymphoblastic leukemia. Nat Genet. 2015;47(5):535-538.
9. Wang LC, Swat W, Fujiwara Y, et al. The TEL/ETV6 gene is required specifically for hematopoiesis in the bone marrow. Genes Dev. 1998;12(15):2392-2402.
10. Nishii R, Baskin-Doerfler R, Yang W, et al. Molecular basis of ETV6-mediated predisposition to childhood acute lymphoblastic leukemia. Blood. 2021;137(3):364-373.
11. Di Paola J, Porter CC. ETV6-related thrombocytopenia and leukemia predisposition. Blood. 2019;134(8):663-667.
12. Moriyama T, Metzger ML, Wu G, et al. Germline genetic variation in ETV6 and risk of childhood acute lymphoblastic leukaemia: a systematic genetic study. Lancet Oncol. 2015;16(16):1659-1666.
13. Pawińska-Wa Sikowska K, Cwiklinska M, Wyrobek E, et al. Disseminated juvenile Xanthogranuloma and hemophagocytic lymphohistiocytosis developed during treatment of acute lymphoblastic leukemia: case report. Front Oncol. 2020;10:921.
14. McClain KL, Bigenwald C, Collin M, et al. Histiocytic disorders. Nat Rev Dis Primers. 2021;7(1):73.
15. Feldman AL, Minniti C, Santi M, Downing JR, Raffeld M, Jaffe ES. Histiocytic sarcoma after acute lymphoblastic leukaemia: a common clonal origin. Lancet Oncol. 2004;5(4):248-250.