

Low-dose non-steroidal anti-inflammatory drugs: a promising approach for the treatment of symptomatic bone marrow failure in Ghosal hematodiaphyseal dysplasia

Authors

Jonathan Bordat,¹ Felipe Suarez,²⁻⁴ Valérie Cormier-Daire,^{2,5} Régis Peffault de Latour,^{1,2,6} Jean Soulier,^{2,6,7} Veronique Meignin,⁸ Mathilde Doyard,⁵ Lise Larcher,^{2,6,7} Stéphane Vanderbecken⁹ and Flore Sicre de Fontbrune^{1,6}

¹Department of Hematology and Bone Marrow Transplantation, Saint-Louis Hospital, Assistance Publique-Hôpitaux de Paris, Paris;

²Paris Cité University, Paris; ³Imagine Institute, INSERM UMR 1163, Laboratory of Molecular Mechanisms of Hematologic Disorders and Therapeutic Implications, Necker-Enfants Malades University Hospital, Assistance Publique-Hôpitaux de Paris, Paris; ⁴Adult Hematology, Necker-Enfants Malades University Hospital, Assistance Publique-Hôpitaux de Paris, Paris; ⁵French Reference Center for

Skeletal Dysplasia, INSERM UMR 1163, Imagine Institute, Necker Enfants Malades University Hospital, Assistance Publique-Hôpitaux de Paris, Paris; ⁶French Reference Center for Aplastic Anemia, Saint-Louis Hospital, Assistance Publique-Hôpitaux de Paris, Paris; ⁷Laboratory of Hematology, Saint-Louis Hospital, Assistance Publique-Hôpitaux de Paris, Paris; ⁸Department of Pathology, Saint-Louis Hospital, Assistance Publique-Hôpitaux de Paris, Paris and ⁹Hemophilia Treatment Center, University Hospital of Réunion, Réunion Island, France.

Correspondence:

J. BORDAT - jonathan.bordat@aphp.fr

F. S. DE FONTBRUNE - flore.sicre-de-fontbrune@aphp.fr

<https://doi.org/10.3324/haematol.2023.284098>

Table S1: List of genetically documented GHD cases reported and their clinical features (see excel file)

A: siblings, *B*: twins, *: but the X-ray could not be reviewed in the center, m: months, y: years, M: male, F: female, Hb: hemoglobin level, RBC: red blood cell transfusion, IS: positive inflammatory syndrome, CRP: C-reactive protein, ESR: erythrocyte sedimentation rate, NSAIDs: non-steroidal anti-inflammatory drugs, NA: non-applicable, AE: adverse event, NOS: not otherwise specified, Hom: homozygous, HetC: composite heterozygous mutation. #: The latest HGVS nomenclature was used. The transcript used is NM_001061.7, corresponding to the updated RefSeq one and retained by MANE select. It is linked to the protein NP_001052.3 where the 473 amino acid is a Glycin and the 474 is an Alanine. All the variants described in the literature were update for harmonize purposes.

Table S2: TBXAS1 mutation comparison in GHD subgroups (see excel file)

n: number of patients, Hom: homozygous, HetC: composite heterozygous mutation. The latest HGVS nomenclature was used. The transcript used is NM_001061.7, corresponding to the updated RefSeq one and retained by MANE select. It is linked to the protein NP_001052.3 where the 473 amino acid is a Glycin and the 474 is an Alanine. All the variants described in the literature were update for harmonize purposes.

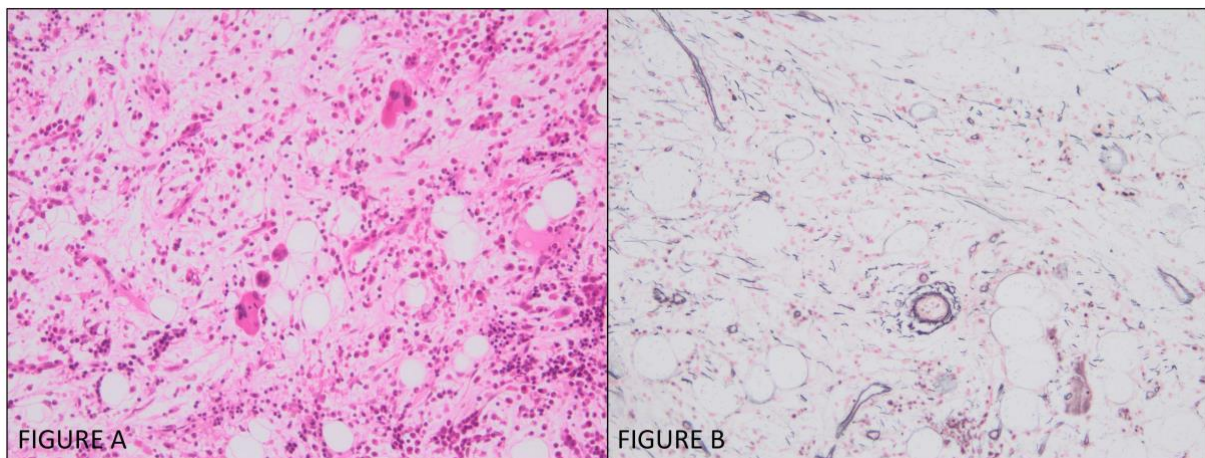


Figure S1: Bone marrow biopsy of Patient #2

Figure A: hypocellular bone marrow (20%) with dysmegakaryopoiesis and dyserythropoiesis associated with pronounced interstitial oedema (HES x 200).

Figure B: slight densification of the reticulin framework (WHO grade 1) (Reticulin staining x 200).

The fibrosis associated with interstitial edema, which is unusual, is characteristic of these biopsies.