

# Daratumumab and brentuximab vedotin combination therapy in T-cell acute lymphoblastic leukemia refractory to conventional chemotherapy and allogeneic stem cell transplant

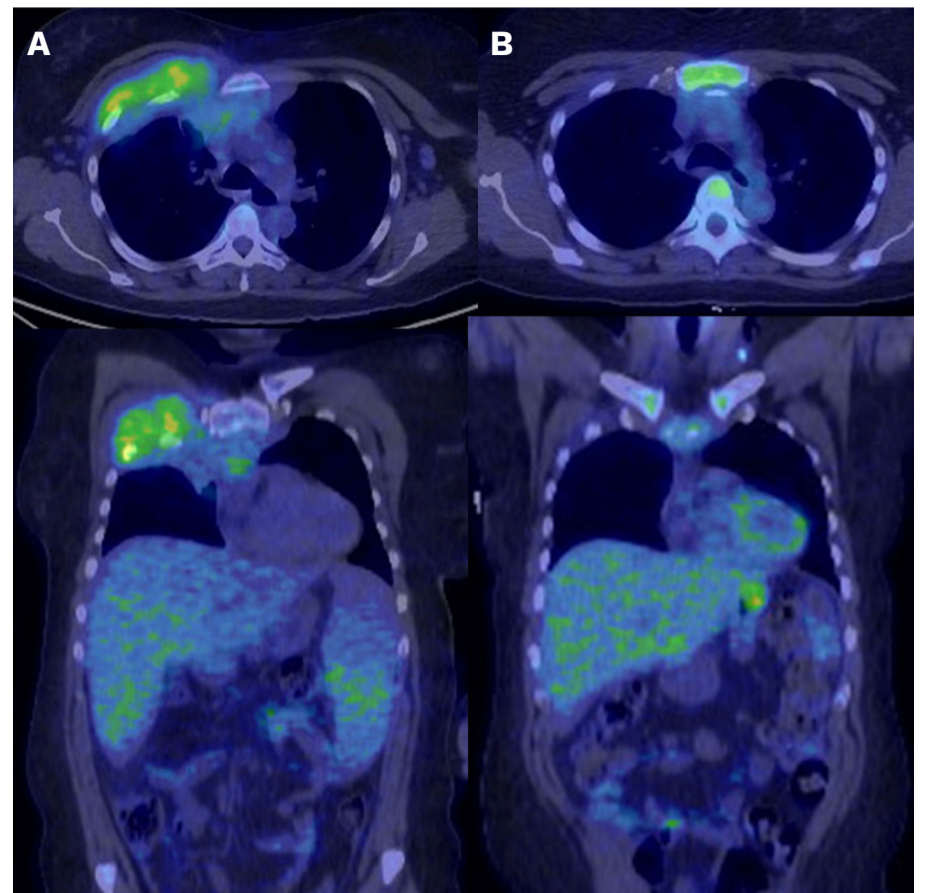
T-cell acute lymphoblastic leukemia/lymphoma (T-ALL) is an aggressive bone marrow neoplasm that accounts for 20% of acute lymphoblastic leukemias cases in adults.<sup>1</sup> Despite high rates of complete remission with first-line combination chemotherapy, with approximately 50% survival at 5 years, the outcomes for patients with relapsed disease are dismal.<sup>2</sup> There are limited salvage treatment options for patients with relapsed/refractory (R/R) disease.<sup>3,4</sup> This highlights the need for effective therapeutic options with novel mechanisms of action. Daratumumab is a CD38-targeted IgG1κ human monoclonal antibody that is used in the treatment of newly diagnosed and R/R multiple myeloma.<sup>5</sup> CD38 has been shown to be uniformly expressed on T-ALL blasts with persistent expression after treatment with chemotherapy.<sup>6</sup> Preclinical studies have demonstrated efficacy of daratumumab using patient-derived xenograft models of T-ALL.<sup>6,7</sup> There have been a few reports of daratumumab use in patients with R/R T-ALL and in patients who achieved a complete remission but were measurable residual disease (MRD)-positive. Brentuximab vedotin is an antibody drug conjugate composed of a CD30-targeting chimeric IgG antibody and the microtubule inhibitor monomethyl auristatin E. It is currently approved for use in the first line setting in combination with chemotherapy in classical Hodgkin lymphoma<sup>8</sup> and CD30-positive peripheral T-cell lymphoma,<sup>9</sup> and as monotherapy in the R/R setting.<sup>10</sup> One study demonstrated CD30 expression in 13 of 34 (38%) of cases of T-ALL by multicolor flow cytometry using a 20% cutoff for positivity; and upregulation of CD30 expression during the course of high-dose chemotherapy in some cases, suggesting that CD30 may be a potential therapeutic target for T-ALL.<sup>11</sup> However, there have not been prior clinical reports of brentuximab use in ALL. Here we report the use of daratumumab and brentuximab vedotin combination in a patient with heavily pretreated R/R T-ALL. A 45-year-old female was diagnosed with T-cell acute lymphoblastic leukemia (T-ALL) after presenting with an enlarging anterior chest wall mass (Figure 1A) and leukocytosis (white blood cell count:  $110.4 \times 10^9/L$ , 84% blasts) with bicytopenia. Bone marrow immunophenotyping showed blasts expressing CD3, CD45(dim), CD7, CD38, nTdT, cCD3, TCR-γ/δ(dim), CD5(dim), and CD58. Fluorescence *in situ* hybridization testing on the bone marrow showed a *TRB* rearrangement at 7q34 that was not fused with the common translocation partners (*MYB*, *TLX1*, *LMO1* or *LMO2*) and

trisomy of chromosome 9. Next-generation sequencing (FoundationOne heme) showed *JAK3* M511I, *MYCN* R357C, *NOTCH1* L1600P, and *PHF6* Y301fs\*1 mutations. She was started on treatment with hyperfractionated cyclophosphamide, vincristine, doxorubicin, and dexamethasone (Hyper-CVAD) regimen and achieved a complete response after 1 cycle with MRD estimated at 0.7% by flow cytometry at a sensitivity of 0.1%. Positron emission tomography/computed tomography (PET/CT) showed resolution of the hypermetabolic soft tissue mass and improvement in splenomegaly with normal <sup>18</sup>F-fluorodeoxyglucose (FDG) activity (Figure 1B). After completing five cycles, she remained MRD-positive at 0.05%. She subsequently received conditioning chemotherapy with cyclophosphamide and total body irradiation 1,200 cGy followed by allogeneic bone marrow transplantation with 11/12 HLA-matched (DP-permissive) unrelated donor. She experienced disease relapse, 3 months following transplant, and was enrolled on the clinical trial EA9152 of liposomal vincristine 2.25 mg/m<sup>2</sup> (days 1, 8, 15, and 22) and venetoclax (600 mg days 1-28). She experienced severe autonomic and sensory neuropathy after the first dose of liposomal vincristine leading to its discontinuation. She had persistent disease after completing one cycle of venetoclax, proceeded with salvage treatment with venetoclax combined with fludarabine, cytarabine, granulocyte colony-stimulating factor, and idarubicin (FLAG-IDA). Bone marrow biopsy at day 21 showed persistent T-ALL with >95% bone marrow blasts. A repeat FoundationOne heme revealed similar mutational profile with subclonal *JAK1* R724C and *STAT5B* N642H mutations. She was subsequently started on nelarabine (1,000 mg/m<sup>2</sup>) (days 1, 3 and 5, reduced dose due to neuropathy) and achieved a MRD-negative state after two cycles. This was followed by consolidation with a donor lymphocyte infusion (DLI) at a dose of  $1 \times 10^7$  CD3 cells/kg from the original donor. However, approximately 1 month following DLI, she experienced another relapse with 72% lymphoblasts and immunophenotype showed blasts expressing CD10, CD45(dim), CD5, CD7, CD38, nTdT, cCD3 but did not express CD3, TCR-γ/δ. Furthermore, immunohistochemistry also revealed blasts expressing diffuse CD38 (>80% of blasts) and strong CD30 staining (Figure 3A-D). There were new FDG-avid retroperitoneal and axillary lymph nodes and enlargement of the spleen with increased uptake on PET/CT (Figure 2A). Based on the CD38 and CD30 expression,

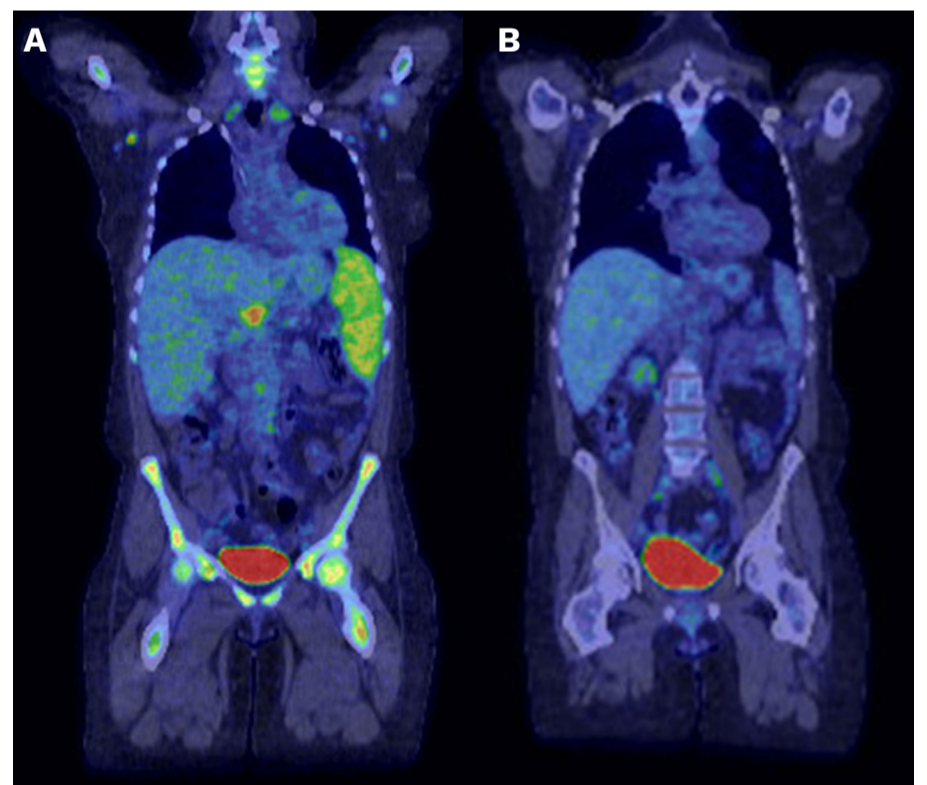
## CASE REPORT

she was started on treatment with weekly daratumumab 16 mg/kg (multiple myeloma schedule) and brentuximab vedotin 1.8 mg/kg every 21 days (Hodgkin lymphoma schedule). After one cycle, the bone marrow was markedly hypocellular with no morphologic features of involvement by T-ALL. MRD by flow cytometry was negative (a representative marrow after cycle 3 is shown in Figure 3E-H). PET/CT showed interval resolution of lymphadenopathy and decrease in the size of the spleen with normal uptake (Figure 2B). Due to persistent pancytopenia, cycle 2 was delayed by 1 month. The dose of brentuximab vedotin was reduced to 1.4 mg/kg starting with the third cycle due to grade 2 sensory peripheral neuropathy. The fourth cycle was complicated by grade 4 neutropenia with bacteremia, grade 3 diarrhea, and grade 3 sensory peripheral neuropathy. Treatment-emergent toxicities were likely a result of prior exposure to multiple chemotherapies, and presence of pre-existing peripheral neuropathy. Therefore, brentuximab vedotin was discontinued and single agent daratumumab was maintained. To date, she has completed eight weekly doses and six biweekly doses of daratumumab and remains in MRD-negative complete remission for a duration of 8 months.

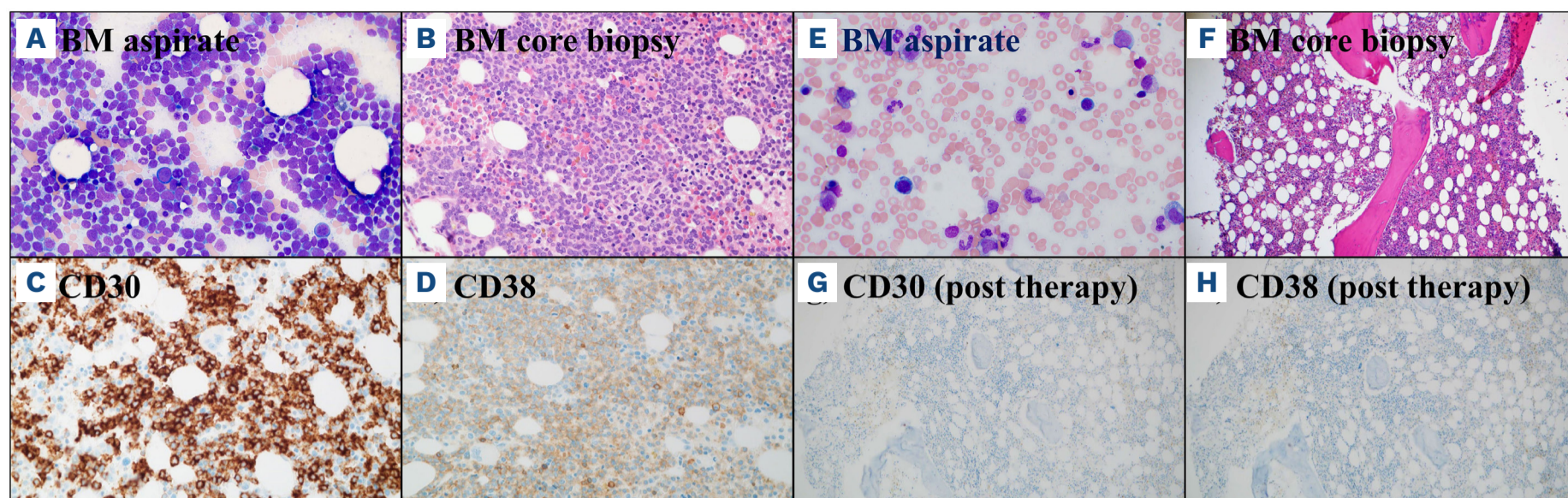
Here we demonstrate the efficacy of daratumumab in combination with brentuximab vedotin in a patient with R/R T-ALL, who had received four prior lines of conventional chemotherapy, including allogeneic stem cell transplant with DLI, with high disease burden who achieved deep and durable remission. At this time, patients with R/R T-ALL have limited therapeutic options and poor survival outcomes, especially when relapse occurs early after first-line induction chemotherapy.<sup>12</sup> Despite evidence for uniform CD38 expression in T-ALL blasts, clinical experience with daratumumab in T-ALL has been limited to case reports and small case series. Ofran *et al.* reported clinical efficacy of daratumumab monotherapy in three patients with heavily pretreated T-ALL who achieved complete remission but were MRD-positive after intensive chemotherapy prior to allogeneic stem cell transplantation. Daratumumab use was associated with eradication of residual disease after three to four doses, with disease-free survival of about 10 months.<sup>13</sup> In a more recent case series of daratumumab in 20 patients with ALL including 13 with T-ALL with R/R or MRD-positive disease after a median of three lines of therapy, overall response rate was 20% including MRD-negative complete remission in two patients. One patient with high disease burden achieved a response when daratumumab was used in combination with chemotherapy. The median time to response in the overall cohort was 4 weeks and median survival was 4 weeks. Treatment was safe with no unexpected toxicities.<sup>14</sup> Furthermore, the efficacy of daratumumab in CD38-positive B-ALL has also been demonstrated in a multiple relapsed pediatric patient with Philadelphia chromosome-positive B-ALL, prior treatments included DLI, two allogeneic stem cell transplants and anti-CD19



**Figure 1. Metabolic response by positron emission tomography scan showing changes over the course of therapy.** (A) Patient at diagnosis of T-cell acute lymphoblastic leukemia showing hypermetabolic anterior right chest wall mass and splenomegaly; and (B) after the first cycle of chemotherapy showing resolution of chest wall mass and improvement in splenomegaly.



**Figure 2. Metabolic response by positron emission tomography scan showing changes over the course of therapy after relapse.** (A) Prior to starting treatment with daratumumab and brentuximab vedotin showing hypermetabolic retroperitoneal and axillary lymph nodes and splenomegaly with increased <sup>18</sup>F-fluorodeoxyglucose avidity; and (B) after 1 cycle of daratumumab and brentuximab vedotin showing interval resolution of lymphadenopathy and decrease in the size of the spleen with normal uptake.



**Figure 3. Bone marrow aspirate and core biopsy findings showing changes pre- and post-treatment with daratumumab and brentuximab vedotin.** Sheets of blasts prior to daratumumab and brentuximab vedotin on (A) diagnostic bone marrow aspirate (Wright Giemsa, original magnification x400); (B) core biopsy (hematoxylin and eosin, original magnification x400); (C) strong CD30 positivity (immunohistochemistry, antibodies to CD30, original magnification x400) and (D) diffuse CD38 positivity on the blasts (immunohistochemistry, antibodies to CD38, original magnification x400); (E) post treatment bone marrow aspirate (Wright Giemsa, original magnification x600); (F) core biopsy in remission (hematoxylin and eosin, original magnification x100); (G) negative CD30 stain (immunohistochemistry, antibodies to CD30, original magnification x400) and (H) negative CD38 stain (immunohistochemistry, antibodies to CD38, original magnification x400).

chimeric antigen receptor T cells, who rapidly achieved morphological remission following initiation of daratumumab, together with weekly vincristine and ponatinib.<sup>15</sup> Whether the deep and durable remission achieved in our patient was due to daratumumab, brentuximab or combination of the two agents is unclear, although it is to be noted that our patient had previously received liposomal vincristine, which has a similar mechanism to brentuximab. To our knowledge, there are no reports for the use of brentuximab vedotin in T-ALL, but the expression of CD30 in a subset of patients with T-ALL provides a rationale for its evaluation in this setting. About one third of patients with T-ALL may express CD30 with increased expression level following chemotherapy.<sup>11</sup> Brentuximab may lead to worsening of pre-existing peripheral neuropathy and prolonged cytopenias in heavily pretreated patients which may limit the duration of treatment or necessitate dose reductions as in our patient. Daratumumab is well tolerated and can be continued on a maintenance schedule (every 28 days). Large studies are needed to confirm the efficacy of this combination in the R/R setting and define the optimal doses, schedule, and treatment duration. Daratumumab in combination with chemotherapy is under investigation in relapsed/refractory pediatric and young adults with ALL (*clinicaltrials.gov. Identifier: NCT03384654*). Preliminary findings from 24 patients enrolled on the phase II DELPHINUS study with daratumumab and vincristine, prednisone, PEG-asparaginase, and doxorubicin (VPLD) reinduction backbone, showed complete remission in ten patients (41.7%) at the end of cycle 1.<sup>16</sup> We also await with interest the results of EA9213, a phase II study of daratumumab-hyaluronidase for chemotherapy-relapsed/refractory minimal residual disease

in T-cell ALL (*clinicaltrials.gov. Identifier: NCT05289687*). To our knowledge this is the first report to demonstrate daratumumab with brentuximab vedotin combination as an effective and safe therapy in relapsed/refractory T-ALL. Additional studies are required to elucidate the possible synergistic mechanism of daratumumab and brentuximab.

## Authors

Kebede H. Begna,<sup>1</sup> Nadine H. Abdallah,<sup>1</sup> Michelle Janania-Martinez,<sup>2</sup> Abhishek A. Mangaonkar,<sup>1</sup> Aruna Rangan,<sup>3</sup> Jennifer L. Herrick,<sup>3</sup> and Naseema Gangat<sup>1</sup>

<sup>1</sup>Department of Internal Medicine, Division of Hematology, Mayo Clinic, Rochester, MN; <sup>2</sup>Division of Hematology/Oncology, Sanford Cancer Center, Sioux Falls, SD and <sup>3</sup>Department of Laboratory Medicine and Pathology, Division of Hematopathology, Mayo Clinic, Rochester, MN USA

Correspondence:

K.H. BEGNA - begna.kebede@mayo.edu

<https://doi.org/10.3324/haematol.2023.283740>

Received: June 12, 2023.

Accepted: September 7, 2023.

Early view: September 14, 2023.

©2024 Ferrata Storti Foundation

Published under a CC BY-NC license 

### Disclosures

No conflicts of interest to disclose.

### Contributions

KB and NA wrote the paper. KB, NA, MJ, AM, and NG participated in patient care. AR and JH performed review of bone marrow biopsies.

All authors reviewed and approved the final draft of the paper.

### Data-sharing statement

Data will be shared upon reasonable request addressed to the corresponding author.

## References

---

1. Marks DI, Paietta EM, Moorman AV, et al. T-cell acute lymphoblastic leukemia in adults: clinical features, immunophenotype, cytogenetics, and outcome from the large randomized prospective trial (UKALL XII/ECOG 2993). *Blood*. 2009;114(25):5136.
2. Fielding AK, Richards SM, Chopra R, et al. Outcome of 609 adults after relapse of acute lymphoblastic leukemia (ALL); an MRC UKALL12/ECOG 2993 study. *Blood*. 2007;109(3):944-950.
3. McMahan CM, Luger SM. Relapsed T cell ALL: current approaches and new directions. *Curr Hematol Malig Rep*. 2019;14(2):83-93.
4. Samra B, Alotaibi AS, Short NJ, et al. Outcome of adults with relapsed/refractory T-cell acute lymphoblastic leukemia or lymphoblastic lymphoma. *Am J Hematol*. 2020;95(9):E245-E247.
5. Moreau P, Kumar SK, San Miguel J, et al. Treatment of relapsed and refractory multiple myeloma: recommendations from the International Myeloma Working Group. *Lancet Oncol*. 2021;22(3):e105-e118.
6. Bride KL, Vincent TL, Im SY, et al. Preclinical efficacy of daratumumab in T-cell acute lymphoblastic leukemia. *Blood*. 2018;131(9):995-999.
7. Naik J, Themeli M, de Jong-Korlaar R, et al. CD38 as a therapeutic target for adult acute myeloid leukemia and T-cell acute lymphoblastic leukemia. *Haematologica*. 2019;104(3):e100-e103.
8. Ansell SM, Radford J, Connors JM, et al. Overall survival with brentuximab vedotin in stage III or IV Hodgkin's lymphoma. *N Engl J Med*. 2022;387(4):310-320.
9. Horwitz S, O'Connor OA, Pro B, et al. Brentuximab vedotin with chemotherapy for CD30-positive peripheral T-cell lymphoma (ECHELON-2): a global, double-blind, randomised, phase 3 trial. *Lancet*. 2019;393(10168):229-240.
10. Chen R, Gopal AK, Smith SE, et al. Five-year survival and durability results of brentuximab vedotin in patients with relapsed or refractory Hodgkin lymphoma. *Blood*. 2016;128(12):1562-1566.
11. Zheng W, Medeiros LJ, Young KH, et al. CD30 expression in acute lymphoblastic leukemia as assessed by flow cytometry analysis. *Leuk Lymphoma*. 2014;55(3):624-627.
12. Ribera JM, Morgades M, Genesca E, et al. Outcomes and prognostic factors of adults with refractory or relapsed T-cell acute lymphoblastic leukemia included in measurable residual disease-oriented trials. *Hematol Oncol*. 2021;39(4):529-538.
13. Ofran Y, Ringelstein-Harlev S, Slouzkey I, et al. Daratumumab for eradication of minimal residual disease in high-risk advanced relapse of T-cell/CD19/CD22-negative acute lymphoblastic leukemia. *Leukemia*. 2020;34(1):293-295.
14. Cerrano M, Bonifacio M, Olivi M, et al. Daratumumab with or without chemotherapy in relapsed and refractory acute lymphoblastic leukemia. A retrospective observational Campus ALL study. *Haematologica*. 2022;107(4):996-999.
15. Ganzel C, Kharit M, Duksin C, et al. Daratumumab for relapsed/refractory Philadelphia-positive acute lymphoblastic leukemia. *Haematologica*. 2018;103(10):e489-e490.
16. Hogan LE, Bhatla T, Teachey DT, et al. Efficacy and safety of daratumumab (DARA) in pediatric and young adult patients (pts) with relapsed/refractory T-cell acute lymphoblastic leukemia (ALL) or lymphoblastic lymphoma (LL): results from the phase 2 DELPHINUS study. *J Clin Oncol*. 2022;40(Suppl 16):S1001.