

Dabrafenib and trametinib in Langerhans cell histiocytosis and other histiocytic disorders

Eily Cournoyer,^{1*} Justin Ferrell,^{1*} Susan Sharp,² Anish Ray,³ Michael Jordan,⁴ Christopher Dandoy,⁴ Michael Grimley,⁴ Somak Roy,⁵ Robert Lorsbach,⁵ Arnold C. Merrow,² Adam Nelson,⁴ Allison Bartlett,⁴ Jennifer Picarsic⁵ and Ashish Kumar⁴

¹Cincinnati Children's Hospital Medical Center Pediatric Residency Training Program, Cincinnati, OH; ²University of Cincinnati College of Medicine, Division of Radiology, Cincinnati Children's Hospital Medical Center, Cincinnati, OH; ³Division of Hematology and Oncology, Cook Children's Hospital, Fort Worth, TX; ⁴University of Cincinnati College of Medicine, Division of Bone Marrow Transplant and Immune Deficiency, Cincinnati Children's Hospital Medical Center, Cincinnati, OH and ⁵University of Cincinnati College of Medicine, Division of Pathology, Cincinnati Children's Hospital Medical Center, Cincinnati, OH, USA

**EC and JF contributed equally as first authors.*

Correspondence: A. Kumar

Ashish.kumar@cchmc.org

Received: April 6, 2023.

Accepted: September 4, 2023.

Early view: September 21, 2023.

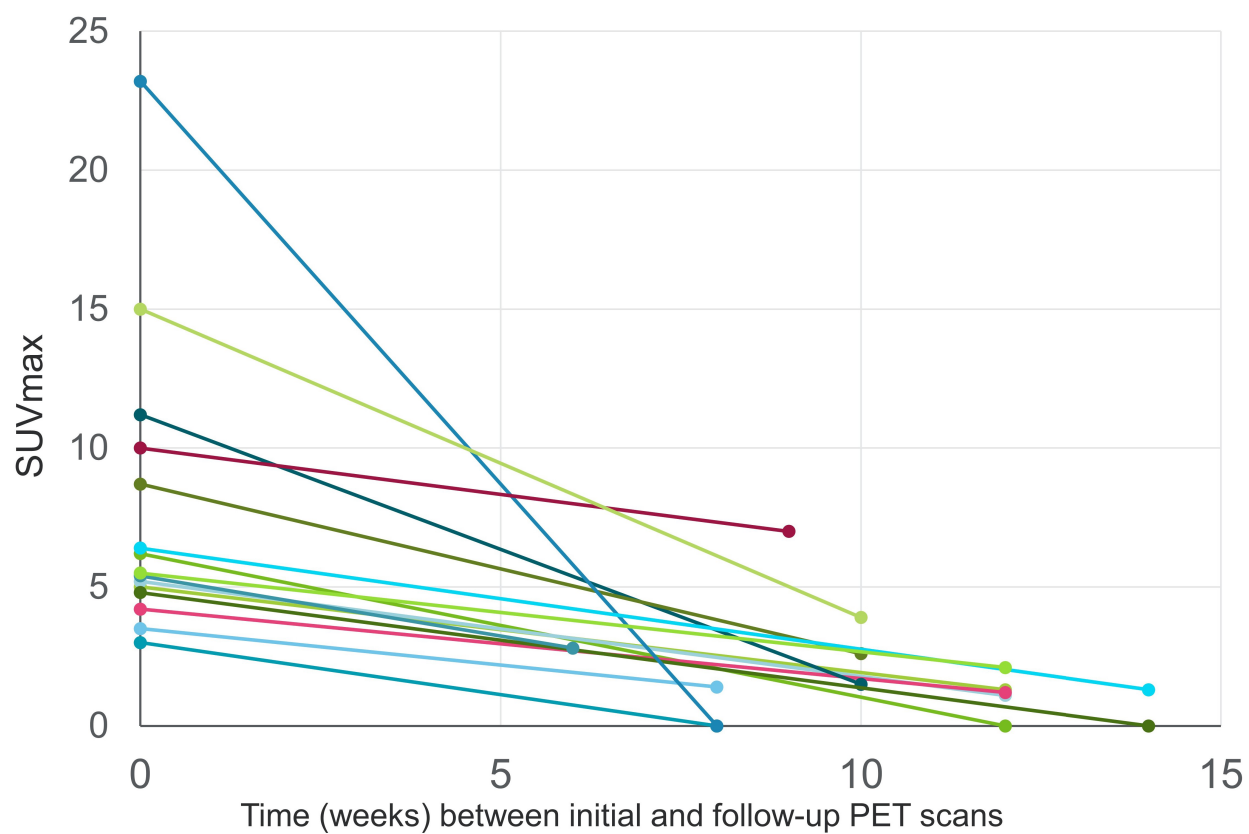
<https://doi.org/10.3324/haematol.2023.283295>

©2024 Ferrata Storti Foundation

Published under a CC BY-NC license



Supplemental Figure 1



Supplemental Figure: Graph depicting changes in PET-CT SUVmax values (vertical axis) in patients at the start of treatment and at their first follow-up scans (time interval in weeks on horizontal axis). Each line represents change in SUVmax for a single patient.