

### Successful pregnancies after transplantation of ovarian tissue retrieved and cryopreserved at time of childhood acute lymphoblastic leukemia – a case report

Fertility preservation (FP) has gained recognition as an integral part of cancer-treatment in young patients and the interest in developing methods that can also be offered to children is increasing.<sup>1</sup> Ovarian tissue cryopreservation (OTC) is the only option for FP for prepubertal girls, and also a frequently offered method to young female adolescents.<sup>2</sup> Retrieval of the tissue is usually performed through laparoscopy and can be planned without significant delay and with low postoperative risks, as reported in large series.<sup>2</sup>

The outcome for pediatric patients suffering from acute leukemia has improved dramatically over the last decades and OTC aimed at FP is becoming an established routine procedure in many cancer centers. However, fundamental questions remain, especially with regard to the potential of reseeding of malignant cells, as well as the future functionality of OTC if the patients have already received several chemotherapy rounds. At present, only a few cases of ovarian tissue transplantation (OTT) in survivors of adult acute leukemia have been reported,<sup>3-5</sup> but no cases of OTC at time of childhood leukemia have been reported.

The case hereby described refers to a female pediatric patient, 14 years of age, diagnosed in 2001 with Philadelphia chromosome positive, high risk, acute lymphoblastic leukemia (Ph<sup>+</sup> ALL). Induction treatment according to the protocol of the Nordic Society Pediatric Hematology and Oncology, NOPHO ALL 2000 high risk protocol (Vincristine, Doxorubicine, Cytarabine and Prednisolone plus Methotrexate), was initiated immediately upon diagnosis. After consolidation the patient achieved complete remission and she was planned for allogeneic stem cell transplantation (HSCT), as stipulated by the protocol. Bone marrow flow-cytometry analysis showed cells with the leukemia-associated immunophenotype below 0,1% at that time point. Due to the high gonadotoxicity of the conditioning regime (3 Gy x 4 total body irradiation combined with high dose cyclophosphamide) the patient was referred for FP counselling (Figure 1). OTC was considered appropriate due to the confirmed remission status. An ovarian biopsy of half the right ovary was obtained by laparoscopy and cryopreserved in pieces of about 2 mm x 4 mm size, using a propanediol-based slow-freezing protocol.<sup>6</sup> Following HSCT-conditioning the patient developed permanent ovarian failure (Figure 1).

In 2016, 15 years after remission and OTC, the patient consulted the fertility clinic expressing a wish to retransplant her ovarian tissue. The serum gonadotropin levels after interruption of hormonal substitution were in the postmenopausal range (Figure 1). The ovaries were small and appeared inactive on ultrasound scans.

Although the ovarian tissue had been harvested after several courses of chemotherapy and during confirmed remission, an additional molecular analysis to further evaluate the safety of the ovarian tissue to be transplanted was discussed with the patient in 2017. No molecular investigations had been performed at the time of leukemia-diagnosis; however, frozen blood cells taken at diagnosis in 2001 were available at the Karolinska Institute's biobank and were used to establish that the patient's leukemic cells harbored the BCR-ABL minor fusion transcript. Subsequently, the presence of the BCR-

ABL transcript was investigated in the patients' cryopreserved ovarian tissue. Eight ovarian tissue pieces each approximately 1-2 mm x 4 mm, comprising approximately 15% of the cryopreserved tissue (the rest was eventually transplanted), were randomly selected and processed in parallel using the EZ1 RNATM tissue mini kit (Qiagen, Sweden) in 2017. In order to maximize sensitivity, we used all the RNA extracted from the ovarian tissue and reverse transcribed it using the Superscript<sup>TM</sup> VILOTM kit (ThermoFischer, Sweden). The presence of the BCR-ABL transcript was investigated in a total of 80 independent polymerase chain reaction (PCR) reactions.<sup>7</sup> GUS transcript was used to measure RNA integrity and quantity. No BCR-ABL transcript was detected in any of the real-time PCR reactions and we could estimate a detection level corresponding to 1/105 malignant to non-malignant cells. As our investigations showed a reassuringly low likelihood for leukemic cell contamination, this supported the decision to proceed to transplantation of the ovarian tissue with reproductive purposes.

Twenty-seven ovarian tissue pieces were thawed and transplanted in November 2017 through a modified laparoscopic technique that allowed the ovary to be exteriorized facilitating the insertion of the ovarian tissue transplants in ovarian subcortical pockets (Figure 2).

The patient suspended hormonal substitution therapy the day before surgery but gonadotropins still indicated postmenopausal levels 1 month post surgery. Ovarian engraftment was followed-up through monitoring of clinical signs of estrogen secretion, climacteric symptoms, and serum levels of gonadotropins, estrogen and anti-Mullerian hormone (AMH). The gonadotropins returned to premenopausal levels 85 days after transplantation, increasing serum estradiol levels were demonstrated, and climacteric symptoms improved (Figure 1). Antral follicles were visualized on ultrasound and controlled ovarian stimulation with gonadotropins (COS) using an antagonist protocol aiming at *in vitro* fertilization (IVF) was initiated. Four attempts of IVF failed due to poor response, with only one oocyte retrieved that was not fertilized. A second transplantation was therefore performed in November 2018 using the remaining ovarian tissue that included 19 thawed pieces; of those seven pieces had been previously thawed in 2017 but not used for the molecular analysis and re-cryopreserved. Spontaneous menstruation occurred 86 days following transplantation. On ultrasound scans the size of the uterus and the ovaries was significantly enlarged from baseline estimations, but the serum AMH levels were low, 0.15 µg/L, indicative of a much reduced ovarian reserve. A new attempt at IVF was initiated when gonadotropins returned to premenopausal levels and this treatment resulted in one oocyte retrieved and fertilized by standard IVF technique. Embryo morphological development was normal and transferred was at 4-cell stage. Pregnancy was established and the patient delivered a healthy baby boy at 35+5 gestational weeks in November 2019. No complications associated with prematurity occurred. Breast feeding was possible, but successful only for 3 months and thereafter suspended. Menstrual cycles resumed 3 months after delivery and continued for 9 months until the woman achieved a natural conception confirmed incidentally in November 2020 at the time of consultation to our fertility center. On ultrasonography, the pregnancy was confirmed as ongoing at gestational week 8. At the time of this report the pregnancy is progressing into week 35<sup>th</sup>.

Although OTC have been reported in women and girls with leukemia in large series of fertility preservation,<sup>2,8</sup>

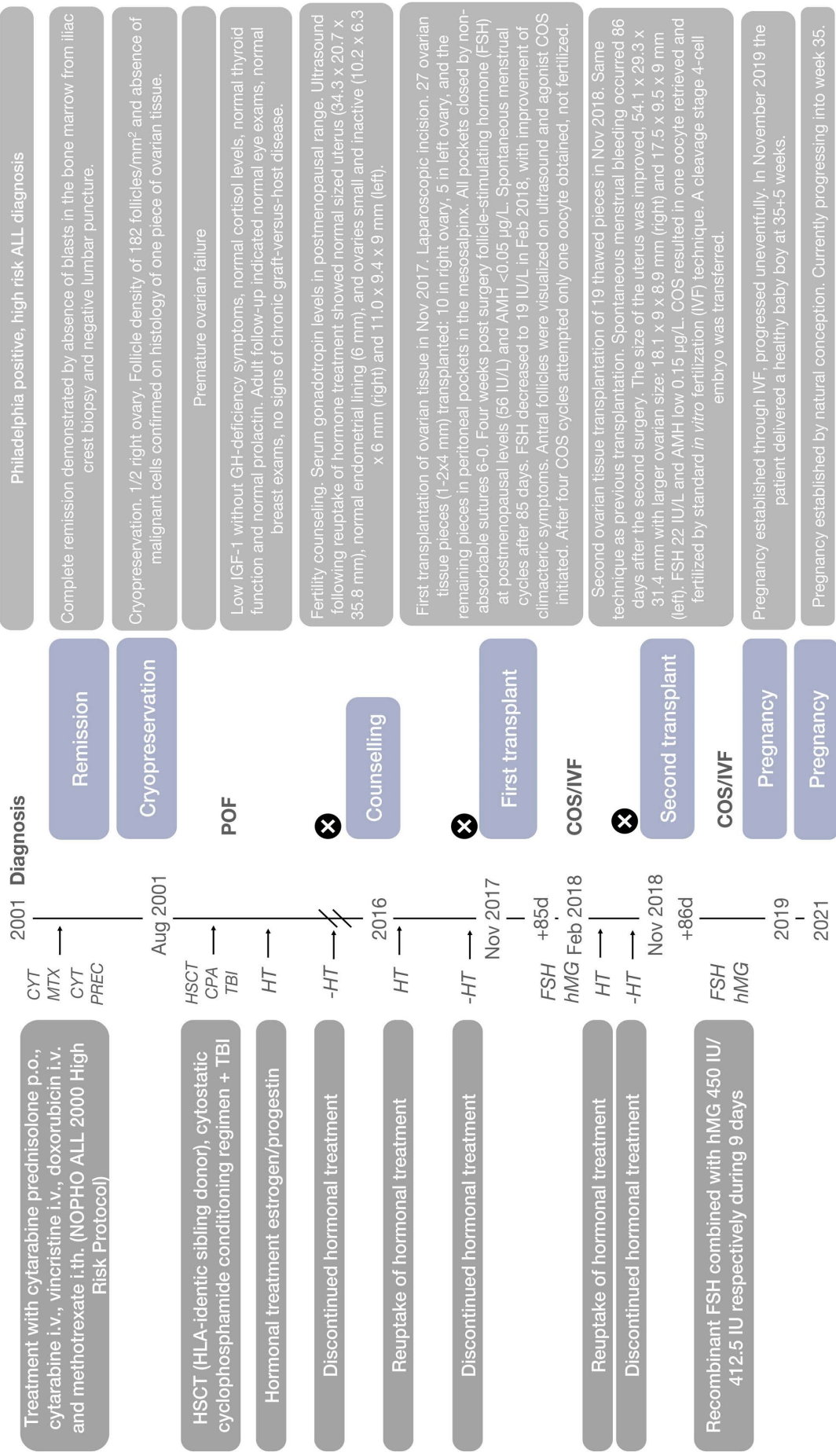


Figure 1. Timeline from diagnosis of acute lymphoblastic leukemia to first pregnancy. p.o.: per os; i.v.: intravenously; i.th.: intrathecal injection; TBI: total body irradiation; FSH: follicle stimulating hormone; hMG: human menopausal gonadotropin; COS: controlled ovarian stimulation using gonadotropins for treatment involving assisted reproduction; IVF: *in vitro* fertilization; IGF-1: insulin-like growth factor 1; GH: growth hormone; POF: premature ovarian failure; AMH: anti-Müllerian hormone. Laboratory reference for serum-FSH: postmenopausal >26 IU/L. Serum AMH: 1 µg/L = 7.14 pmol/L.

Table 1. Outcomes of ovarian tissue transplantation in survivors of adult acute leukemia.

Diagnosis	Age OTC	Age OTT	Chemotherapy prior to OTC	MRD bone marrow at OTC	Treatment after OTC	Evaluation OTC MRD	Outcome	Reference
AML	26	37	2 x ADE	CR	Allogeneic HSCT (TBI*)	Molecular detection of leukemia-specific marker	ROF	8
AML	19	27	1 x MAC, 1 x HDAC+ASPA	CR	Allogeneic HSCT	Molecular detection of leukemia-specific v marker	ROF	8
AML	19	32	Ara-C+Daunorubicin	CR	Allogeneic HSCT	Molecular detection of fusion transcript + xenograft	1 LB	3
ALL	24	39	no information	CR	no information	no information	1 LB	4
AML	25	28	no information	CR	no information	no information	ROF	4
ALL	19	26	VD+ASPA+MTX	CR	Allogeneic HSCT FluCy-TBI	Molecular detection of fusion transcript + IHC	1 LB	5

OTC: ovarian tissue cryopreservation; OTT: ovarian tissue transplantation; MRD: minimal residual disease; AML: acute myeloid leukemia; ALL: acute lymphoblastic leukemia; ROF: re-establishment of ovarian function; ADE: Ara-C (Cytarabine), Daunorubicin, Etoposide; MAC: Myeloablative conditioning Aracytine Mitoxantrone; HDAC+ASPA: Aracytine, L-Asparaginase; VD+ASPA+MTX: Vincristine, Daunorubicin, L-Asparaginase, Methotrexate; CR: complete remission; HSCT: hematopoietic stem cell transplantation, TBI: total body irradiation; FluCy: Fludarabine cyclophosphamide; IHC: immunohistochemistry; LB: live birth.

only isolated cases of OTT in survivors of hematological malignancies have been described to date.<sup>4,8,9</sup> The majority of the reported OTT for hematological malignancies concern lymphomas, while only a handful cases of OTT in survivors of adult acute leukemia have been reported (Table 1).<sup>3-5,8</sup>

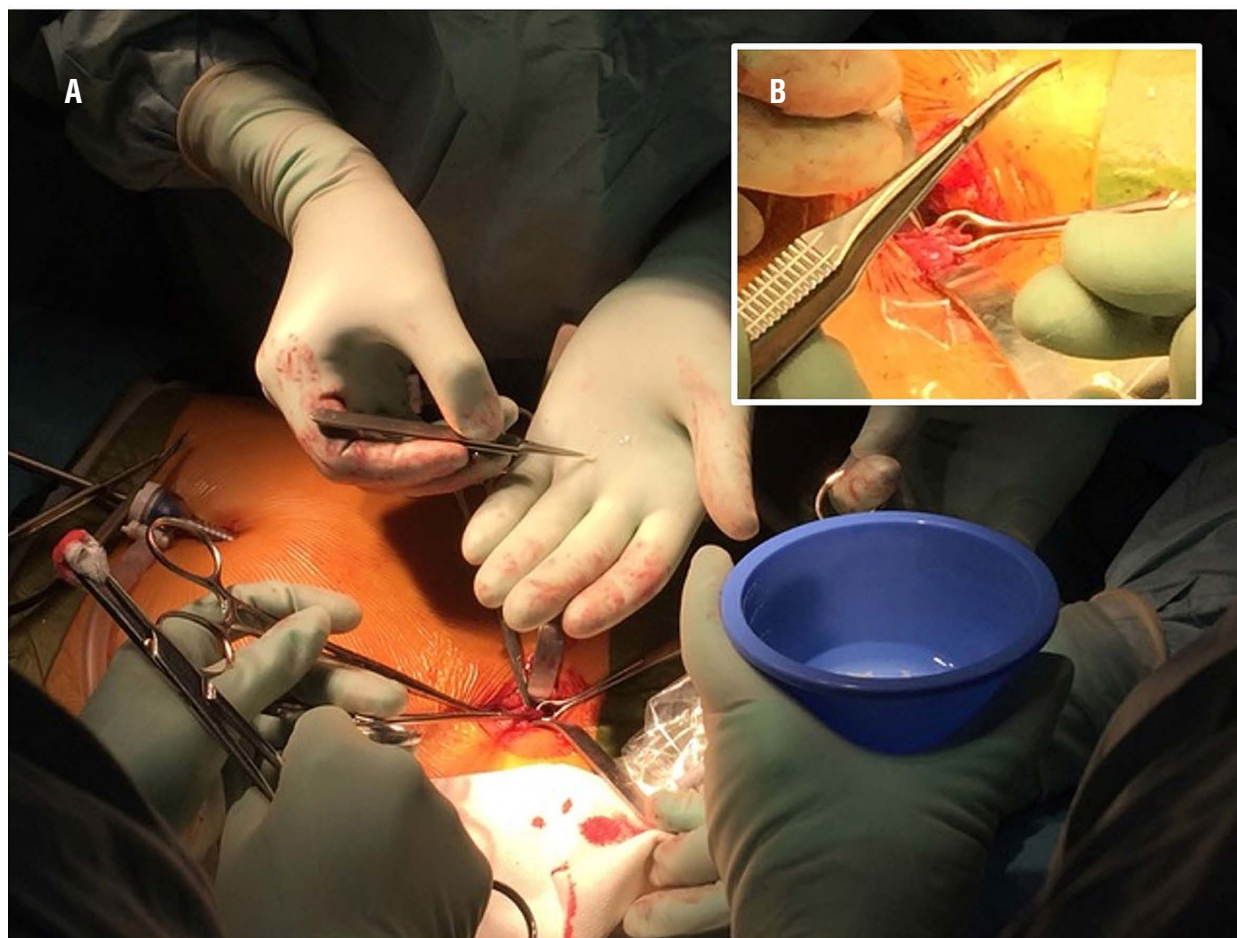
Residual disease is often detected when the tissue is investigated with sensitive molecular methods targeting leukemia-specific genetic markers and OTC has been performed before the patient has achieved molecular remission.<sup>10-12</sup> Also, xenografts of cryopreserved OT from women diagnosed with chronic myeloid leukemia (CML) and ALL into severe combined immunodeficient (SCID) mice could transfer leukemic cells, demonstrating that viable malignant cells may be present in the grafts. However, only the xenografts with detectable leukemic markers, as determined by sensitive molecular methods, showed leukemic cell transfer together with the xenografted OT.<sup>10</sup> Importantly, studies have shown that OTC retrieved after the patient has achieved complete remission in the bone marrow in most cases also is negative for leukemia markers in the cryopreserved ovarian tissue<sup>8,13,14</sup> and OTC that scored negative for molecular leukemic markers did not transfer leukemia to the recipient mice.<sup>13</sup> In a recent study Chevillon and co-workers investigated the presence of minimal residual disease (MRD) in OTC harvested from acute leukemia patients that achieved complete remission and showed significant concordance between bone marrow and OT; however, four of nine discordant patients had undetectable MRD in the bone marrow while positive in the OT.<sup>15</sup>

Taken together, these studies support that OTC harvested once the patient has achieved remission in the bone marrow has a very low likelihood to transmit leukemia provided the OTC is negative for the molecular

marker present in the blast cells.

The present case shares several important features with the published reports of live births following OTT in patients cured from acute leukemia that provide details on treatment preceding the OTC (Table 1). In all cases the OTC was performed after induction and consolidation therapy when the patient had achieved complete remission in the bone marrow.<sup>3,5</sup> One important common fact regarding previously reported OTT patients and our patient is that they had all received allogeneic HSCT as part of the leukemia treatment and graft-versus-leukemia effect may contribute to eliminate small amounts of leukemic cells potentially introduced with the OTT.<sup>3,5</sup> Another important aspect in common is the availability of a fusion transcript unique to the malignant blasts that could be investigated in the OTT with very sensitive methods.<sup>3,5</sup>

To the best of our knowledge three live births have been reported to date after ovarian tissue transplantation in patients with adult acute leukemia.<sup>3-5</sup> The present case is the third reported of a live birth after OTT in a patient with acute leukemia and the first one in pediatric ALL, as well as the first case where spontaneous pregnancy has additionally occurred after ovarian tissue transplantation in a survivor from pediatric ALL that recovered fertility following the transplantation procedures. The patient has been disease-free for 20 years after the diagnosis of ALL, and at the time of this report 43 and 31 months have elapsed from the first and second transplantations, respectively. Our results suggest that OT harvested in remission after several courses of chemotherapy and cryopreserved may be a reproductive option for young women and girls treated for ALL. However, one should be cautious and carefully inform patients about the limitations of the available methods to exclude persistence of



**Figure 2. Transplantation of ovarian tissue.** (A) The first transplantation was conducted in November 2017. In total 27 ovarian tissue pieces of size 1.2 mm x 4 mm were thawed and transplanted. The majority of ovarian pieces were implanted in subcortical pockets using microsurgical instruments (ten in the right ovary, and five in the left ovary) and 12 pieces in peritoneal pockets in the mesosalpinx. All pockets were closed by non-absorbable sutures 6-0. The surgery and post-operative period were uneventful. The second transplantation included 19 thawed pieces. Same technique as previous transplant. (B) A modified laparoscopic technique was used, to allow the ovary being grasped with Babcock forceps and exteriorized through the anterior abdominal wall using a 3 cm incision to facilitate inserting the tissue pieces.

leukemic cells in the ovarian tissue. We believe important aspects to sustain a future plausible transplantation of the ovarian tissue include the performance of OTC at a confirmed remission stage, as well as the availability of using a relatively large portion of the OTC for safety assessments. Only if these assessments point towards a low likelihood of risks can a decision to transplant ovarian tissue back to a patient cured from cancer been made when she aims at regaining fertility.

Kenny A. Rodriguez-Wallberg<sup>1,2</sup> Milan Milenkovic,<sup>1,2</sup> Kiriaki Papaikononou,<sup>3</sup> Victoria Keros,<sup>2</sup> Britt Gustafsson,<sup>4</sup> Fotios Sergouniotis,<sup>1,2</sup> Ida Wikander,<sup>2</sup> Ronak Perot,<sup>5</sup> Birgit Borgström,<sup>1</sup> Per Ljungman<sup>6</sup> and Gisela Barbany<sup>7</sup>

<sup>1</sup>Department of Oncology-Pathology, Karolinska Institutet; <sup>2</sup>Department of Reproductive Medicine, Division of Gynecology and Reproduction, Karolinska University Hospital; <sup>3</sup>Department of Women's and Children's Health, Division of Obstetrics and Gynecology, Karolinska Institutet; <sup>4</sup>Department of Women's and Children's Health, Division of Pediatric Oncology, Karolinska Institutet; <sup>5</sup>Department of Gynecology, Division of Gynecology and Reproduction, Karolinska University Hospital; <sup>6</sup>Department of Cellular Therapy and Allogeneic Stem Cell Transplantation, Karolinska University Hospital and Division of Hematology, Department of Medicine Huddinge, Karolinska Institutet and <sup>7</sup>Department of Molecular Medicine and

Surgery, Karolinska Institutet and Department of Clinical Genetics, Laboratory Division Karolinska University Hospital, Stockholm, Sweden

Correspondence: KENNY A. RODRIGUEZ-WALLBERG - kenny.rodriguez-wallberg@ki.se

doi:10.3324/haematol.2021.278828

Received: March 23, 2021.

Accepted: June 28, 2021.

Pre-published: July 8, 2021.

Disclosures: the authors declare that they have no competing financial interests.

Contributions: KARW designed the study, performed surgery and assisted reproductive treatments, collected and analyzed data, and wrote the manuscript together with MM and GB; MM, KP, RP performed surgery; FS, IW and MM performed assisted reproductive treatments; VK performed cryopreservation and thawing of ovarian tissue; BG, BB and PL collected data on clinical follow-up; GB performed the molecular investigations for evaluation of ovarian tissue. All authors approved the last version of the manuscript.

Acknowledgments: we are grateful to Hanna Nilsson at Karolinska Institutet for expert assistance in the preparation of the manuscript. We kindly acknowledge Katja Pokrovskaja Tamm for her expert assistance at the childhood leukemia biobank of Karolinska Institutet.

*Funding:* this study was supported by research grants from the Swedish Childhood Cancer Fund (grant number KP2016-0031, PR2016-0115), the Swedish Cancer Society (grant number CAN 2017/704), Radiumhemmets Research Funds (grant number 201313, 181272), the Stockholm county council (grant number 20160626) and Karolinska Institutet (grant number 2020-00339) (to KARW). The funding sources have played no role in the research design, analysis or reporting.

*Ethical approval:* ethical approval for the study of children undergoing gonadal tissue cryopreservation aiming at fertility preservation and for the follow-up of patients to adulthood was granted by the Ethical Review Board of Karolinska University Hospital (Dnr. 427/03) and the Regional Ethics Committee of Stockholm (Dnr. 2011/1158-31/2, 2014/470-32, 2016/2530-32 and 2018/2255-32). The patient has given her written informed consent to publish and discuss the case and the pictures here included. The patient has also read and approved the submission of this manuscript.

## References

- Rodriguez-Wallberg KA, Tanbo T, Tinkanen H, et al. Ovarian tissue cryopreservation and transplantation among alternatives for fertility preservation in the Nordic countries - compilation of 20 years of multicenter experience. *Acta Obstet Gynecol Scand.* 2016; 95(9):1015-1026.
- Rodriguez-Wallberg KA, Marklund A, Lundberg F, et al. A prospective study of women and girls undergoing fertility preservation due to oncologic and non-oncologic indications in Sweden-Trends in patients' choices and benefit of the chosen methods after long-term follow up. *Acta Obstet Gynecol Scand.* 2019;98(5):604-615.
- Shapira M, Raanani H, Barshack I, et al. First delivery in a leukemia survivor after transplantation of cryopreserved ovarian tissue, evaluated for leukemia cells contamination. *Fertil Steril.* 2018;109(1):48-53.
- Silber SJ, DeRosa M, Goldsmith S, Fan Y, Castleman L, Melnick J. Cryopreservation and transplantation of ovarian tissue: results from one center in the USA. *J Assist Reprod Genet.* 2018;35(12):2205-2213.
- Sonmezer M, Ozkavukcu S, Sukur YE, Kankaya D, Arslan O. First pregnancy and live birth in Turkey following frozen-thawed ovarian tissue transplantation in a patient with acute lymphoblastic leukemia who underwent cord blood transplantation. *J Assist Reprod Genet.* 2020;37(8):2033-2043.
- Keros V, Xella S, Hultenby K, et al. Vitrification versus controlled-rate freezing in cryopreservation of human ovarian tissue. *Hum Reprod.* 2009;24(7):1670-1683.
- Gabert J, Beillard E, van der Velden VH, et al. Standardization and quality control studies of 'real-time' quantitative reverse transcriptase polymerase chain reaction of fusion gene transcripts for residual disease detection in leukemia - a Europe Against Cancer program. *Leukemia.* 2003;17(12):2318-2357.
- Poirot C, Fortin A, Dhedin N, et al. Post-transplant outcome of ovarian tissue cryopreserved after chemotherapy in hematologic malignancies. *Haematologica.* 2019;104(8):e360-e363.
- Meirow D, Ra'anani H, Shapira M, et al. Transplantations of frozen-thawed ovarian tissue demonstrate high reproductive performance and the need to revise restrictive criteria. *Fertil Steril.* 2016; 106(2):467-474.
- Dolmans MM, Marinescu C, Saussoy P, Van Langendonck A, Amorim C, Donnez J. Reimplantation of cryopreserved ovarian tissue from patients with acute lymphoblastic leukemia is potentially unsafe. *Blood.* 2010;116(16):2908-2914.
- Meirow D, Hardan I, Dor J, et al. Searching for evidence of disease and malignant cell contamination in ovarian tissue stored from hematologic cancer patients. *Hum Reprod.* 2008;23(5):1007-1013.
- Rosendahl M, Andersen MT, Ralfkiaer E, Kjeldsen L, Andersen MK, Andersen CY. Evidence of residual disease in cryopreserved ovarian cortex from female patients with leukemia. *Fertil Steril.* 2010; 94(6):2186-2190.
- Greve T, Clasen-Linde E, Andersen MT, et al. Cryopreserved ovarian cortex from patients with leukemia in complete remission contains no apparent viable malignant cells. *Blood.* 2012;120(22):4311-4316.
- Jahnukainen K, Tinkanen H, Wikstrom A, et al. Bone marrow remission status predicts leukemia contamination in ovarian biopsies collected for fertility preservation. *Leukemia.* 2013;27(5):1183-1185.
- Chevillon F, Clappier E, Arfeuille C, et al. Minimal residual disease quantification in ovarian tissue collected from patients in complete remission of acute leukemia. *Blood.* 2021;137(12):1697-1701.