

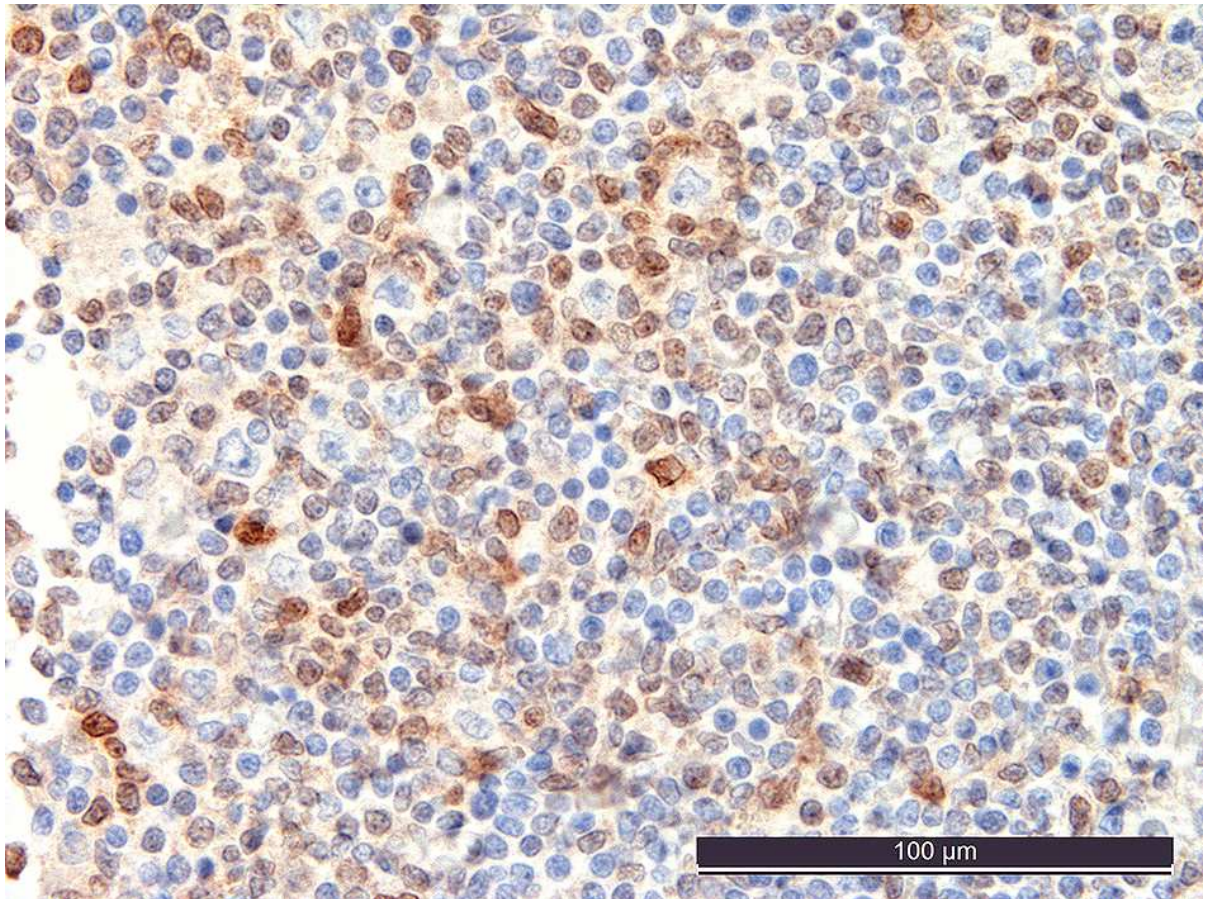
SMAD1 promoter hypermethylation and lack of SMAD1 expression in Hodgkin lymphoma: a potential target for hypomethylating drug therapy

Magdalena M. Gerlach,¹ Anna Stelling-Germani,² Cheuk Ting Wu,² Sebastian Newrzela,³ Claudia Döring,³ Visar Vela,¹ Anne Müller,² Sylvia Hartmann³ and Alexandar Tzankov¹

¹Institute of Medical Genetics and Pathology, University of Basel, Basel, Switzerland; ²Institute of Molecular Cancer Research, University of Zurich, Zurich, Switzerland and ³Institute of Pathology, Department of Pathology, Goethe University Frankfurt on Main, Germany

Correspondence: ALEXANDAR TZANKOV - alexandar.tzankov@usb.ch

doi:10.3324/haematol.2020.249276



Suppl. Figure 1: Expression of SMAD1 in nodular lymphocyte predominant (LP) Hodgkin lymphoma

Substantial amounts of SMAD1 positive tumor-infiltrating lymphocytes including such that rim the neoplastic LP cell. Note that the large LP cells, including the rimmed one, are negative.

Immunoperoxidase staining, magnification 400x.