

Utility of clinical comprehensive genomic characterization for diagnostic categorization in patients presenting with hypocellular bone marrow failure syndromes

Piers Blombery,^{1,2,3} Lucy C. Fox,^{3,4,5*} Georgina L. Ryland,^{3*} Ella R. Thompson,^{2,3} Jennifer Lickiss,³ Michelle McBean,³ Satwica Yerneni,³ David Hughes,⁶ Anthea Greenway,⁶ Francoise Mechinaud,⁶ Erica M. Wood,⁵ Graham J. Lieschke,^{1,7} Jeff Szer,¹ Pasquale Barbaro,⁸ John Roy,⁸ Joel Wight,⁹ Elly Lynch,^{10,11,12} Melissa Martyn,^{10,11,12} Clara Gaff^{2,10,12} and David Ritchie¹

¹Clinical Hematology, Peter MacCallum Cancer Center/Royal Melbourne Hospital, Melbourne, Victoria; ²University of Melbourne, Melbourne, Victoria; ³Department of Pathology, Peter MacCallum Cancer Center, Melbourne, Victoria; ⁴Epworth Healthcare, Melbourne, Victoria; ⁵Transfusion Research Unit, School of Public Health & Preventive Medicine, Monash University, Melbourne, Victoria; ⁶Royal Children's Hospital, Melbourne, Victoria; ⁷Australian Regenerative Medicine Institute, Monash University, Melbourne, Victoria; ⁸Children's Health Queensland and University of Queensland, South Brisbane, Queensland; ⁹Department of Hematology, Austin Health, Melbourne, Victoria; ¹⁰Melbourne Genomics Health Alliance, Melbourne, Victoria; ¹¹Victorian Clinical Genetics Service, Melbourne, Victoria and ¹²Murdoch Children's Research Institute, Melbourne, Victoria, Australia

*LCF and GLR contributed equally as co-second authors

©2021 Ferrata Storti Foundation. This is an open-access paper. doi:10.3324/haematol.2019.237693

Received: September 6, 2019.

Accepted: February 7, 2020.

Pre-published: February 13, 2020.

Correspondence: PIERS BLOMBERG - piers.blombery@petermac.org

Supplementary Material

Utility of clinical comprehensive genomic characterisation for diagnostic categorisation in patients presenting with hypocellular bone marrow failure syndromes

Piers Blombery^{1,2,3}, Lucy Fox^{3,4,5*}, Georgina L. Ryland^{3*}, Ella R. Thompson^{2,3}, Jennifer Lickiss³, Michelle McBean³, Satwica Yerneni³, David Hughes⁶, Anthea Greenway⁶, Françoise Mechinaud⁶, Erica M. Wood⁵, Graham J. Lieschke^{1,7}, Jeff Szer¹, Pasquale Barbaro⁸, John Roy⁸, Joel Wight⁹, Ella Lynch^{10,11,12}, Melissa Martyn^{10,11,12}, Clara Gaff^{2, 10,12}, David Ritchie¹

¹Clinical Haematology, Peter MacCallum Cancer Centre/Royal Melbourne Hospital, Melbourne, Australia

²University of Melbourne, Melbourne, Australia

³Department of Pathology, Peter MacCallum Cancer Centre, Melbourne, Australia

⁴Epworth Healthcare, Melbourne, Australia

⁵Transfusion Research Unit, School of Public Health & Preventive Medicine, Monash University, Melbourne, Australia

⁶Royal Children's Hospital, Melbourne, Australia

⁷Australian Regenerative Medicine Institute, Monash University

⁸Children's Health Queensland and University of Queensland

⁹Department of Haematology, Austin Health, Melbourne, Australia

¹⁰Melbourne Genomics Health Alliance

¹¹Victorian Clinical Genetics Service, Melbourne Australia

¹²Murdoch Children's Research Institute, Melbourne Australia

**these authors contributed equally to this work*

Supplementary Methods

Study design

This was a prospective study of patients presenting with bone marrow failure (BMF) through the Peter MacCallum Cancer Centre, The Royal Melbourne Hospital, Royal Children's Hospital and Austin Hospital, Victoria, Australia. Eligibility criteria were (i) age ≥ 3 months (ii) a clinicopathological diagnosis of either acquired aplastic anaemia (aAA), an inherited/genetic BMF syndrome (IBMFS), hypoplastic myelodysplastic syndrome (hMDS) or a BMF syndrome characterised by marrow hypoplasia/aplasia but not able to be definitively categorised. All participants were under ongoing investigation into the cause of their BMF. Patients (or their guardians) provided written informed consent after pre-test counselling and assessment. Research was conducted after institutional review board ethics approval

(HREC/13/MH/326 and HREC/17/PMCC/163) and all research was conducted in accordance with the Declaration of Helsinki.

Targeted sequencing

Patient samples including peripheral blood, bone marrow aspirate, buccal swab, skin biopsy and cultured skin fibroblasts were analysed using three NGS-based sequencing panels, as described below.

BMF panel

DNA (300 ng) was sheared by focused acoustic sonication (Covaris, MA, USA) and libraries prepared using the KAPA Hyper Prep Kit (KAPA Biosystems, MA, USA), followed by enrichment using a custom SureSelectXT hybridisation-based capture panel (Agilent, CA, USA) and sequenced on an Illumina NextSeq500 (Illumina, CA, USA) with 75 bp paired-end reads. After base calling and de-multiplexing, a Seqliner-framework analysis pipeline was used to align reads to the human reference genome (GRCh37 assembly) using BWA-MEM, followed by marking of duplicate reads, base quality score recalibration, local indel realignment and germline variant calling using GATK Haplotype Caller. In addition the targeted panel aligned sequence data was processed through a dedicated bioinformatics pipeline which included variant calling with GATK4/Mutect2 (<https://software.broadinstitute.org/gatk/>) in order to improve detection of low level acquired variants. VCFs were analysed in PathOS including variants occurring within the coding regions and flanking splice sites (within 2 bp) of the 85 genes and transcripts listed in Supplementary Table 1. The BMF panel includes genes implicated in both IBMFS and aAA. Acquired variants were curated for pathogenicity as above. Germline variants were classified according to the American College of Medical Genetics and Genomics standards for interpretation of sequence variants¹ and reviewed at a series of multidisciplinary team meetings. Pathogenic and likely pathogenic variants of clinical significance were confirmed by an alternative method. Only pathogenic and likely pathogenic variants are included in the description of this cohort. Some variants were also investigated in parental samples to establish phase and segregation. Genome-wide copy number analysis was performed by comparing read counts from on and off target reads to a pooled reference to correct for enrichment and sequencing biases².

Whole exome sequencing

SureSelectQXT (Agilent) libraries were prepared from 50 ng DNA followed by targeted enrichment using the Clinical Research Exome V1 (Agilent) and sequenced on an Illumina HiSeq 4000 (Illumina) with 150 bp paired-end reads. A Seqliner-framework analysis pipeline and germline variant curation in PathOS was performed as described above. *ANKRD26*, *DNAJC21*, *ETV6*, *SAMD9*, *SAMD9L*, *SMARCD2*, *SRP54* and *THPO* were assessed in all patients in addition to all genes present in the targeted panel (93 genes listed in Supplementary Table 1). If no causative variant was identified, whole exome sequencing (WES) analysis was extended to include additional genes based on the patient's clinical phenotype.

RNAseq

Samples for whole transcriptome sequencing were prepared using the TruSeq RNA Sample Preparation Kit (Illumina) from 1 µg total RNA according to standard protocols. Samples were sequenced on an Illumina NextSeq500 (Illumina) with 75 bp paired-end reads. Alignment was

performed using HISAT2 followed by generation of read counts using HTSeq. Quantile normalized counts were generated using Limma.

Droplet Digital PCR

Droplet digital PCR (ddPCR) analysis was performed using the Bio-Rad Droplet Digital PCR system (Bio-Rad, CA, USA) following manufacturer's protocols. An allele-specific PCR assay to detect and quantify the fractional abundance of the *RUNX1* c.496C>T variant and corresponding wildtype allele was custom designed using PrimePCR (BioRad). Details of the *TERT* c.-124C>T ddPCR assay have been described previously³. ddPCR was performed using approximately 50 ng DNA per reaction on the QX200 Droplet Digital PCR System and data were analysed using QuantaSoft software, to a detection limit of 0.2%.

Supplementary Table 1. BMF genes assessed by panel and whole exome sequencing.

| Gene | Transcript | Targeted exons | Gene | Transcript | Targeted exons |
|----------|----------------|--------------------|----------|----------------|----------------|
| ACD | NM_001082486.1 | All coding | MPL | NM_005373.2 | All coding |
| AK2 | NM_013411.4 | All coding | NHP2 | NM_017838.3 | All coding |
| ANKRD26* | NM_014915.2 | All coding & 5'UTR | NOP10 | NM_018648.3 | All coding |
| ASXL1 | NM_015338.5 | 12 | NRAS | NM_002524.4 | 2-4 |
| ATR | NM_001184.3 | All coding | PALB2 | NM_024675.3 | All coding |
| BCOR | NM_017745.5 | All coding | PARN | NM_002582.3 | All coding |
| BCORL1 | NM_021946.4 | All coding | PIGA | NM_002641.3 | All coding |
| BRCA2 | NM_000059.3 | All coding | RAD51C | NM_058216.2 | All coding |
| BRIP1 | NM_032043.2 | All coding | RBM8A | NM_005105.4 | All coding |
| CALR | NM_004343.3 | 9 (AA352-400) | RPL11 | NM_000975.3 | All coding |
| CBL | NM_005188.3 | All coding | RPL15 | NM_002948.3 | All coding |
| CSF3R | NM_156039.3 | All coding | RPL26 | NM_000987.3 | All coding |
| CSMD1 | NM_033225.5 | All coding | RPL35A | NM_000996.2 | All coding |
| CTC1 | NM_025099.5 | All coding | RPL5 | NM_000969.3 | All coding |
| DDX41 | NM_016222.2 | All coding | RPS10 | NM_001014.4 | All coding |
| DKC1 | NM_001363.3 | All coding | RPS19 | NM_001022.3 | All coding |
| DNAJC21* | NM_194283.3 | All coding | RPS24 | NM_033022.3 | All coding |
| DNMT3A | NM_022552.4 | All coding | RPS26 | NM_001029.3 | All coding |
| ELANE | NM_001972.2 | All coding | RPS29 | NM_001032.4 | All coding |
| ERBB2 | NM_004448.2 | 8, 17, 19-21, 27 | RPS7 | NM_001011.3 | All coding |
| ERCC4 | NM_005236.2 | All coding | RTEL1 | NM_032957.4 | All coding |
| ERCC6L2 | NM_001010895.2 | All coding | RUNX1 | NM_001754.4 | All coding |
| ETV6* | NM_001987.4 | All coding | SAMD9* | NM_017654.3 | All coding |
| EZH2 | NM_004456.4 | All coding | SAMD9L* | NM_152703.2 | All coding |
| FANCA | NM_000135.2 | All coding | SBDS | NM_016038.2 | All coding |
| FANCB | NM_001018113.1 | All coding | SETBP1 | NM_015559.2 | 4 |
| FANCC | NM_000136.2 | All coding | SF3B1 | NM_012433.2 | 14-18 |
| FANCD2 | NM_001018115.1 | All coding | SH2D1A | NM_002351.4 | All coding |
| FANCE | NM_021922.2 | All coding | SLX4 | NM_032444.2 | All coding |
| FANCF | NM_022725.3 | All coding | SMARCA1 | NM_014140.3 | All coding |
| FANCG | NM_004629.1 | All coding | SMARCD2* | NM_001098426.1 | All coding |
| FANCI | NM_001113378.1 | All coding | SRP54* | NM_003136.3 | All coding |
| FANCL | NM_018062.3 | All coding | SRP72 | NM_006947.3 | All coding |
| FANCM | NM_020937.2 | All coding | SRSF2 | NM_003016.4 | 1 |
| G6PC3 | NM_138387.3 | All coding | TCIRG1 | NM_006019.3 | All coding |
| GATA1 | NM_002049.3 | All coding | TERT | NM_198253.2 | All coding |
| GATA2 | NM_032638.4 | All coding | TET2 | NM_001127208.2 | All coding |

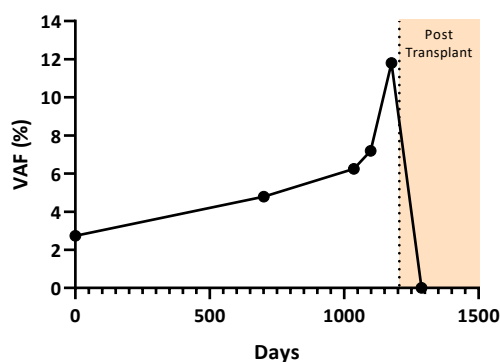
| | | | | | |
|-------|-------------|------------|--------|----------------|------------|
| GFI1 | NM_005263.3 | All coding | THPO* | NM_000460.2 | All coding |
| HAX1 | NM_006118.3 | All coding | TINF2 | NM_001099274.1 | All coding |
| IDH1 | NM_005896.2 | 4 | TP53 | NM_000546.5 | All coding |
| IDH2 | NM_002168.2 | 4 | U2AF1 | NM_006758.2 | 2, 6 |
| IKZF1 | NM_006060.4 | All coding | VPS45 | NM_007259.4 | All coding |
| JAGN1 | NM_032492.3 | All coding | WAS | NM_000377.2 | All coding |
| JAK2 | NM_004972.3 | All coding | WRAP53 | NM_018081.2 | All coding |
| JAK3 | NM_000215.3 | 11, 15, 16 | WT1 | NM_024426.4 | 7-9 |
| KIT | NM_000222.2 | All coding | ZRSR2 | NM_005089.3 | All coding |
| KRAS | NM_033360.2 | 2-4 | | | |

*Gene analysed by WES only

AA, amino acid.

Supplementary Clinical Data

Patient ID #4: A 5-year-old male presented shortly after birth with anaemia and thrombocytopenia requiring transfusion support. Bone marrow biopsy at 11 weeks of age demonstrated mild to moderate dyserythropoiesis and dysgranulopoiesis but insufficient morphological features for a formal diagnosis of a myelodysplastic syndrome. Metaphase cytogenetic analysis and FISH for chromosomes 5, 7 and 8 was normal. A nonsense variant in *RUNX1* [NM_001754.4:c.496C>T; p.(Arg166*)] was detected with targeted sequencing at 4.8% variant allele frequency. This variant was quantitatively monitored in the bone marrow over time by allele specific ddPCR and was noted to be steadily increasing and reaching 11.8% over a 15 month period (Supp Fig 1). The variant was not detected in a skin biopsy sample. The patient underwent a matched unrelated donor allogeneic bone marrow transplant with subsequent resolution of cytopenias.

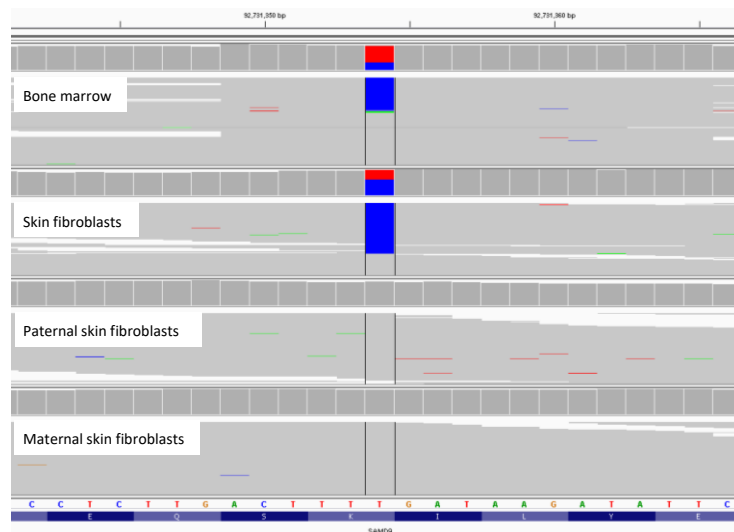
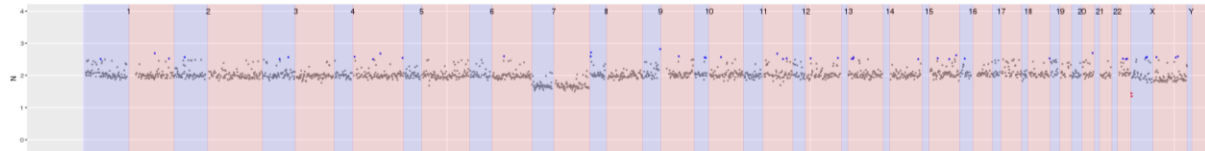


Supplementary Figure 1. Quantitation of *RUNX1* c.496C>T by droplet digital PCR over time in a 5-year-old with refractory cytopenia of childhood.

Patient ID #13: A 6-month-old female was noted to be severely anaemic at birth (haemoglobin 50 g/L) and experienced bilateral watershed cerebral infarcts, respiratory failure requiring intubation and anuria. A clinical diagnosis was unable to be made. BMF panel testing on bone marrow aspirate identified a heterozygous missense variant in *RPS19* [NM_001022.3:c.184C>T; p.(Arg62Trp)] providing a diagnosis of Diamond-Blackfan anaemia. The *RPS19* Arg62Trp has been described in multiple families as both a *de novo* and an inherited variant segregating with Diamond-Blackfan anaemia with an autosomal dominant mode of inheritance⁴⁻⁶. The patient had significant clinical improvement upon introduction of steroids and resolution of the profound anaemia, and continues on low-dose prednisolone daily.

Patient ID #14: A 4-year-old male was noted to have incidentally identified anaemia aged 12 months. A clinicopathological diagnosis of Diamond-Blackfan anaemia was made based on bone marrow aspirate and trephine demonstrating severe red cell hypoplasia in the setting of gradual onset anaemia and marked macrocytosis. No genetic testing was performed at the time of this clinical diagnosis. BMF panel testing identified a frameshift variant in *RPS19* [NM_001022.3:c.251_252del; p.(Arg84Lysfs*69)]. Parental testing confirmed the *de novo* origin of this variant. This variant has previously been described in a patient with Diamond-Blackfan anaemia ⁵.

Patient ID #20: A 5-year-old female had dysmorphic features including squared and dysplastic ears with hypoplastic lobes, and scaphocephaly. She was born pre-term (36 weeks gestation) requiring ventilation support and admission for sepsis, thrombocytopenia and mild anaemia. At 3 months of age she was diagnosed with CMV colitis resulting in a sigmoid stricture and a large bowel obstruction that required surgical correction and nasogastric tube feeding until 2 years of age. There was no family history of an IBMFS. Bone marrow biopsy performed shortly after birth was normocellular with subtle trilineage dysplasia, and monosomy 7 was detected by metaphase cytogenetics and FISH. Repeat biopsy at 2-3 month intervals consistently detected the monosomy 7 by FISH but at reducing frequency until becoming undetectable over a period of approximately 32 months. Trilineage dysplasia remained stable over this time period, with some minor improvement noted at the time of monosomy 7 resolution. WES performed on a stored bone marrow aspirate sample (collected 5 months after birth) identified a NM_017654.3:c.4057A>G; p.(Lys1353Glu) missense variant in *SAMD9* at approximately 30% variant allele frequency, along with the presence of monosomy 7 (Supp Fig 2A & B). Testing of DNA from skin fibroblasts from the patient and her parents confirmed a germline *de novo* origin of this variant. The Lys1353Glu has not been reported in population databases or in clinical case series of patients with bone marrow failure.

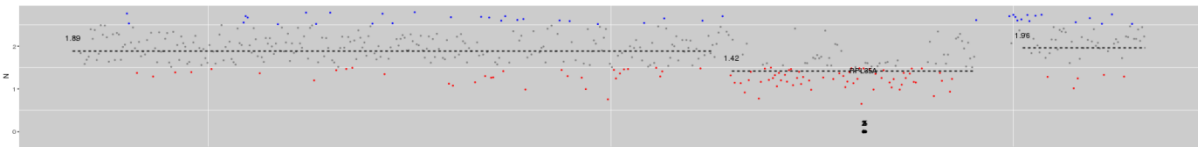
A**B**

Supplementary Figure 2. (A) *SAMD9* Lys1353Glu detected in bone marrow and skin fibroblast samples from a 5-year-old with BMF. This variant was not detected in DNA from either parent. (B) Monosomy 7 detected in a bone marrow sample collected 5 months after birth.

Patient ID #23: A 7-year-old male was incidentally discovered to have monosomy 7 by SNP array while being investigated for autism spectrum disorder at 2 years of age. There was no history of BMF in the family. A bone marrow biopsy was hypocellular with trilineage dysplasia and no blast excess. WES identified a previously unreported missense variant in *SAMD9* [NM_017654.3:c.2318T>C; p.(Ile773Thr)] which was confirmed to be *de novo* through parental testing. The patient was treated with 6 cycles of azacitidine. The monosomy 7 clone reduced from 86% to 19% measured by FISH over this 6 month time period however whether this was due to azacitidine or spontaneous resolution (as is occasionally observed in *SAMD9* and related abnormalities⁷) cannot be definitively determined. The patient underwent an unrelated cord blood transplant and is in an ongoing complete response with full donor chimerism.

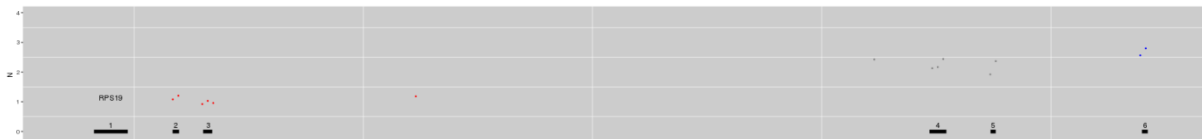
Patient ID #25: A 14-year-old female presented at birth with severe anaemia and neutropenia. There was no family history of an IBMFS. Bone marrow biopsy was normocellular with markedly reduced erythropoiesis and myeloid maturation arrest. The patient was not responsive to corticosteroids and remained transfusion-dependent with persistent neutropenia and recurrent infections. A

heterozygous deletion on chromosome 3 involving *RPL35A* was detected by BMF panel copy number analysis (Supp Fig 3). Subsequent copy number analysis by SNP array confirmed a terminal deletion of approximately 0.5 Mb on the long arm of one chromosome 3. In addition, the long arm of chromosome 3 showed an apparently acquired genotyping profile consistent with progressive copy number neutral loss of heterozygosity increasing from 10% near the centromere to 30% towards the telomere, similar to that previously described in two siblings with Diamond-Blackfan anaemia and a *RPL35A* deletion⁸.



Supplementary Figure 3. Copy number analysis from BMF panel showing heterozygous deletion of *RPL35A*.

Patient ID #31: A 16-year-old male presented at 11 weeks of age with severe anaemia. There were no dysmorphic features or developmental delay and no family history of an IBMFS. A bone marrow biopsy demonstrated marked erythroid hypoplasia. The anaemia responded to corticosteroid treatment however the patient remained steroid-dependent until approximately 10 years of age when he was successfully weaned off. Copy number analysis identified a heterozygous deletion of exons 2 and 3 in *RPS19* (Supp Fig 4).

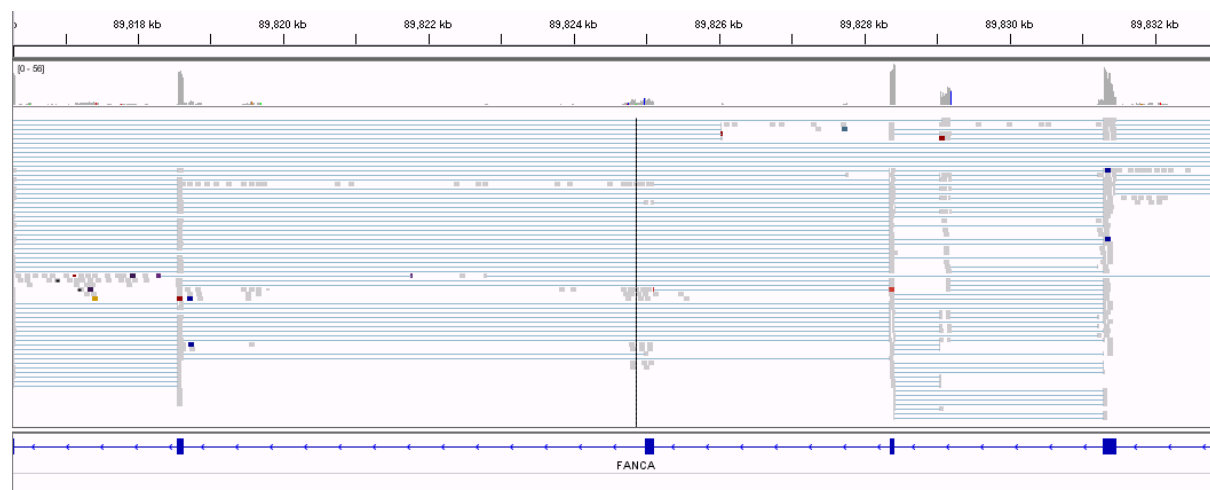


Supplementary Figure 4. Copy number analysis from BMF panel showing heterozygous deletion of *RPS19* exons 2-3.

Patient ID #32: A 5-year-old female had presented as an infant with cellulitis and was noted to be neutropenic. Both her mother and maternal grandmother had also experienced lifelong severe neutropenia, but generally experienced good health (with occasional hospital admissions for infection only) and did not required G-CSF therapy regularly. The child was developmentally normal with no additional medical issues. WES detected a heterozygous in-frame deletion in *SRP54* [NM_003136.3:c.349_351del; p.(Thr117del)]. The Thr117del is the most commonly described variant in *SRP54* in case series of severe congenital neutropenia to date and has been described as both a *de novo* and an inherited variant segregating with an autosomal dominant mode of inheritance^{9, 10}. The

SRP54 Thr117del was subsequently detected in both her mother and grandmother, providing a genetic diagnosis to three generations of a family who had experienced uncharacterised BMF for over 50 years.

Patient ID #39: A 27-year-old otherwise well female presented with pancytopenia. No congenital abnormalities were present on physical exam. Bone marrow aspirate and trephine demonstrated marked hypocellularity. Eltrombopag was commenced for presumed aplastic anaemia without improvement in blood counts. There was no family history of an IBMFS, however consanguinity was noted. SNP array testing on a peripheral blood sample demonstrated long continuous stretches of homozygosity (>5Mb) on chromosomes 4, 6, 7, 16, 19 and 21 representing approximately 6% of the genome. BMF panel testing on bone marrow aspirate demonstrated a homozygous *FANCA* missense variant [NM_000135.2:c.2980A>G; p.(Ser994Gly)]. This variant occurs within the conserved splice sequence motif of the exon 30/intron 30 splice donor site and RNAseq analysis from unselected bone marrow cells showed skipping of exon 30 (Supp Fig 5). Chromosomal breakage studies (using diepoxybutane) performed on peripheral blood as well as cultured skin fibroblasts were both equivocal with evidence of increased chromosomal break relative to negative control but insufficient for a positive result. However, absence of monoubiquitination of FANCD2 in PHA-stimulated blood cells on western blot was observed consistent with inactivation of *FANCA* and a diagnosis of Fanconi anaemia.

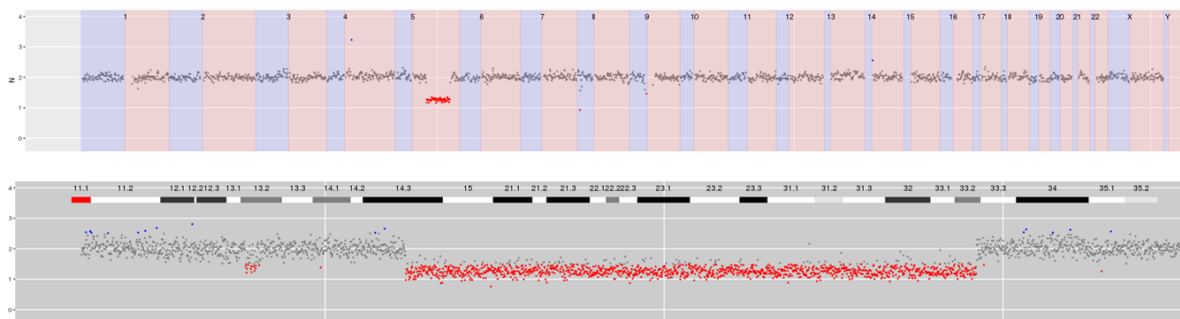


Supplementary Figure 5. RNAseq from bone marrow cells showing exon 30 skipping in *FANCA* as a result of NM_000135.2: c.2980A>G; p.(Ser994Gly).

Patient ID #44: A 35-year-old male presented at birth with tetralogy of Fallot and atrioventricular canal defect requiring multiple cardiothoracic operations. He was of short stature with a webbed neck, dysmorphic facies and earlobes, and lacked thumb bones bilaterally. Other medical issues included a solitary kidney, obstructive sleep apnoea, type two diabetes mellitus, scoliosis with restrictive lung disease and learning difficulties. His sibling had died at age 2 following complications related to cardiothoracic surgery to repair an atrioventricular septal defect and coarctation of the aorta and perform pulmonary artery banding. Chromosomal fragility studies using mitomycin C demonstrated increased breakage in the patient cells. BMF panel testing of peripheral blood demonstrated a homozygous missense *RAD51C* variant [NM_058216.2:c.773G>A; p.(Arg258His)]. This variant has previously been observed in the homozygous state in a single family with infants displaying a Fanconi anaemia-like disorder characterised by congenital heart disease, thumb, renal, intestinal and anal abnormalities. Experimental evidence is consistent with this variant being a hypomorphic mutant that results in increased chromosomal disruption and cell cycle arrest¹¹⁻¹³. The patient's sister was subsequently referred for predictive testing with regard to her possible risk of breast and ovarian cancer.

Patient ID #47: A 64-year-old male presented with pancytopenia. He had been diagnosed in early adulthood with cerebellar ataxia of unclear cause. His brother and mother had also experienced cerebellar ataxia. Bone marrow aspirate and trephine demonstrated marked hypocellularity with some fibrosis and he commenced immunosuppressive therapy for presumed aAA. There was no response to immunosuppressive therapy and he subsequently commenced eltrombopag. Repeat bone marrow aspirate and trephine demonstrated a mild increase in blasts and cytogenetic clonal progression (46,XY,t(3;21)(q26;q22)) and eltrombopag was ceased. Targeted sequencing performed on peripheral blood demonstrated a *CBL* variant [NM_005188.3:c.1259G>C; p.(Arg420Pro)] at a variant allele frequency of 7.5% consistent with the presence of clonal haematopoiesis. WES on peripheral blood identified a heterozygous missense variant in *SAMD9L* [NM_152703.2:c.2956C>T; p.(Arg986Cys)]. This variant has been reported in a family with ataxia-pancytopenia (ATXPC) syndrome and *in vitro* evidence demonstrates that this variant is gain-of-function, enhancing the growth suppressing activity of *SAMD9L*¹⁴. The patient subsequently presented with circulating blasts and bone marrow aspirate and trephine demonstrated progression to acute myeloid leukaemia. He died of infectious complications during induction chemotherapy. The patient's children and family were subsequently referred for predictive testing.

Patient ID #52: A previously well 41-year-old female presented with severe anaemia. Bone marrow aspirate and trephine was performed and demonstrated marked erythroid hypoplasia. A provisional diagnosis of pure red cell aplasia was made based on bone marrow assessment. There was no evidence of parvovirus or thymoma and she was commenced on cyclosporine and corticosteroid. BMF panel testing on peripheral blood identified a large deletion of chromosome 5 spanning the region 5q14.3-33.2 which was confirmed with the finding of isolated deletion of 5q by conventional cytogenetics and a diagnosis of myelodysplastic syndrome with isolated del(5q) according to WHO 2016 diagnostic criteria was made (Supp Fig 6). On review, the marrow demonstrated subtle dysplastic features, in particular hypolobated megakaryocytes. The patient was commenced on lenalidomide with resolution of anaemia.



Supplementary Figure 6. Interstitial deletion of the long arm of chromosome 5 spanning the region 5q14.3-33.2.

Patient ID #53: An 11-year-old male was referred for genetic testing after developing persistent and severe pancytopenia following consolidation therapy containing cyclophosphamide (COG AALL1231) for T-acute lymphoblastic lymphoma. BMF panel testing identified two nonsense variants in *FANCM* [NM_020937.2:c.1972C>T; p.(Arg658*) and NM_020937.2:c.5101C>T; p.(Gln1701*)], both of which have been previously reported in cases of severe chemotherapy toxicity^{15, 16}. There was no family history of a IBMFS or cancer predisposition, and no congenital malformations or previous abnormal blood parameters suggestive of Fanconi anaemia. Chromosome breakage studies using diepoxybutane on peripheral blood and tissue fibroblast cultures demonstrated a slight increase in the number of chromosome breaks compared to the control but below the number typically seen in Fanconi anaemia. Further chemotherapy was subsequently modified with reduced toxicity and ongoing response to therapy.

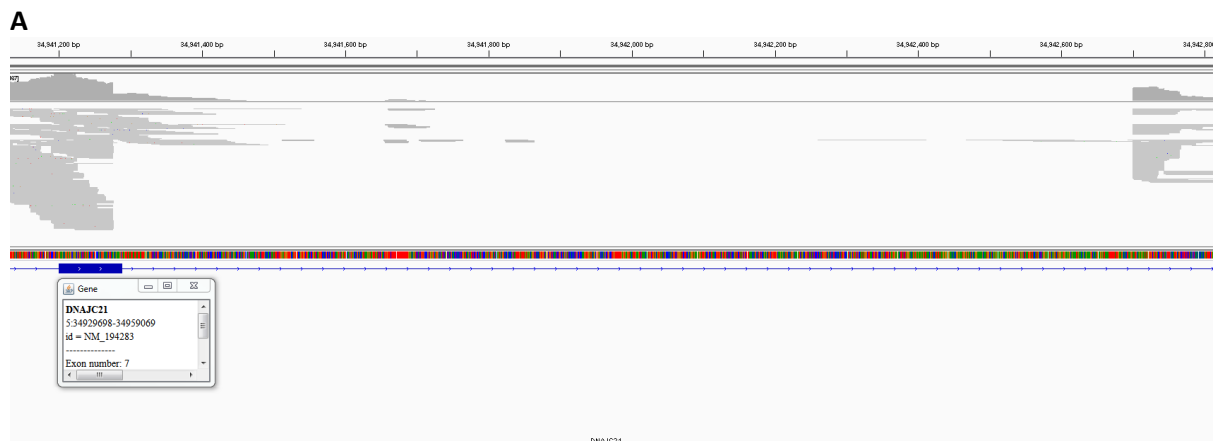
Patient ID #60: A 12-month-old male had presented with petechiae due to severe thrombocytopenia (platelets $5 \times 10^9/L$) at 8 months of age. He had microcephaly, orbital hypertelorism, leukoplakia and had so far demonstrated normal development. Investigations showed severe retinopathy and cerebellar hypoplasia. Telomere lengths of the patient's mononuclear cells were low normal ($\geq 1^{\text{st}}$ and $< 10^{\text{th}}$ percentile). BMF panel testing on peripheral blood detected two heterozygous missense variants in *TERT* [NM_198253.2:c.3148A>G; p.(Lys1050Glu) and c.1670T>C; p.(Leu557Pro)]. *Trans* inheritance was inferred by the demonstration of the Lys1050Glu maternally and the Leu557Pro paternally. The Lys1050Glu has previously been reported in a kindred with familial idiopathic pulmonary fibrosis where the index case was shown to have short telomeres¹⁷. In addition, *in vitro* telomerase activity assays have demonstrated some effect of the Lys1050Glu variant on enzyme function and processivity relative to wild type *TERT*^{17, 18} with structural analyses suggestive of a possible role for nucleic acid binding at or near this residue in the hThumb domain¹⁸. The Leu557Pro is not present in population databases (gnomAD) and is undescribed in both the literature and relevant disease databases (ClinVar, Arizona State University Telomerase Database) but occurs in the highly conserved RNA binding (TRBD) domain responsible for TERT-TER complex formation enabling telomeric DNA repeat synthesis¹⁹. Both of these variants were shown to impair TERT function in *in vitro* assays (manuscript in preparation).

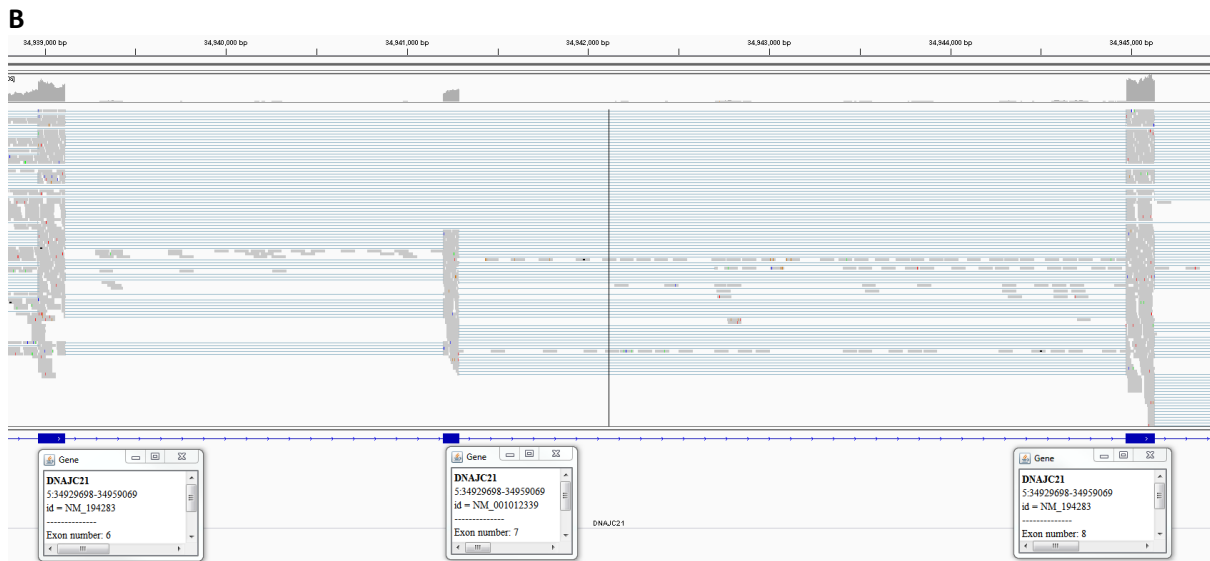
Patient ID #62: A 2-year-old male was born pre-term (33 weeks gestation). He required transfusion support for thrombocytopenia as a neonate. He experienced poor growth and multiple respiratory infections from the age of 4 months requiring hospitalisation. Bone marrow biopsy demonstrated marked left-shifted granulopoiesis with mild to moderate dysplasia of the megakaryocyte and erythroid lineages. Monosomy 7 was detected by metaphase cytogenetics. Chromosome breakage studies and faecal elastase were normal, and he had a normal appearing pancreas and skeletal survey. WES detected a *SAMD9* variant [NM_017654.3:c.2318T>C; p.(Ile773Thr)] at a variant allele frequency of approximately 26%, consistent with the presence of a monosomy 7 as demonstrated by the BMF panel. The Ile773Thr was detected in a hair follicle sample and testing of parental samples demonstrated it to be *de novo*. The patient underwent a matched sibling donor allogeneic bone marrow transplant.

Patient ID #67: A 2-year-old female presented with severe macrocytic anaemia and watershed cerebral infarction. She had a history of mild hydrocephalus, subclinical hypothyroidism and ear anomalies. There was no significant family history. Bone marrow biopsy was hypocellular with

markedly reduced erythropoiesis. Red cell adenosine deaminase (ADA) was elevated. An *RPS19* missense variant [NM_001022.3:c.184C>T; p.(Arg62Trp)] was detected which was confirmed to be *de novo* through parental testing.

Patient ID #69: A 3-month-old male born to consanguineous parents was noted to have neutropenia after presenting at birth with respiratory distress and hypoglycaemia. There was no history of recurrent infections. He was noted to have an increased head circumference and subsequently underwent an MRI brain demonstrating a small subdural haemorrhage but no structural abnormalities. Examination revealed mild transaminitis and hepatosplenomegaly but no pancreatic insufficiency or other dysmorphic features. The parents reported a history of multiple early deaths in the family leading to the suspicion of an inherited disorder. Bone marrow aspirate and trephine was normocellular with non-diagnostic features. WES of a bone marrow sample detected a large deletion (1426 bp) in *DNAJC21* involving part of exon 7 and the splice donor site at the exon 7/intron 7 boundary (c.972_983+1414del), which was confirmed in peripheral blood (Supp Fig 7A). The presence of wildtype reads suggested that this variant was heterozygous, and *DNAJC21* was not with a region of homozygosity based on microarray analysis. RNA studies (by RNAseq) were consistent with the presence of a transcript with skipping of exon 7 (Supp Fig 7B). No other sequence variants or exon level deletions were detected. The family was referred for genetic counselling and segregation analysis.





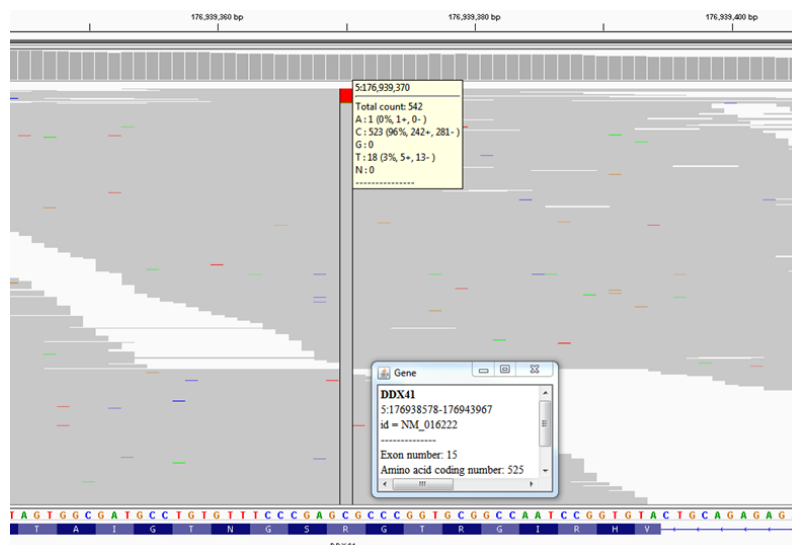
Supplementary Figure 7. (A) WES demonstrating a c.972_983+1414del involving exon 7 of *DNJC21*, with corresponding paired reads mapped to a region within intron 7. (B) Alignment of RNAseq reads demonstrating an aberrant transcript with skipping of exon 7.

Patient ID #76: A 33-year-old male presented in childhood with fingernail changes and moderate thrombocytopenia. Bone marrow biopsy demonstrated marked hypocellularity and a clinical diagnosis of dyskeratosis congenita was made. There was no family history of an IBMFS. BMF panel testing of peripheral blood detected a heterozygous missense *TINF2* variant [NM_001099274.1:c.844C>T; p.(Arg282Cys)], which has previously been observed in multiple families as both *de novo* and as an inherited variant segregating with dyskeratosis congenita with an autosomal dominant mode of inheritance^{20, 21}. The *TINF2* variant was subsequently detected in this patient's son, who had severe thrombocytopenia (platelets 10-20 x 10⁹/L) and bilateral exudative retinopathy (Revesz syndrome).

Patient ID #81: A 13-year-old male was being managed for severe refractory immune thrombocytopenia, which had been diagnosed when he presented aged 10 with platelets <10 x 10⁹/L and marked epistaxis. Bone marrow aspirate and trephine demonstrated a moderately hypocellular marrow with significant dysmegakaryopoiesis. He was also found to be hypogammaglobulinaemic, with an IgG of 4.4g/L. Initially he had a moderate response to immunosuppression however this was not sustained. His family history was significant for his maternal grandfather having been diagnosed in adulthood with immune thrombocytopenia and his mother's first cousin having had a splenectomy for refractory immune thrombocytopenia. WES of peripheral blood detected a heterozygous splice site variant in *DDX41* [NM_016222.2:c.435-2_435-1delinsCA; p.?]. This variant occurs at the splice acceptor site of the intron 5/exon 6 boundary and is predicted to result in abnormal splicing. This

variant has been previously reported in one family with a history of myelodysplastic syndrome and leukaemia²².

Patient ID #82: A 69-year-old female with a long standing history of neutropenia (approximately 15 years) had previously received chemotherapy for breast cancer diagnosed at age 66. The patient had no relevant family history. A bone marrow biopsy performed for recent progressive cytopenias demonstrated moderate to marked hypocellularity with trilineage dysplasia and 6% blasts. Conventional cytogenetics did not identify any abnormalities. A *DDX41* missense variant [NM_016222.2:c.517G>A; p.(Gly173Arg)] was detected which has recently been described in five patients presenting with a similar clinical phenotype²³. Consistent with the five cases reported to date, deep sequencing of *DDX41* in this patient also identified a recurrent somatic *DDX41* variant [NM_016222.2:c.1574G>A; p.(Arg525His)] present at 3.3% variant allele frequency (Supp Fig 8).



Supplementary Figure 8. Somatic *DDX41* Arg525His detected in a 69-year-old female with a germline Gly173Arg *DDX41* variant.

Patient ID #85: A 33-year-old female was diagnosed with Fanconi anaemia in childhood as a result of short stature, short thumbs, bilaterally absent index fingers and mild cognitive and hearing impairment. She subsequently experienced premature ovarian failure, primary biliary cirrhosis and severe chronic obstructive pulmonary disease despite no personal smoking history. BMF panel testing demonstrated two heterozygous *FANCI* variants [NM_00113378.1:c.3184C>T; p.(Gln1062*) and NM_00113378.1:c.3041G>A; p.(Cys1014Tyr)]. The Cys1014Tyr missense variant has been described

in three patients with a clinical diagnosis of Fanconi anaemia, one of whom was homozygous for the Cys1014Tyr²⁴ and two in the compound heterozygous state with truncating *FANCI* variants^{25, 26}.

Patient ID #87: A 49-year-old male presented with pancytopenia. A bone marrow biopsy demonstrated marked hypocellularity. No PNH clone was detected on peripheral blood. A diagnosis of aAA was made and the patient commenced immunosuppressive therapy with anti-thymocyte globulin/cyclosporine with minimal improvements in blood counts. BMF panel testing of peripheral blood detected a novel *TERT* variant [NM_198253.2:c.1223T>C; p.(Leu408Pro)]. In addition, a frameshift *BCOR* variant [NM_017745.5:c.3549_3561dup; p.(Val1188Metfs*27)] was also detected (16% variant allele frequency). The finding of a *TERT* variant prompted telomere length studies which were demonstrated to be <1st percentile (flow FISH). Additional testing by ddPCR identified a *TERT* promoter variant [NM_198253.2:c.-124C>T], which has been described in patients with a clinical diagnosis of a telomeropathy and germline *TERT/TERC* variants²⁷. There were no phenotypic features of dyskeratosis congenita in the patient. He subsequently underwent an allogeneic stem cell transplant from a sibling with documented normal telomere length by flow FISH.

Patient ID #96: A 34-year-old male was referred for pancytopenia noted during work up of liver lesions which were subsequently demonstrated to be hepatocellular carcinoma. He had a past history of mandibular squamous cell carcinoma at age 32 for which he had undergone surgery and radiotherapy. He had experienced significant radiation toxicity with residual scarring resulting in the need for ongoing feeding via percutaneous endoscopic gastrostomy tube. His family history was notable for his sister having been diagnosed with myelodysplastic syndrome in her 20s. BMF panel testing demonstrated two heterozygous *FANCA* missense variants [NM_000135.2:c.2852G>A; p.(Arg951Gln) and NM_000135.2:c.3971C>T; p.(Pro1324Leu)] both of which have been reported in multiple individuals with Fanconi anaemia in the compound heterozygous state²⁸⁻³². Peripheral blood chromosomal fragility studies using diepoxybutane demonstrated increased breakage. Hepatocellular carcinoma therapy was then tailored to avoid undue toxicity.

Patient ID #104: A 20-year-old female had been diagnosed with severe congenital neutropenia in infancy after presenting with culture negative febrile neutropenia. In addition she had significant cognitive impairment of unclear cause. She received life-long G-CSF therapy and experienced intermittent infections (predominantly skin). Her 15-year-old brother also experienced severe

congenital neutropenia requiring life-long G-CSF, significant cognitive impairment and hypertension. Her father had previously been diagnosed with cyclical neutropenia and also had some mild cognitive impairment. WES detected a heterozygous in-frame deletion in *SRP54* [NM_003136.3:c.349_351del; p.(Thr117del)]. The Thr117del is the most commonly described variant in *SRP54* in case series of severe congenital neutropenia to date and has been described as both a *de novo* and an inherited variant segregating with an autosomal dominant mode of inheritance^{9,10}. The *SRP54* Thr117del was subsequently detected in the patient's brother and father.

Patient ID #106: A 4-year-old female presented with a fluctuating mild anaemia since birth. Bone marrow biopsy was moderately hypocellular with mild dyserythropoiesis. An elevated red cell ADA was demonstrated. Her mother had been diagnosed with a transfusion-dependent macrocytic anaemia of unclear cause at age 13 and continued to receive regular red blood cell transfusions into adulthood. BMF panel testing on peripheral blood of the child demonstrated a heterozygous splice site variant in *RPS7* [NM_001011.3:c.75+1G>T; p.?]. The c.75+1G>T occurs at the canonical splice donor site on the exon 2/intron 2 boundary and is predicted to result in abnormal splicing by *in silico* predictors. This variant has not been reported in population databases (gnomAD), ClinVar, or the literature, however other *RPS7* splice site variants have been reported in patients with Diamond-Blackfan anaemia³³⁻³⁵. This variant was subsequently also detected in the peripheral blood of the child's mother.

Patient ID #107: An 18-year-old female had been diagnosed with severe congenital neutropenia shortly after birth. She had received life-long G-CSF therapy and suffered from intermittent skin and respiratory tract infections. She had been considered for allogeneic stem cell transplant, however neither a related nor unrelated donor could be identified. BMF panel testing demonstrated a heterozygous nonsense variant in *ELANE* [NM_001972.2:c.684C>A; p.(Tyr228*)]. In addition, a low level acquired variant was detected in *CSF3R* [NM_156039.3:c.2308C>T; p.(Gln770*)] at a variant allele frequency of 2.9%. The *ELANE* Tyr228* has previously been reported in patients with severe congenital neutropenia (including in association with myelodysplastic syndrome/acute myeloid leukaemia) and cyclical neutropenia^{36,37}.

Patient ID #118: A 21-year-old female was referred with fluctuating mild-moderate cytopenias and infections since the age of 15. Her family history was significant for a paternal aunt and uncle both

having died from acute myeloid leukaemia in young adulthood. Peripheral blood flow cytometry of lymphocyte subsets demonstrated B and NK cell cytopenias. Bone marrow aspirate and trephine was moderately hypocellular with erythroid hyperplasia, dyserythropoiesis and dysmegakaryopoiesis. Monosomy 7 was detectable by conventional cytogenetics. Targeted sequencing performed on bone marrow aspirate demonstrated an acquired pathogenic *SETBP1* variant [NM_015559.2:c.2602G>A; p.(Asp868Asn)] typically observed in myeloproliferative/myelodysplastic overlap entities³⁸⁻⁴⁰ but having also been seen in aAA⁴¹. BMF panel testing of peripheral blood demonstrated a heterozygous synonymous variant in *GATA2* [NM_032638.4:c.351C>G; p.(Thr117=)]. RNA studies have previously demonstrated that this variant results in the introduction of a cryptic splice donor site, leading to an aberrantly spliced transcript with a 136 bp internal deletion resulting in a frameshift and a truncated *GATA2* protein⁴². This variant has previously been reported in patients with clinical features of a *GATA2* haploinsufficiency syndrome, including in a mother and her three children who were all affected with *GATA2* haploinsufficiency syndrome-associated clinical features, and in an unrelated individual with immunodeficiency with no known family history⁴². The patient underwent a matched unrelated donor allogeneic stem cell transplant and the family has been referred for predictive testing.

Supplementary References

1. Richards S, Aziz N, Bale S, et al. Standards and guidelines for the interpretation of sequence variants: a joint consensus recommendation of the American College of Medical Genetics and Genomics and the Association for Molecular Pathology. *Genet Med*. 2015;17(5):405-423.
2. Markham JF, Yerneni S, Ryland GL, et al. CNspecter: a web-based tool for visualisation and clinical diagnosis of copy number variation from next generation sequencing. *Scientific reports*. 2019;9(1):6426.
3. Wong SQ, Raleigh JM, Callahan J, et al. Circulating Tumor DNA Analysis and Functional Imaging Provide Complementary Approaches for Comprehensive Disease Monitoring in Metastatic Melanoma. *JCO Precision Oncology*. 2017;1:1-14.
4. Draptchinskaia N, Gustavsson P, Andersson B, et al. The gene encoding ribosomal protein S19 is mutated in Diamond-Blackfan anaemia. *Nat Genet*. 1999;21(2):169-175.
5. Willig TN, Draptchinskaia N, Dianzani I, et al. Mutations in ribosomal protein S19 gene and diamond blackfan anemia: wide variations in phenotypic expression. *Blood*. 1999;94(12):4294-4306.
6. Campagnoli MF, Garelli E, Quarello P, et al. Molecular basis of Diamond-Blackfan anemia: new findings from the Italian registry and a review of the literature. *Haematologica*. 2004;89(4):480-489.
7. Pastor VB, Sahoo SS, Boklan J, et al. Constitutional SAMD9L mutations cause familial myelodysplastic syndrome and transient monosomy 7. *Haematologica*. 2018;103(3):427-437.
8. Farrar JE, Vlachos A, Atsidaftos E, et al. Ribosomal protein gene deletions in Diamond-Blackfan anemia. *Blood*. 2011;118(26):6943-6951.
9. Bellanne-Chantelot C, Schmaltz-Panneau B, Marty C, et al. Mutations in the SRP54 gene cause severe congenital neutropenia as well as Shwachman-Diamond-like syndrome. *Blood*. 2018;132(12):1318-1331.

10. Carapito R, Konantz M, Paillard C, et al. Mutations in signal recognition particle SRP54 cause syndromic neutropenia with Shwachman-Diamond-like features. *J Clin Invest*. 2017;127(11):4090-4103.
11. Vaz F, Hanenberg H, Schuster B, et al. Mutation of the RAD51C gene in a Fanconi anemia-like disorder. *Nature Genetics*. 2010;42(406).
12. Somyajit K, Saxena S, Babu S, Mishra A, Nagaraju G. Mammalian RAD51 paralogs protect nascent DNA at stalled forks and mediate replication restart. *Nucleic Acids Research*. 2015;43(20):9835-9855.
13. Somyajit K, Subramanya S, Nagaraju G. Distinct roles of FANCO/RAD51C protein in DNA damage signaling and repair: implications for Fanconi anemia and breast cancer susceptibility. *The Journal of biological chemistry*. 2012;287(5):3366-3380.
14. Tesi B, Davidsson J, Voss M, et al. Gain-of-function SAMD9L mutations cause a syndrome of cytopenia, immunodeficiency, MDS, and neurological symptoms. *Blood*. 2017;129(16):2266-2279.
15. Bogliolo M, Bluteau D, Lespinasse J, et al. Biallelic truncating FANCM mutations cause early-onset cancer but not Fanconi anemia. *Genetics In Medicine*. 2017;
16. Catucci I, Osorio A, Arver B, et al. Individuals with FANCM biallelic mutations do not develop Fanconi anemia, but show risk for breast cancer, chemotherapy toxicity and may display chromosome fragility. *Genetics In Medicine*. 2017;
17. Cronkhite JT, Xing C, Raghu G, et al. Telomere shortening in familial and sporadic pulmonary fibrosis. *Am J Respir Crit Care Med*. 2008;178(7):729-737.
18. Hoffman H, Rice C, Skordalakes E. Structural Analysis Reveals the Deleterious Effects of Telomerase Mutations in Bone Marrow Failure Syndromes. *The Journal of biological chemistry*. 2017;292(11):4593-4601.
19. Sandin S, Rhodes D. Telomerase structure. *Curr Opin Struct Biol*. 2014;25(104-110).
20. Vulliamy T, Beswick R, Kirwan MJ, Hossain U, Walne AJ, Dokal I. Telomere length measurement can distinguish pathogenic from non-pathogenic variants in the shelterin component, TIN2. *Clinical Genetics*. 2012;81(1):76-81.
21. Walne AJ, Vulliamy T, Beswick R, Kirwan M, Dokal I. TIN2 mutations result in very short telomeres: analysis of a large cohort of patients with dyskeratosis congenita and related bone marrow failure syndromes. *Blood*. 2008;112(9):3594-3600.
22. Lewinsohn M, Brown AL, Weinel LM, et al. Novel germ line DDX41 mutations define families with a lower age of MDS/AML onset and lymphoid malignancies. *Blood*. 2016;127(8):1017-1023.
23. Sebert M, Passet M, Rimbault A, et al. Clinical and Molecular Characteristics of DDX41-Mutated Patients in a Large Cohort of Sporadic MDS/AML. *Blood*. 2018;132(Suppl 1):797.
24. Ameziane N, Sie D, Dentro S, et al. Diagnosis of fanconi anemia: mutation analysis by next-generation sequencing. *Anemia*. 2012;2012(132856).
25. Savage SA, Ballew BJ, Giri N, et al. Novel FANCI mutations in Fanconi anemia with VACTERL association. *Am J Med Genet A*. 2016;170A(2):386-391.
26. Mantere T, Haanpaa M, Hanenberg H, et al. Finnish Fanconi anemia mutations and hereditary predisposition to breast and prostate cancer. *Clin Genet*. 2015;88(1):68-73.
27. Gutierrez-Rodrigues F, Donaires FS, Pinto A, et al. Pathogenic TERT promoter variants in telomere diseases. *Genetics in Medicine*. 2018;
28. Ameziane N, Errami A, Leveille F, et al. Genetic subtyping of Fanconi anemia by comprehensive mutation screening. *Human mutation*. 2008;29(1):159-166.
29. Gille JJ, Floor K, Kerkhoven L, Ameziane N, Joenje H, de Winter JP. Diagnosis of Fanconi Anemia: Mutation Analysis by Multiplex Ligation-Dependent Probe Amplification and PCR-Based Sanger Sequencing. *Anemia*. 2012;2012(603253).
30. Bottega R, Nicchia E, Cappelli E, et al. Hypomorphic FANCA mutations correlate with mild mitochondrial and clinical phenotype in Fanconi anemia. *Haematologica*. 2018;103(3):417-426.
31. Morgan NV, Tipping AJ, Joenje H, Mathew CG. High frequency of large intragenic deletions in the Fanconi anemia group A gene. *Am J Hum Genet*. 1999;65(5):1330-1341.

32. Zheng Z, Geng J, Yao RE, et al. Molecular defects identified by whole exome sequencing in a child with Fanconi anemia. *Gene*. 2013;530(2):295-300.
33. Gazda HT, Sheen MR, Vlachos A, et al. Ribosomal protein L5 and L11 mutations are associated with cleft palate and abnormal thumbs in Diamond-Blackfan anemia patients. *Am J Hum Genet*. 2008;83(6):769-780.
34. Gerrard G, Valganon M, Foong HE, et al. Target enrichment and high-throughput sequencing of 80 ribosomal protein genes to identify mutations associated with Diamond-Blackfan anaemia. *British journal of haematology*. 2013;162(4):530-536.
35. Ichimura T, Yoshida K, Okuno Y, et al. Diagnostic challenge of Diamond-Blackfan anemia in mothers and children by whole-exome sequencing. *Int J Hematol*. 2017;105(4):515-520.
36. Dale DC, Person RE, Bolyard AA, et al. Mutations in the gene encoding neutrophil elastase in congenital and cyclic neutropenia. *Blood*. 2000;96(7):2317-2322.
37. Makaryan V, Zeidler C, Bolyard AA, et al. The diversity of mutations and clinical outcomes for ELANE-associated neutropenia. *Current opinion in hematology*. 2015;22(1):3-11.
38. Piazza R, Valletta S, Winkelmann N, et al. Recurrent SETBP1 mutations in atypical chronic myeloid leukemia. *Nat Genet*. 2013;45(1):18-24.
39. Elena C, Galli A, Such E, et al. Integrating clinical features and genetic lesions in the risk assessment of patients with chronic myelomonocytic leukemia. *Blood*. 2016;
40. Makishima H, Yoshida K, Nguyen N, et al. Somatic SETBP1 mutations in myeloid malignancies. *Nat Genet*. 2013;45(8):942-946.
41. Heuser M, Schlarmann C, Dobbernack V, et al. Genetic characterization of acquired aplastic anemia by targeted sequencing. *Haematologica*. 2014;99(9):e165-167.
42. Wehr C, Grotius K, Casadei S, et al. A novel disease-causing synonymous exonic mutation in GATA2 affecting RNA splicing. *Blood*. 2018;