



*Advances in Basic, Laboratory and Clinical Aspects of Thromboembolic Diseases**

THE UTILITY AND COST-EFFECTIVENESS OF D-DIMER MEASUREMENTS IN THE DIAGNOSIS OF DEEP VEIN THROMBOSIS

LUCIANO CRIPPA, SILVANA VIGANÒ D'ANGELO, LOREDANA TOMASSINI, BARBARA RIZZI,

GABRIELLA D'ALESSANDRO, ARMANDO D'ANGELO

Coagulation Service, Scientific Institute H San Raffaele, Milan, Italy

ABSTRACT

Background and Objective. The potential utility of D-dimer measurements for the diagnosis of deep vein thrombosis became evident soon after the development of reliable commercial assays. The purpose of this review is to outline some critical aspects affecting cost-effectiveness of D-dimer measurements in the diagnosis of deep vein thrombosis (DVT).

Methods. The authors have been working in this field contributing original papers whose data have been used for this study. In addition, the material analyzed in this article includes papers published in the journals covered by the Science Citation Index® and Medline®.

Results. D-dimer levels are very sensitive to the process of fibrin formation/dissolution occurring with ongoing thrombosis. However, they may not be highly specific for venous thromboembolism as they are influenced by the presence of comorbid conditions potentially elevating plasma D-dimer (cancer, surgery, infectious diseases). In addition, commercially available ELISA assays, although quantitative and reproducible, cannot be used under emergency conditions because they are time-consuming and suited for batch-processing of plasma samples. Recently, new assays have been introduced which permit fast and quantitative D-dimer estimations in individual patients. We have evaluated the utility of two new rapid assays (LPIA D-dimer, Mitsubishi, and VIDAS D-DIMER, bioMerieux) in combination with compression real-time-B-mode ultrasonography for the detection of deep vein thrombosis in asymptomatic patients following elective hip

replacement and in patients with clinically suspected deep vein thrombosis. In both settings, we identified cut-off values with optimal sensitivity which allow exclusion of deep vein thrombosis in a considerable percentage of patients, with substantial sparing of economic resources. In fact, based on a cost-effectiveness analysis, a diagnostic algorithm combining D-dimers measurement and compression ultrasonography would result in cost-savings ranging from 5% to 55% in patients with high or low clinical pre-test probability respectively. However, the specificity of D-dimer measurements for deep vein thrombosis was much higher in symptomatic than in asymptomatic patients. Choice of the cut-off value proved to be dependent on the method as well as on the patient populations studied.

Conclusions. The cost-effectiveness of D-dimers measurement in the diagnosis of asymptomatic DVT remains questionable. Conversely, our data strongly support the utility of D-dimers determinations in the diagnosis of symptomatic DVT. In terms of sparing economic resources, the introduction in the clinical laboratory of the rapid quantitative assays would be highly convenient, because they avoid a source of bias in the interpretation of D-dimers results, are easy to perform and do not require dedicated personnel or instrumentation. Prospective management studies validating the utility of D-dimer measurement in the diagnosis of deep vein thrombosis are urgently needed.

©1997, Ferrata Storti Foundation

Key words: D-dimer, deep vein thrombosis

D-dimer is a specific degradation product resulting from the digestion of cross-linked fibrin by plasmin. It is composed of two identical subunits deriving from two fibrinogen molecules. High D-dimer levels are to be expected in the presence of increased fibrin formation and of an efficient fibrinolytic system. Thus, with only few

exceptions,¹ D-dimer should be considered a marker of intra- or extravascular fibrin formation rather than fibrinolysis. Soon after the introduction of the very first assay suitable for its measurement, the potential utility of D-dimer as a laboratory tool in the diagnosis of thromboembolic disease became evident.²⁻¹⁸ The purpose of this review is to outline

Correspondence: Armando D'Angelo, M.D., Coagulation Service, Istituto Scientifico H S. Raffaele, via Olgettina 60, 20132, Milano, Italy. Tel. international +39.2.26432228. Fax. international +39.2.26432640.

Acknowledgements: the financial support of Telethon - Italy (Grant no. E.C472.) is gratefully acknowledged.

*This paper was presented at the Second International Winter Meeting on Basic, Laboratory and Clinical Aspects of Thromboembolic Diseases, held in La Thuile, Italy, on March 17-23, 1996. The Meeting organizers (A. D'Angelo, A. Girolami & F. Piovella) have acted as Guest Editors and assumed the responsibility for peer review of this manuscript.

Received April 16, 1997; accepted May 26, 1997.

some critical aspects affecting the cost-effectiveness of D-dimer measurements in the diagnosis of deep vein thrombosis (DVT).

D-dimer or D-dimers?

D-dimer is the final proteolytic split product formed by the action of plasmin on cross-linked fibrin in the presence of calcium. The D-dimer exposes neoantigens not present in the parent fibrinogen molecule. However, the D-dimer configuration carrying the same neoantigens also occurs in a number of intermediate, soluble, fibrin split products.^{19,20} Thus, at least in theory, the term “D-dimers” should be preferable. This distinction also has a practical implication in D-dimers testing. The measurement of D-dimer using antibodies directed against the neoantigens involves measuring a broad range of molecules derived from cross-linked fibrin. Reactivity towards the various fragments varies with the monoclonal antibody used and this accounts for the difficulties encountered in the standardization of D-dimer assays. Indeed the purified D-dimer preparations used for internal calibration are *qualitatively* different from the D-dimers moieties detected in circulating plasma. This is most probably the basis for the different absolute D-dimer values observed in a normal population tested with different commercial kits (Table 1).

The potential utility of D-dimers measurement in the diagnosis of symptomatic deep vein thrombosis

The clinical diagnosis of DVT is erroneous in about half of symptomatic patients. Recently, a detailed questionnaire has been proposed to quantitate the clinical probability of thrombosis before diagnostic testing (pretest probability).²¹ Although a good relationship was observed between the clinical pretest probability (low, moderate, high) for

DVT and the prevalence of the disease as proved by venography, this approach can hardly be used widely in clinical practice.

Venography is considered the only proven accurate method for the diagnosis of all deep vein thromboses. It carries, however, major limitations which hamper its use for screening purposes in high-risk patients. The technique is invasive, requires experienced personnel and dedicated instrumentation, and involves a definite - albeit minimal - risk to patients. As a result, many non-invasive techniques have been proposed to replace venography.²⁴ Compression ultrasonography,^{25,26} impedance plethysmography²⁷ and doppler ultrasonography,^{26,28} have been evaluated for their accuracy in the diagnosis of symptomatic DVT. Of the above techniques, only compression ultrasonography has achieved a large consensus and clinical validation.²⁵ However, like the other non-invasive methods, compression ultrasonography shows relatively low sensitivity to distal vein thrombosis because of the poorly visible compressibility of the calf veins. Thus, serial testing over a 7-day period is considered mandatory for patients with a suspected DVT who initially present normal compression ultrasonography (Figure 1). This procedure is, however, time-consuming and expensive. Moreover, a significant proportion of outpatients may be lost at follow-up.

In this setting, the contribution of D-dimer mea-

Table 1. D-dimer levels (µg/mL) in 24 healthy subjects as measured with 4 different commercial kits.

Assay	Mean ± S.D.	Median	95% confidence limits of the distribution
LPIA D-Dimer (Mitsubishi)	0.33±0.16	0.29	0.0-0.67
FDP-Slidex (bioMerieux)	<0.25	<0.25	<0.25
Fibrinostika FbDP (Organon Teknika)	0.22±0.06	0.22	0.09-0.36
Fibrinostika TDP (Organon Teknika)	0.64±0.16	0.61	0.31-0.98

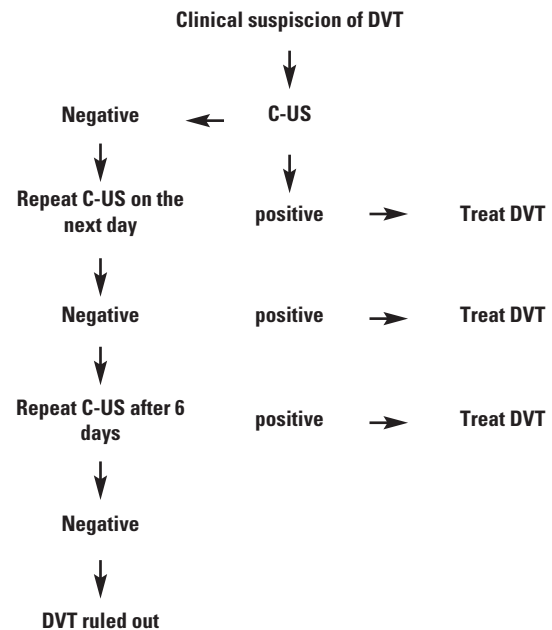


Figure 1. Algorithm for the diagnosis of symptomatic deep vein thrombosis by compression ultrasonography (C-US).

many ways. First, it might be used in combination with compression ultrasonography or other non-invasive techniques to identify patients with DVT despite an initially negative examination. Such an approach would allow definitive diagnosis concerning the presence or absence of DVT on the day of presentation in 42% of patients versus 19% of patients who would have been diagnosed with compression ultrasonography alone¹³ and it would significantly reduce diagnostic errors when using only strain-gauge plethysmography.¹⁶ D-dimers, combined with the use of the clinical model could be useful for excluding a diagnosis of DVT; alternatively, D-dimer determination could replace the clinical model in the evaluation of the clinical pretest probability of DVT. Moreover, should D-dimer testing be rapidly performed in individual patients and its negative predictive value approach 100% with satisfactory specificity at the corresponding cut-off value, this might eliminate the need for instrumental diagnosis of DVT in a considerable percentage of in- and outpatients, with a substantial savings of economic resources. Last but not least, measurement of D-dimer levels may be useful in the identification of DVT recurrence,²⁹ which is often a true challenge to the clinician.²⁴ However, it must be pointed out that D-dimer testing is potentially useful in clinical practice only if properly carried out and interpreted.

D-dimer assays and their accuracy in the diagnosis of DVT

Commercially available D-dimer assays include both semiquantitative and quantitative methods. Latex agglutination techniques or ELISAs based on color development when plasma D-dimers exceed a previously established cut-off value are popular semi-quantitative assays. Quantitative assays are mainly based on ELISA technique. All methods of D-dimer testing have been evaluated in a number of published papers and their accuracy in the diagnosis of DVT is now well established. It is generally accepted that low D-dimer levels can be used to exclude the presence of DVT in clinically suspect

patients. A comprehensive review of 1994³⁰ reports sensitivity and specificity of, respectively, 97% and 35% for quantitative and 83% and 68% for semi-quantitative tests (Table 2).

To avoid misdiagnosing DVT, the D-dimer assay should have a negative predictive value of virtually 100%. This can be achieved only by using the quantitative methods which, on the other hand, are time-consuming and unsuitable for emergency purposes.³⁰ During the last 3 years, new rapid quantitative methods have been introduced that are suitable for individual plasma D-dimer measurement. These techniques have advanced the use of D-dimers as a diagnostic tool in the clinical field. Recently, we evaluated a latex immunophotometric assay (LPIA D-dimer) and a fluorescence-based immunoassay (VIDAS D-dimer). Both assays proved to be rapid (turnaround time: 20-30 minutes) and suitable for clinical testing. Table 3 reports the accuracy in the diagnosis of symptomatic DVT of the novel rapid methods for D-dimer measurement.

Factors influencing the cost-effectiveness of plasma D-dimer measurement in the diagnosis of deep vein thrombosis in symptomatic patients

In addition to the negative predictive value, the cost-effectiveness of D-dimer measurement in the diagnosis of symptomatic DVT relies on its positive predictive value, which reflects the specificity of the assay and must also be high to allow significant cost savings. Only under these conditions is it possible to avoid further diagnostic procedures (invasive or non-invasive) in patients with suspected DVT and a negative D-dimer value.

The accuracy of the assay depends on both its sensitivity and specificity for DVT and is influenced by many factors which must be considered in a cost-effectiveness analysis. A first variable is represented by the instrumental diagnosis used to confirm or exclude the presence of DVT. Since non-invasive methods have a low sensitivity to distal DVT, the specificity and positive predictive value of D-dimer levels will be higher when venography is

Table 2. Accuracy of D-dimer latex agglutination and ELISA methods in symptomatic deep vein thrombosis diagnosed by venography or non-invasive methods (modified from ref. #30).

<i>Instrumental diagnosis of DVT</i>	<i>D-dimer method</i>	<i>Cut-off value (µg/mL)</i>	<i>n</i>	<i>Sensitivity</i>	<i>Specificity</i>	<i>Positive predictive value</i>	<i>Negative predictive value</i>
Venography	Latex agglutination	0.4-0.5	251	74%	70%	65%	78%
Non-invasive	Latex agglutination		482	89%	67%	57%	92%
Venography	ELISA	0.4-0.5	541	97%	47%	58%	96%
Non-invasive	ELISA		796	97%	29%	36%	95%

Table 3. Accuracy of rapid D-dimer assay methods in the diagnosis of symptomatic deep vein thrombosis.

Instrumental diagnosis of DVT	D-dimer method	Cut-off value (µg/mL)	n	Sensitivity	Specificity	Positive predictive value	Negative predictive value
Venography	Nycocard D-dimer*	0.5	92	95%	25%	52%	87%
Venography	SimpliRED ^o	0.2	214	89%	77%	56%	95%
Non-invasive	SimpliRED ^f	0.2	86	94%	61%	77%	88%
Non-invasive	LPIA D-dimer ^g	2.3	103	100%	79%	56%	100%
Non-invasive	VIDAS D-dimer ^h	1.0	99	100%	75%	49%	100%

* Nycomed Pharma, ref. #33; ^oAgen, ref. #34; ^fAgen, ref. #35; ^gMitsubishi, ref. #31; ^hbioMerieux, ref. #32.

employed as a confirmatory test (Tables 2 and 3). Due to the inverse relationship between sensitivity and specificity,³³ an increase in the specificity of the assay is associated with a decrease in sensitivity. If this is not the case, as reported in Tables 2 and 3, the cut-off values chosen to exclude the presence of DVT are most probably incorrect.

Cut-off values are strictly method dependent. When using semi-quantitative methods, the correct choice of the cut-off value is hampered by the intrinsic characteristic of the assay for which results are substantially expressed as positive or negative. For quantitative methods, exclusion of DVT diagnosis as based on the observation of D-dimers levels within the normal range would negatively affect the specificity – and hence cost-effectiveness – of the test. Rather, optimal cut-off values should be determined by receiver operator characteristics (ROC) curve analysis, which basically describes the relationship between true positive and false positive decisions.³⁶ The cut-off value chosen must have a negative predictive value virtually identical to 100%, and it should be high enough to allow satisfactory specificity for DVT. Not surprisingly, cut-off values are largely dependent on the characteristics of the patient populations evaluated. Because D-dimers are elevated by inflammatory diseases and cancer,³² the prevalence of such comorbid conditions in the patient population tested to determine the cut-off level might influence the predictive value of the assay. These levels are also influenced by the average time elapsed between onset of symptoms and clinical observation of the patients. As shown in Figure 2, DVT related D-dimers levels are lower in patients with symptoms lasting for over one week and may even be normal 11 or more days after the onset of symptoms.³² This implies that optimal cut-off values are useful for excluding thrombosis only within a certain number of days from the onset of symptoms.³² Last but not least, the cost-effectiveness of clinical D-dimer testing also depends on the actual prevalence of deep vein thrombosis in the patient population. The potential for avoiding instrumental diagnosis in all patients with plasma

D-dimer levels below the cut-off will lead to a substantial sparing of economic resources only if the prevalence of the disease is relatively low.

Based on our cost-effectiveness analysis, a diagnostic algorithm combining D-dimer measurement and compression ultrasonography (Figure 3) would result in cost-savings ranging from 5% to 55% in patients with high or low clinical pre-test probability, respectively.³²

Measurement of D-dimers may be extremely useful in the diagnosis of recurrent DVT. As already remarked, D-dimer levels show a decrease over time following the thrombotic event and they normalize within 15-20 days of the onset of symptoms.^{29,37} Irrespective of anticoagulant treatment, an increase in D-dimer levels is always associated with DVT recurrence.³² The diagnosis of DVT recurrence is very difficult and expensive in the absence of a prior instrumental diagnosis. In our hands, the measurement of D-dimers may allow up to a 77% cost-savings in patients with suspected DVT recurrence.³²

Accuracy of D-dimers in the diagnosis of

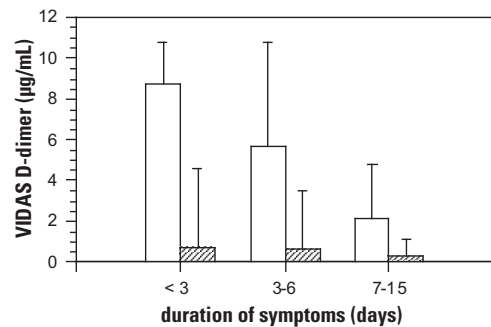


Figure 2. Relationship of plasma D-Dimer levels (VIDAS D-Dimer, median and highest values) with the duration of symptoms in patients with (open bars) and without DVT (hatched bars) as diagnosed by compression ultrasonography (from ref. #32).

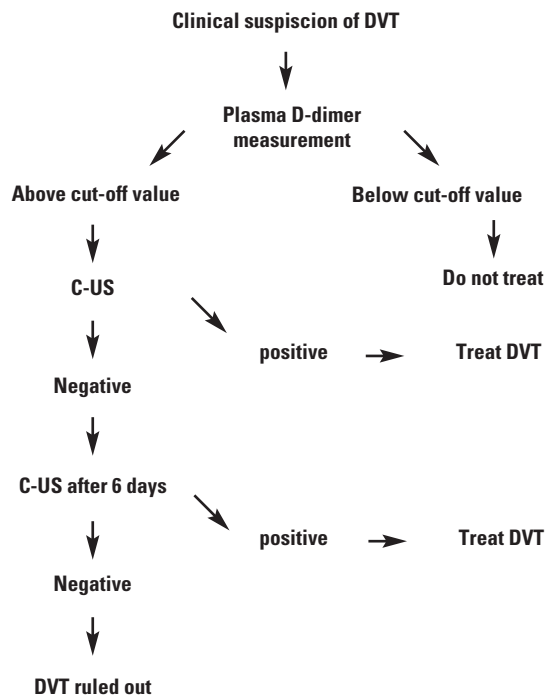


Figure 3. Potential contribution of plasma D-Dimer measurements in the diagnostic algorithm of symptomatic deep vein thrombosis.

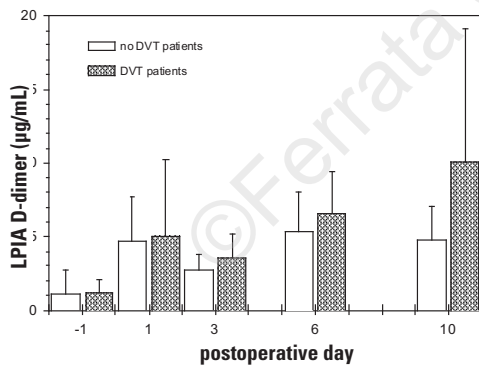


Figure 2. Changes in plasma D-Dimer levels (LPIA D-dimer, mean \pm S.D.) in patients submitted to elective hip replacement who had bilateral ascending venography performed on postoperative day 10 (from ref. #49). Only on postoperative day 10 were D-dimer levels significantly higher ($p < 0.01$) in patients with DVT than in those without DVT.

pulmonary embolism as frequently as occlusive ones. Asymptomatic DVT has a high prevalence in patients submitted to neurosurgery and to orthopedic or urologic surgery.

Non-invasive methods for the detection of DVT have demonstrated unsatisfactory sensitivity to asymptomatic DVT.³⁸⁻⁴³ On the other hand, venography can hardly be proposed for routine surveillance of all patients submitted to high-risk surgery. Under these circumstances, D-dimer measurement could be useful for identifying those patients requiring further invasive (venography) or non-invasive (serial compression ultrasonography) procedures.⁴⁴⁻⁴⁸ In establishing the proper D-dimer cut-off value, surgery-dependent elevations of D-dimer levels must be taken into account (Figure 4). We have identified a reasonably useful cut-off value for D-dimers only on the 10th postoperative day in patients submitted to prosthetic hip replacement.⁴⁹ Compression ultrasonography could thus be limited to patients with D-dimer values above the cut-off and secondary prophylaxis should be started only in patients with proven DVT. It should be kept in mind, however, that the optimal cut-off value may change over time with the introduction of new surgical procedures and/or new thromboprophylactic drugs.^{50,51} Thus, updating of the cut-off value is mandatory from time to time.

Conclusions

The cost-effectiveness of D-dimer measurement in the diagnosis of asymptomatic DVT remains questionable. Conversely, our data strongly support the utility of D-dimer determinations in the diagnosis of symptomatic DVT. In terms of savings money, the introduction into the clinical laboratory of rapid quantitative assays would be extremely useful because they avoid a source of bias in the interpretation of D-dimer results, are easy to perform and do not require dedicated personnel or instrumentation. Although the preliminary data are promising, the algorithm presented in Figure 3 needs to be validated by prospective management studies investigating the safety of withholding non-invasive or invasive diagnostic procedures from patients with suspected DVT and a negative D-dimer test.

References

- Bandello F, Viganò D'Angelo S, et al. High factor VII activity and lipoprotein(a) levels in central retinal vein occlusion. *Thromb Haemost* 1994; 72:39-44.
- Heaton DC, Billings JD, Hickton CM. Assessment of D dimer assays for the diagnosis of deep vein thrombosis. *J Lab Clin Med* 1987; 110:588-91.
- Rowbotham BJ, Carroll P, Whitaker AN, et al. Measurement of crosslinked fibrin derivatives - use in the diagnosis of venous thrombosis. *Thromb Haemost* 1987; 57:59-61.
- Ott P, Astrup L, Jensen RH, Nyeland B, Pederson B. Assessment of D-dimer in plasma: diagnostic value in suspected deep venous thrombosis of the leg. *Acta Med Scand* 1988; 224:263-7.
- Bounameaux H, Schneider PA, Reber G, de Moerloose Ph, Krahenbuhl B. Measurement of plasma D-dimer for diagnosis of deep venous thrombosis. *Am J Clin Pathol* 1989; 91:82-5.
- van Bergen PFMM, Knot EAR, Jonker JJC, de Boer AC, de Maat MPM. Is quantitative determination of fibrin(ogen) degradation products and thrombin-antithrombin III complexes useful to diagnose deep venous thrombosis in outpatients? *Thromb Haemost*

- 1989; 62:1043-5.
7. Chapman CS, Akhtar N, Campbell S, Miles K, O'Connor J, Mitchell VE. The use of D-dimer assay by enzyme immunoassay and latex agglutination techniques in the diagnosis of deep vein thrombosis. *Clin Lab Haematol* 1990; 12:37-42.
 8. Elias A, Aillaud MF, Roul C, Villain Ph, Serradimigni A, Juhan-Vague I. Assessment of D-dimer measurement by ELISA or latex methods in deep vein thrombosis diagnosed by ultrasonic duplex scanning. *Fibrinolysis* 1990; 4:237-40.
 9. Boneu B, Bes G, Pelzer H, Sie P, Boccalon H. D-dimers, thrombin-antithrombin III complexes and prothrombin fragments 1+2: diagnostic value in clinically suspected deep vein thrombosis. *Thromb Haemost* 1991; 65:28-32.
 10. Chang-Liem GS, Lustermsans FAT, van Wersch JWJ. Comparison of the appropriateness of the latex and ELISA D-dimer determination for the diagnosis of deep venous thrombosis. *Haemostasis* 1991; 21:106-10.
 11. de Boer WA, de Haan MA, Huisman JW, Klaassen CHL. D-dimer latex assay as screening method in suspected deep venous thrombosis of the leg. A clinical study and review of the literature. *Neth J Med* 1991; 38:65-9.
 12. Grau E, Linares M, Estany A, Martin F. Utility of D-dimer in the diagnosis of deep vein thrombosis in outpatients. *Thromb Haemost* 1991; 66:510.
 13. Heijboer H, Ginsberg JS, Büller HR, Lensing AWA, Colly LP, ten Cate JW. The use of the D-dimer test in combination with non-invasive testing versus serial non-invasive testing alone for the diagnosis of deep vein thrombosis. *Thromb Haemost* 1992; 67:510-3.
 14. Carter CJ, Doyle DL, Dawson N, Fowler S, Devine DV. Investigations into the clinical utility of latex D-dimer in the diagnosis of deep venous thrombosis. *Thromb Haemost* 1993; 69:8-11.
 15. Raimondi P, Bongard O, de Moerloose P, Reber G, Waldvogel F, Bounameaux H. D-dimer plasma concentration in various clinical conditions: implication for the use of this test in the diagnostic approach for venous thromboembolism. *Thromb Res* 1993; 69:125-30.
 16. Pini M, Quintavalla R, Pattacini C, et al. Combined use of strain-gauge plethysmography and latex D-dimer test in clinically suspected deep venous thrombosis. *Fibrinolysis* 1993; 7:391-6.
 17. Shaikat N, Rowlands DJ, Cotter L, Walker MG, Douglas JT. The specificity and sensitivity of various ELISA methods for fibrin degradation products in the diagnosis of arterial and venous thrombosis. *Thromb Haemost* 1993; 69:839.
 18. Bouman CSC, Ypma ST, Sybesma JPHB. Comparison of the efficacy of D-dimer, fibrin degradation products and prothrombin fragment 1+2 in clinically suspected deep venous thrombosis. *Thromb Res* 1995; 77:225-34.
 19. Plow EF, Hougie C, Edgington TS. Neoantigenic expressions engendered by plasmin cleavage of fibrinogen. *J Immunol* 1971; 107:1496-500.
 20. Plow EF, Edgington TS. Discriminating neoantigenic differences between fibrinogen and fibrin derivatives. *Proc Natl Acad Sci USA* 1973; 70:1169-73.
 21. Wells PS, Hirsh J, Anderson DR, et al. Accuracy of clinical assessment of deep-vein thrombosis. *Lancet* 1995; 345:1326-30.
 22. Bettman MA, Robbins A, Braun SD, Wetzner S, Dunnick NR, Finkelstein J. Contrast venography of the leg: diagnostic efficacy, tolerance and complication rates with ionic and non-ionic contrast media. *Radiology* 1987; 165:113-6.
 23. Lensing AWA, Prandoni P, Buller HR, Cogo A, Casara D, ten Cate JW. Lower extremity venography with iohexol: results and complications. *Radiology* 1990; 77:503-5.
 24. Büller HR, Lensing AWA, Hirsh J, ten Cate JW. Deep vein thrombosis: new non-invasive diagnostic tests. *Thromb Haemost* 1991; 66:133-7.
 25. Lensing AWA, Prandoni P, Brandjes D, et al. Detection of deep-vein thrombosis by real-time b-mode ultrasonography. *N Engl J Med* 1989; 320:342-5.
 26. Cogo A, Lensing AWA, Prandoni P, Büller HA, Girolami A, ten Cate JW. Comparison of real-time B-mode ultrasonography and doppler ultrasound with contrast venography in the diagnosis of venous thrombosis in symptomatic outpatients. *Thromb Haemost* 1993; 70:404-7.
 27. Hull RD, van Aken WG, Hirsh J, et al. Impedance plethysmography using the occlusive cuff technique in the diagnosis of venous thrombosis. *Circulation* 1976; 53:696-700.
 28. Lensing AWA, Levi MM, Büller H, et al. Diagnosis of deep-vein thrombosis using an objective doppler method. *Ann Intern Med* 1990; 113:9-13.
 29. Sie P. The value of laboratory tests in the diagnosis of venous thromboembolism. *Haematologica* 1995; 80(Suppl):57-60.
 30. Bounameaux H, de Moerloose P, Perrier A, Reber G. Plasma measurement of D-dimer as diagnostic aid in suspected venous thromboembolism: an overview. *Thromb Haemost* 1994; 71:1-6.
 31. Milani E, Safa O, Mazzola G, Garlando A, Pattarini E, D'Angelo A. Turbidimetric quantitative determination of plasma D-dimer: comparison with ELISA and qualitative methods [abstract]. First International Winter Meeting on Coagulation - Basic, Laboratory and Clinical Aspects of Venous Thromboembolism. March 9-12, 1994, Cortina D'Ampezzo, Italy. Abstract Book, p 49.
 32. D'Angelo A, D'Alessandro G, Tomassini L, Pittet JL, Dupuy G, Crippa L. Evaluation of a new rapid quantitative D-dimer assay in patients with clinically suspected deep vein thrombosis. *Thromb Haemost* 1996; 75:412-6.
 33. Dale S, Gogstad GO, Brosstad F, et al. Comparison of three D-dimer assays for the diagnosis of DVT: ELISA, Latex and an immunofiltration assay (NycoCard D-dimer). *Thromb Haemost* 1994; 71:270-4.
 34. Wells PS, Brilledwards P, Stevens P, et al. A novel and rapid whole-blood assay for D-dimer in patients with clinically suspected deep vein thrombosis. *Circulation* 1995; 91:2184-7.
 35. Brenner B, Pery M, Lanir N, et al. Application of a bedside whole blood D-dimer assay in the diagnosis of deep vein thrombosis. *Blood Coag Fibrinol* 1995; 6:219-22.
 36. Metz CE. Basic principles of ROC analysis. *Semin Nucl Med* 1978; 8:283-98.
 37. The DVTENOX Study Group. Markers of hemostatic system activation in acute deep venous thrombosis. Evolution during the first days of heparin treatment. *Thromb Haemost* 1993; 70:909-14.
 38. Agnelli G, Volpato R, Radicchia S, et al. Detection of asymptomatic deep vein thrombosis by real-time B-mode ultrasonography in hip surgery patients. *Thromb Haemost* 1992; 68:257-60.
 39. Borris LC, Christiansen HM, Lassen MR, Olsen AD, Schott P. Comparison of real-time B-mode ultrasonography and bilateral ascending phlebography for detection of postoperative deep vein thrombosis following elective hip surgery. *Thromb Haemost* 1989; 61:363-5.
 40. Woolson ST, Mc Crory DW, Walter JF, Maloney WJ, Watt JM, Cahill PD. B-Mode ultrasound scanning in the detection of proximal venous thrombosis after total hip replacement. *J Bone Joint Surg* 1990; 72A:983-7.
 41. Jongbloets LMM, Lensing AWA, Koopman MW, Büller HR, ten Cate JW. Comparison of real-time B-mode ultrasonography and doppler ultrasound for the detection of symptomless postoperative deep vein thrombosis. *Lancet* 1994; 343:1142-4.
 42. Harris WH, Athansoulis C, Waltman AC, Salzman EW. Cuff impedance plethysmography and ¹²⁵I-fibrinogen leg scanning versus roentgenographic phlebography for diagnosis of thrombophlebitis following hip surgery. *J Bone Joint Surg* 1976; 58:939-44.
 43. Cruickshank MK, Levine MN, Hirsh J, et al. An evaluation of impedance plethysmography and ¹²⁵I-fibrinogen leg scanning in patients following hip surgery. *Thromb Haemost* 1989; 62:830-4.
 44. Kroneman R, Nieuwenhuizen W, Knot EAR. Monoclonal antibody-based plasma assays for fibrinogen and derivatives, and their clinical relevance. *Blood Coag Fibrinol* 1990; 1:91-111.
 45. Jørgensen LN, Lind B, Hauch O, Leffers A, Albrecht-Beste E, Konradsen LAG. Thrombin-antithrombin III-complex and fibrin degradation products in plasma: surgery and postoperative deep vein thrombosis. *Thromb Res* 1990; 59:69-76.
 46. Bounameaux H, Khabiri E, Huber O, et al. Value of liquid crystal contact thermography and plasma level of D-dimer for screening of deep venous thrombosis following general abdominal surgery. *Thromb Haemost* 1992; 67:603-6.
 47. Rowbotham BJ, Whitaker AN, Harrison J, Murtaugh P, Reasbeck I, Bowie EJW. Measurement of crosslinked fibrin derivatives in patients undergoing abdominal surgery: use in the diagnosis of postoperative venous thrombosis. *Blood Coag Fibrinol* 1992; 3:25-31.
 48. Dunn ID, Hui ACW, Triffit PD, et al. Plasma D-dimer as a marker of postoperative deep venous thrombosis. *Thromb Haemost* 1994; 72:663-5.
 49. Crippa L, Ravasi F, Viganò D'Angelo S, et al. Diagnostic value of compression ultrasonography and fibrinogen-related parameters in the detection of postoperative deep vein thrombosis following elective hip replacement: a pilot study. *Thromb Haemost*, 1995; 74:1235-9.
 50. Pini M. Prophylaxis of venous thromboembolism: the old and the new. *Haematologica* 1995; 80(suppl to no. 2):66-77.
 51. D'Angelo A, Crippa L, Agazzi A, et al. Oral anticoagulants: old drugs with a promising future. *Haematologica* 1995; 80(suppl to no 2):92-101.