

Characterization of response and corneal events with extended follow-up after belantamab mafodotin (GSK2857916) monotherapy for patients with relapsed multiple myeloma: a case series from the first-time-in-human clinical trial

Multiple myeloma (MM) remains an incurable haematological malignancy typically characterised by multiple relapses requiring ongoing sequential therapy.¹ This treatment paradigm is being challenged by novel immunotherapies that may be able to induce deeper and more durable responses than conventional treatments.² Belantamab Mafodotin (belamaf, GSK2857916) is a humanized, afucosylated monoclonal anti-BCMA antibody conjugated to monomethyl auristatin-F (MMAF, a microtubule-disrupting agent) which demonstrated an overall response rate of 60% and a median progression-free survival (PFS) of 12.0 months (95% CI: 3.1–not reached [NR]) in a first-in-human clinical trial in relapsed MM (BMA117159; NCT02064387).^{3,4} In this study a maximum of 16 doses could be given, three weeks apart. The most significant events leading to dose reductions were blurred vision (12 of 35; 34%) and thrombocytopenia (6 of 35; 17%), with corneal events reported in 24 (69%) patients. All patients received prophylactic steroid eye drops four-times a day for four days commencing 24 hours pre-belamaf and fluorescein sodium 2% dye staining was performed at slit lamp examination. Within the context of the trial, greater characterisation of disease response and corneal events, including their management, is not available. We therefore report our experience following a median of 32.6 months follow-up of the five patients treated at our center with the recommended dose of 3.4 mg/kg Q3W. Baseline demographics and corneal events are shown in the *Online Supplementary Table S1*, efficacy parameters are summarised in Table 1.

Case 1. This 51-year old female with 1q amplification and t(11;14) had received four prior lines and was proteasome inhibitor (PI) and immunomodulatory agent (IMiD) refractory. She was a contact lens wearer and initially continued this against medical advice. Her baseline eye examination was normal. She completed 16 doses of belamaf

monotherapy and achieved a complete response (CR) with a PFS of 18.9 months, a treatment-free-interval (TFI) of 6.5 months before clinical relapse. Following dose three, she developed grade (G) III corneal events (dry eyes, photophobia) limiting her driving ability. This was managed by an increased frequency (2 hourly) and duration of dexamethasone eye drops and preservative-free (PF) lubricant eye drops until improvement to GI whereupon they were tapered slowly. Dosing was delayed by 98 days and recommenced with a 50% dose reduction (at 1.7 mg/kg). Further intermittent treatment delays were required due to GII corneal events, managed as previously with no further dose reductions. Corneal events fully resolved 9.5 months following the last dose of belamaf. Secondary cataracts were identified and surgically extracted.

Case 2. This 51-year old male had four prior lines of therapy and was IMiD and daratumumab refractory. He had a history of laser ocular surgery and had a normal baseline eye examination. He completed 16 doses of belamaf monotherapy, achieving stringent CR (sCR) with resolution of extramedullary disease. This response was maintained after 34.4 months follow-up with a TFI of 20.0 months. Following two doses of belamaf he developed GIII corneal events (blurring of vision, dry eye) requiring increased frequency of dexamethasone eye drops (4 hourly), PF lubricant eye drops and interruption of belamaf dosing. Dose 3 was delayed by 50 days and reduced by 25% (2.55 mg/kg). Corneal events subsequently remained at <GII. He developed raised intra-ocular pressure, which responded to a topical pressure lowering agent and tapering of steroid eye drops. A further 25% dose reduction from original dose (1.7 mg/kg) was required due to asymptomatic GIII gamma-glutamyl transferase (GGT) elevation. Corneal events fully resolved 6.8 months following the last dose. Secondary cataracts were identified and surgically extracted.

Case 3. This 57-year old female with 1q amplification and t(11;14) translocation received six prior lines, was IMiD refractory and had multiple co-morbidities (Arnold Chiari malformation with cerebellar tonsillar descent, pharyngeal dysphagia, diabetes and bronchiectasis) with poor tolerance to prior therapies. She had a history of dry eyes

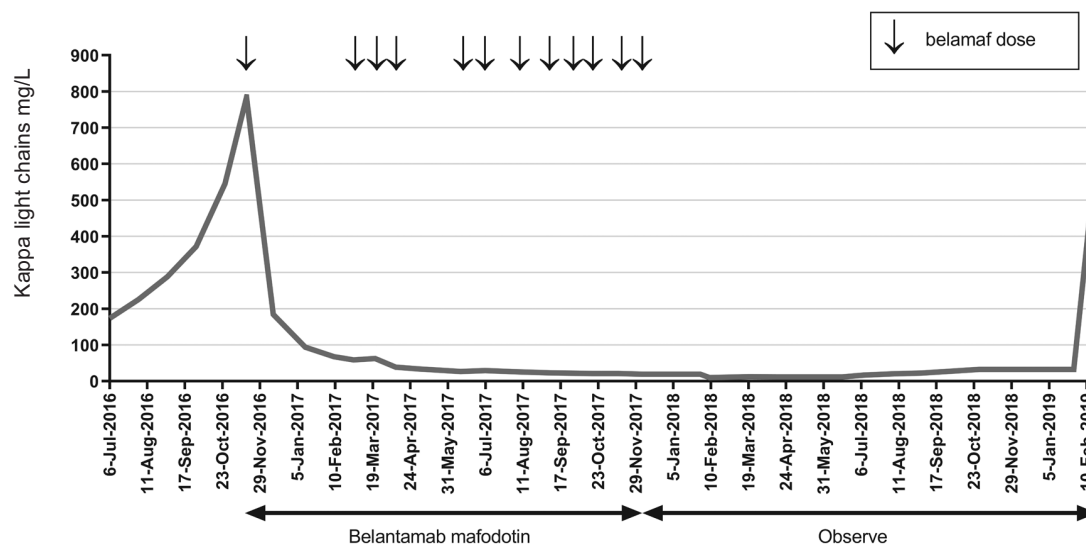


Figure 1. Graphical representation of Case 4 showing decline in kappa light chains with Belantamb Mafodotin (belamaf) (doses represented by arrows). Treatments were planned to be given at 21 day intervals.

Table 1. Corneal events and efficacy.

Parameter	Subject					Median
	1	2	3	4	5	
Number of dose interruptions	3	3	6	5	5	5
Number of dose reductions	2	2	2	2	2	2
Highest grade corneal AE/ CTCAE criteria v4.0	3	3	2	2	2	2
Resolution of corneal event from last dose/ months	9.5	6.8	3.3	12.0	9.8	9.5
Best response	CR	sCR	sCR	VGPR	VGPR	
Follow-up/ months	40.5	34.4	32.6	32.5	28.5	32.6
PFS/ months	18.9	Not reached	Not reached	29.1	15.2	29.1
TFI/ months	6.5	Not reached	Not reached	17.6	7.8	17.6
TNT/ months	23.0	Not reached	Not reached	31.0	21.7	31.0

AE: adverse events; CTCAE: common terminology criteria for adverse events; PFS: progression free survival; TFI: treatment free interval; TNT: time to next treatment; CR: complete response; sCR: stringent complete response; VGPR: very good partial response. All response parameters were in accordance with IMWG criteria;^{14,15} survival parameters were calculated by Kaplan-Meier method using GraphPad Prism 8.

and narrow anterior chamber bilaterally by slit lamp examination at baseline. She completed 12 doses of belamaf and achieved sCR; but stopped due to a persistent cough, which aggravated cerebellar herniation. The sCR was maintained with a TFI of 20.8 months. She developed GII corneal events (blurring of vision, dry eye) following dose one, managed by a prolonged duration of dexamethasone eye drops and PF lubricant eye drops. Belamaf was delayed by 30 days until improvement to GI. She received subsequent doses at 25% reduction (2.5 mg/kg); however, developed GII corneal events after dose 5 requiring a further delay and a 25% dose reduction (to 1.7 mg/kg). She developed raised intra-ocular pressure and was managed with topical pressure lowering agents. Six dose interruptions were required due to recurrent chest infections and corneal events. Monthly prophylactic intravenous immunoglobulin was commenced due to progressive hypogammaglobulinaemia. Corneal events fully resolved 3.3 months following the last dose.

Case 4. This 57-year old male with 1q amplification and t(11;14) translocation received three prior lines, was refractory to carfilzomib and had a normal baseline eye examination. He completed 12 doses of belamaf, stopping following prolonged hospitalisation with a probable fungal chest infection. He achieved a very good partial remission (VGPR) with a PFS of 29.1 months and TFI of 17.6 months. He continued to work as a builder whilst on treatment and developed progressive hypogammaglobulinaemia. Impaired humoral immunity was demonstrated by a sub-optimal response to pneumococcal vaccine and regular intravenous immunoglobulin replacement therapy was commenced. He developed GII corneal events (blurring of vision and dry eye) following dose one of belamaf which was managed by an increased duration and frequency (up to hourly) of dexamethasone eye drops and PF lubricant eye drops, with a 77 day delay in treatment until improvement to GI. Despite this, his kappa light chains continued to fall (Figure 1) and dose 2 was subsequently administered with a 50% dose reduction (1.7 mg/kg). A further three treatment interruptions were required due to GII corneal events (blurred vision, photophobia, dry eye). He developed secondary raised intra-ocular pressure, which was poorly responsive to intraocular lowering agents and dexamethasone eye drops were substituted with fluorometholone.

Case 5. This 66-year old female had three prior lines and had adverse risk myeloma (100% del 17p), was PI refractory and relapsed within 1 year of autologous stem cell trans-

plant. Baseline eye examination was unremarkable. She received 16 doses of belamaf monotherapy and achieved a VGPR with a PFS of 15.2 months. After dose one, she developed a GII infusion related reaction, which led to a 25% dose reduction (to 2.5 mg/kg). A further 25% dose reduction (1.7 mg/kg) was required due to GII corneal events, managed with an increased frequency of dexamethasone eye drops to hourly and PF lubricant eye drops, with subsequent tapering on improvement. Secondary raised intra-ocular pressure was managed with topical pressure lowering agents.

Corneal events were common with all patients developing GIV-V corneal staining (Oxford grading scale) with fluorescein sodium 2%. The median time to resolution to Oxford grading scale 0-I was 9.5 months (range: 3.3-12.0) from last dose (Table 1). Dry eye sensation may be secondary to reduced tear production and corneal epitheliopathy; however Schirmer's test was not required in this protocol. Patients were managed with an increase in steroid eye drops frequency (median four-times a day (range: 1 hourly-twice a day), PF lubricant eye drops (during waking hours) as well as dose interruptions (median 14 days [range: 7-98 days]) and reductions (median 2 of 25% each). The optimal management of corneal events is to be determined; however, as dry eye symptoms are common, PF lubricant eye drops are strongly recommended before and during treatment. The evidence for using steroid eye drops in this report was from other antibody-drug conjugates³ and experience with severe dry eye whereby they reduce an inflammatory response to corneal deposits and rapidly suppress ocular surface inflammation.⁶

However, long term steroid treatment is not recommended due to potential complications of raised intra-ocular pressure, cataracts and infection (our patients received prophylactic antibiotic eye drops and required cataract extraction). The DREAMM-2 clinical trial ocular sub-study recently reported no benefit of prophylactic steroid drops to the development of corneal epitheliopathy compared with lubricant eye drops alone.⁷ On this basis, steroid eye drops are no longer recommended. However a short pulse under careful ophthalmology supervision may help relieve symptoms. The main management for corneal events is with lubricant eye drops and belamaf dose modifications (delays and reductions). A suggested approach is shown (Table 2). Alternative belamaf dosing schedules are also under evaluation.

Other antibody drug conjugates (ADC) utilising MMAF or other microtubule targeting cytotoxins have been asso-

Table 2. Suggested recommendations for the management of belamaf related corneal events.

Corneal event* / CTCAE** criteria	Visual acuity***	Recommendations
Grade I	No changes	Continue dosing
Grade II	≤3 lines of decreased vision from baseline	Reduce dose by 25% and continue treatment. Continue lubricant eye drops, at least 1 drop every 2-4 hours whilst awake. Once symptoms improve to Grade I consider resuming treatment with starting dose.
Grade III or IV	>3 lines of decreased vision from baseline or better. Then follow recommendations	Withhold treatment until symptoms improve to grade II as per grade above.
	Severe reduction in visual acuity from baseline (i.e. Snellen fraction ≤20/200) or corneal ulcer	Withhold treatment and consider discontinuation, consult an ophthalmologist immediately.

1. Ophthalmology referral is recommended at baseline and at the onset of visual symptoms. 2. Patients should use preservative free (PF) lubricant eye drops (artificial tears) every 2-4 hours during waking hours. This should commence 24 hours prior to the first dose and continue whilst on treatment and until all treatment related eye symptoms have resolved. Worsening of dry eye symptoms should be actively reviewed and managed accordingly with ophthalmology input. 3. An eye cooling mask may be used during the belamaf infusion and after as tolerated. 4. A short pulse of steroid eye drops may be considered for ≥grade III events to reduce symptoms; however this must be done under the close supervision of an ophthalmologist. These recommendations are subject to change as further data emerges. *Grouped term to incorporate: blurring of vision, dry eye, keratitis. Use worst grade of each event for dosing purposes. **CTCAE: Common Terminology Criteria for Adverse Events v4.03. ***Assessed by Snellen chart.

ciated with corneal events. Typical symptoms are blurred vision, keratitis, dry eye and microcystic epithelial damage.^{5,8} SGN-75 is a CD70-MMAF conjugate that reported ocular adverse events in 57% of patients;⁹ SGN-CD19A, a CD19-MMAF conjugate reported 84% of patients developing superficial microcystic keratopathy.¹⁰ ABT-414 is an EGFR-MMAF conjugate that reported 89% ocular events in a phase 1 study of glioblastoma multiforme.¹¹ The exact mechanism of corneal events is unknown; however, it may be related to non-specific ADC uptake into actively dividing basal epithelial limbal stem cells residing in the basal epithelial layer of the cornea.¹² The findings are similar to patients treated with high dose cytarabine.¹³

Intravenous immunoglobulin was required for two patients due to recurrent/severe infections. All received cotrimoxazole and aciclovir prophylaxis. Whilst excess infections were not reported we recommend prophylaxis during ongoing therapy.

Belamaf has demonstrated single agent activity for patients with relapsed refractory myeloma and represents a new modality of treatment.⁷ The associated corneal events may be managed with lubricant eye drops and timely dose modifications. Close ophthalmology liaison is essential to allow ongoing treatment and resolution of corneal events.

Rakesh Popat,¹ Dana Warcel,¹ Jenny O'Nions,¹ Anna Cowley,¹ Sasha Smith,¹ William R Tucker,² Kwee Yong¹ and Simona Degli Esposti²

¹National Institute for Health Research Clinical Research Facility, University College London Hospitals NHS Foundation Trust and ²National Institute for Health Research Biomedical Research Centre for Ophthalmology at Moorfields Eye Hospital NHS Foundation Trust & University College London Institute of Ophthalmology, London, UK

Correspondence: RAKESH POPAT
rakesh.popat@ucl.ac.uk
doi:10.3324/haematol.2019.235937

Information on authorship, contributions, and financial & other disclosures was provided by the authors and is available with the online version of this article at www.haematologica.org.

References

- Kumar SK, Rajkumar V, Kyle RA, et al. Multiple myeloma. *Nat Rev Dis Primers*. 2017;3:17046.
- Cho SF, Anderson KC, Tai YT. Targeting B cell maturation antigen (BCMA) in multiple myeloma: Potential uses of BCMA-based immunotherapy. *Front Immunol*. 2018;9:1821.
- Trudel S, Lendvai N, Popat R, et al. Targeting B-cell maturation antigen with GSK2857916 antibody-drug conjugate in relapsed or refractory multiple myeloma (BMA117159): a dose escalation and expansion phase 1 trial. *Lancet Oncol*. 2018;19(12):1641-1653.
- Trudel S, Lendvai N, Popat R, et al. Antibody-drug conjugate, GSK2857916, in relapsed/refractory multiple myeloma: an update on safety and efficacy from dose expansion phase I study. *Blood Cancer J*. 2019;9(4):37.
- Eaton JS, Miller PE, Mannis MJ, Murphy CJ. Ocular adverse events associated with antibody-drug conjugates in human clinical trials. *J Ocul Pharmacol Ther*. 2015;31(10):589-604.
- Thulasi P, Djalilian AR. Update in current diagnostics and therapeutics of dry eye disease. *Ophthalmology*. 2017;124(11S):S27-S33.
- Lonial S, Lee HC, Badros A, et al. Belantamab mafodotin for relapsed or refractory multiple myeloma (DREAMM-2): a two-arm, randomised, open-label, phase 2 study. *Lancet Oncol*. 2019;21(2):207-221.
- Donaghy H. Effects of antibody, drug and linker on the preclinical and clinical toxicities of antibody-drug conjugates. *MAbs*. 2016;8(4):659-671.
- Tannir NM, Forero-Torres A, Ramchandren R, et al. Phase I dose-escalation study of SGN-75 in patients with CD70-positive relapsed/refractory non-Hodgkin lymphoma or metastatic renal cell carcinoma. *Invest New Drugs*. 2014;32(6):1246-1257.
- Moskowitz CH, Fanale MA, Shah BD, et al. A phase 1 study of denintuzumab mafodotin (SGN-CD19A) in relapsed/refractory B-lineage non-Hodgkin lymphoma. *Blood*. 2015;126(23):182-182.
- Reardon DA, Lassman AB, van den Bent M, et al. Efficacy and safety results of ABT-414 in combination with radiation and temozolomide in newly diagnosed glioblastoma. *Neuro Oncol*. 2017;19(7):965-975.
- Zhao H, Atkinson J, Gulesserian S, et al. Modulation of macrophage-mediated internalization decreases ocular toxicity of antibody-drug conjugates. *Cancer Res*. 2018;78(8):2115-2126.
- Guthoff T, Tietze B, Meinhardt B, Becher J, Guthoff R. Cytosine-araboside-induced keratopathy: a model of corneal proliferation kinetics. *Ophthalmologica*. 2010;224(5):308-311.
- Durie BGM, Harousseau JL, Miguel JS, et al. International uniform response criteria for multiple myeloma. *Leukemia*. 2006;20(9):1467-1473.
- Kyle RA, Rajkumar SV. Criteria for diagnosis, staging, risk stratification and response assessment of multiple myeloma. *Leukemia*. 2009;23(1):3-9.