



LYSIS OF A RIGHT ATRIAL THROMBUS OF MORE THAN A WEEK'S DURATION BY HIGH DOSE UROKINASE IN A ONE-YEAR-OLD CHILD

CARLO DUFOUR,* ANGELO CLAUDIO MOLINARI,* LOREDANA TASSO,^o ENRICO DE CARO,[#] ALESSANDRO RIMINI,[#] PIER GIORGIO MORI*

*Department of Pediatric Hematology; ^oDepartment of Infectious Diseases; [#]Department of Pediatric Cardiology, G. Gaslini Children's Hospital, Genoa, Italy

ABSTRACT

The case of a one-year-old child in whom a large catheter-related right atrial thrombus of more than a week's duration was dissolved by urokinase is presented. After one week of unsuccessful heparin treatment, urokinase, via a central venous catheter, was added at the dose of 1500 IU/kg/h. Urokinase was subsequently increased by 1000 U/Kg/hr every day up to a maximum of 4500 IU/kg/h on the basis of thrombus size reduction as assessed by daily cross-sectional echocardiography. One week later the thrombus was almost completely dissolved. No major bleeding occurred.

Warfarin was given for the next three months and the international normalized ratio (INR) was maintained between 2 and 3. At the end of warfarin treatment echocardiography was negative for right atrial thrombosis. This case suggests that local high dose urokinase therapy can be safely and successfully used to dissolve large right atrial thromboses of more than a week's duration.

©1997, Ferrata Storti Foundation

Key words: right atrial thrombus, children, urokinase, fibrinolytic therapy, thrombolytic therapy, central venous catheter

Thrombolytic therapy is being used increasingly in pediatric populations, although in the absence of controlled studies its actual effectiveness and safety still have to be assessed.

We present the case of a one-year-old child in whom local urokinase (UK) treatment lysed a large right atrial thrombus of between one and three week's duration that occurred after the placement of a central venous catheter (CVC).

Case report

A one-year-old child whose family history is negative for thrombosis, during the post-operative period following correction of congenital bilateral hydronephrosis, underwent cross sectional echocardiography (CSE) which confirmed a suspected tricuspid endocarditis but did not detect right atrial thrombosis. The same day (day 0) a CVC was inserted through the right basilic vein but, because X-rays showed that the tip was placed too deeply in the right atrium, the catheter was pulled back 2 cm. A follow-up roentgenograph showed that the tip was correctly located at the junction between the superior vena cava and the right atrium. Two weeks later (day +14) follow-up echocardiography showed that the tricuspid endocarditis had disappeared but revealed the presence of a large, non mobile right atrial thrombus attached to the septum, not touching the tip of the catheter, that occupied two thirds of the right atrial volume

(Figure 1).

After a 50 IU/kg bolus, unfractionated heparin at an initial dose of 400 IU/kg/day was given through the CVC by using a constant 24-hour infusion pump. Six hours later an aPTT (tilt tube manually performed with kaolin- Stago- and Thrombofax-Ortho Diagnostics) of 1.7 times the basal value was achieved and maintained by modifying the scheduled dose by $\pm 10\%$ for seven days. At the end of the heparin course (day +21) the thrombus was unchanged on echocardiogram and we decided to start fibrinolytic therapy through the CVC. Accordingly to previous experience,¹ we added 1500 IU/kg/h of UK to the above heparin dose with the aim of increasing UK by 1000 IU/kg/h every day up to a maximum of 4500 IU/kg/h if daily CSE monitoring showed a decrease in the size of the thrombus. On day +24 (+3 from UK start) with UK at 3500 IU/kg/h, echocardiography revealed a significant reduction of the thrombus. UK was then increased to 4500 IU/kg/h and maintained at this level until day +28 (+7 from UK start) when CSE showed almost complete disappearance of the thrombus (Figure 2). UK was stopped and heparin was increased, maintaining the aPTT at 2 times the basal value for 7 more days. Throughout UK treatment the only bleeding manifestations were mild venipuncture site oozing, which occurred on day +28 and was controlled by local pressure without requiring UK dose reduction. Neither infectious

Correspondence: Carlo Dufour, Department of Pediatric Hematology, G. Gaslini Children's Research Hospital, largo G. Gaslini 5, 16148 Genoa, Italy. Tel. international +39.10.5636277/331. Fax. international +39.10.3762322.

Acknowledgements: the authors wish to thank Mrs. Valerie Wigg for her linguistic consultation, Mrs Roberta Cancedda and Miss Alessia Montobbio for the secretarial assistance.

Received September 18, 1996; accepted March 18, 1997.

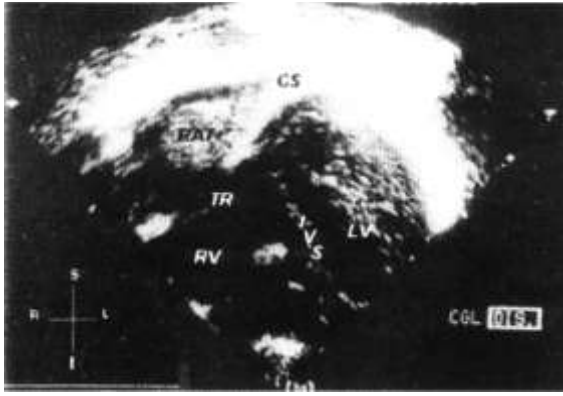


Figure 1. Large non mobile RAT lying beneath the ostium of the coronary sinus and just over the tricuspid valve (day + 14 after catheter placement). RAT=right atrial thrombosis, CS=coronary sinus, TR=tricuspid valve, IVS=interventricular septum, LV=left ventricle, RV=right ventricle.

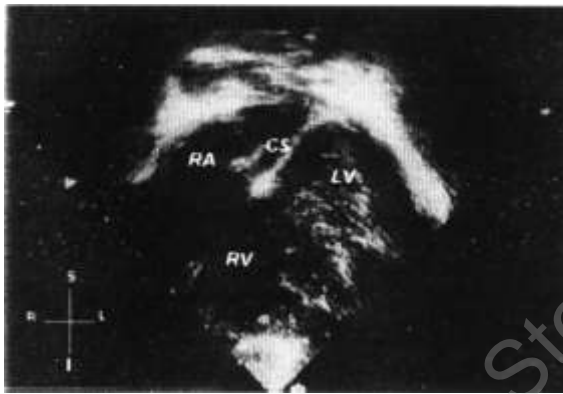

Figure 2. The RAT is no longer evident after 7 days of UK infusion (day +28 after catheter placement). RA= right atrium, CS=coronary sinus, LV=left ventricle, RV=right ventricle.

complications nor pulmonary embolism symptoms occurred. Chest X-ray was normal. Fibrinogen, whose baseline value was 382 mg/dL (Clauss method), remained within the normal range (130-400 mg/dL) except for a single value of 109 mg/dL which coincided with the above mentioned minor bleeding. No hemorrhages were observed during heparin therapy.

Seven days after the end of UK treatment the thrombus was no longer evident on echocardiography. Warfarin was added to heparin at a loading dose of 0.3 mg/kg/day for three days. When an *international normalized ratio* (INR) of 2.53 was achieved heparin was stopped and the CVC removed. A mean warfarin dose of 0.17 mg/kg/day was required to maintain the INR between 2 and 3 for the next 3 months. At this time echocardiography was still negative for atrial thrombosis and warfarin was stopped. At this writing, nine months after echocardiographic detection, the patient shows no right atrial thrombosis.

Discussion

Right atrial thrombi in infancy and childhood are rare events and only a few isolated cases treated with fibrinolytic agents are reported in the literature (ref. #1, reviewed in ref. #2). Therefore no definite indications are available on what is the most appropriate strategy to adopt in these circumstances.

While in deep venous thrombosis (DVT) the age of the clot seems to be a critical factor in the outcome of fibrinolytic treatment, in that only thrombi of fewer than 8 days are reported to be lysed by UK,³ this probably does not apply to right atrial thrombi since the age of the clot does not seem to be predictive of the success of the treatment. In fact most of the right atrial thrombi reported in the literature in children (reviewed in ref. #2, ref. #4) and adults⁵ have been lysed by UK at ages on the order of weeks and months. The case reported herein is in keeping with this finding. Indeed when UK was started the clot was surely at least one week old but, due to mechanical damage to the interatrial septum that most probably occurred when the catheter was placed too deeply in the right atrium 21 days before, it cannot be excluded that the clot was as old as three weeks.

The different results achieved by thrombolytic therapy in DVT and right atrial thrombi in relation to the age of the clot may probably be explained by the differences in the possibility of UK to enter the thrombus. This depends on both the local blood flow and the structure of the thrombus itself, which in turn is age dependent. In this regard it is clear that a large but non occlusive right atrial thrombus is far more accessible to locally given UK than extensive, occlusive deep venous thrombi. In our case local UK administration, which allowed the drug to reach the surface of the thrombus directly, and the non-occlusive nature of the clot might explain the success of the treatment.

Initial heparin therapy was decided on the basis of some previous successful experiences^{6,7} in order to avoid the higher hemorrhagic risk implied by fibrinolysis. The heparin infusion was monitored, according to our experience, by maintaining the aPTT within the range (1.5-2.5 times the basal value) which is currently described as therapeutic in the literature.⁸

However, it has to be noted that, due to the widely varying sensitivity of aPTT reagents to heparin, the aPTT monitoring system may not always reflect heparin-induced anticoagulation.⁸ This has also been pointed out in a pediatric study⁹ in which aPTT values correctly predicted whether heparin concentrations were therapeutic only 73% of the time. Therefore it is possible that our aPTT of 1.7 times the baseline did not correspond to an anticoagulant effect and it cannot be excluded that heparin failure was due to insufficient dosage.

The case reported here confirms that a large right atrial thrombus between one and three weeks old can be lysed with UK. It also suggests that locally administered high-dose UK is safe and may avoid surgical thrombectomy.

Although tissue plasminogen activator has been successfully utilized in infants,¹⁰ we preferred to use UK under close fibrinogen level monitoring in combination with daily echocardiography on the basis of the previous safe and successful experience acquired by our group.¹

The indication and the efficacy of fibrinolytic therapy, as well as the dosage and the duration of administration of thrombolytic agents have not been clearly established in infants and children as most cases are treated following approaches that are extrapolated from schemes for adults. In order to establish pediatric therapeutic guidelines, the results of the clinical trial currently being run in children by a Canadian group headed by M. Andrew are awaited.

References

1. Pongiglione G, Marasini M, Ribaldone D, Silvestri G, Tuo P, Garelli-Cantoni L. Right atrial thrombosis in two premature infants: successful treatment with urokinase and heparin. *Eur Heart J* 1986; 7: 1086-9.
2. Ryan CA, Andrew M. Failure of thrombolytic therapy in four children with extensive thromboses. *AJDC* 1992; 146:187-93.
3. D'Angelo A, Mannucci PM. Outcome of treatment of deep-vein thrombosis with urokinase: relationship to dosage, duration of therapy, age of the thrombus and laboratory changes. *Thromb Haemost* 1984; 51:236-9.
4. Alkalay AL, Mazkereth R, Santulli T, Pomerance JJ. Central venous line thrombosis: a case management and literature review. *Am J Perinatol* 1993; 10:323-6.
5. Goldhaber SZ, Nagel SD, Theard M, Levine JD, Sutton MG St J. Treatment of right atrial thrombus with urokinase. *Am Heart J* 1988; 115:894-7.
6. Makihata S, Mihata S, Nakagawa Y, et al. M-mode and two-dimensional echocardiography in the evaluation of right atrial masses. *J Cardiogr* 1983; 13:633-48.
7. Porath A, Avnun L, Hirsch M, Ovsyshcher I. Right atrial thrombus and recurrent pulmonary emboli secondary to permanent cardiac pacing: a case report and short review of literature. *Angiology* 1987; 38:627-30.
8. Hirsh J. Heparin. *N Engl J Med* 1991; 324:1565-74.
9. Andrew M, Marzinotto W, Massicotte P, et al. Heparin therapy in pediatric patients: a prospective cohort study. *Pediatr Res* 1994; 35: 78-83.
10. Wacker P, Oberhansli I, Didier D, Bumann P, Bognard O, Wyss M. Right atrial thrombosis associated with central venous catheters in children with cancer. *Med Ped Oncol* 1994; 22:53-7.