



SMALL BOWEL INFARCTION BY ASPERGILLUS

LUCIO CATALANO, MARCO PICARDI, DARIO ANZIVINO,* LUIGI INSABATO,° ROSARIO NOTARO, BRUNO ROTOLI

Cattedre di Ematologia, *Microbiologia e °Anatomia Patologica, Università Federico II, Naples, Italy

ABSTRACT

Primary gut involvement by *Aspergillus* is a rare and often fatal complication of intensive anti-leukemic therapy. We describe the case of an adult patient affected by acute leukemia who developed a small bowel fungal thromboembolism without radiographic evidence of lung involvement during the post-induction aplastic phase. The diagnosis was made histologically at laparotomy performed

for small bowel perforation. The patient died a week later in spite of amphotericin-B treatment and neutrophil recovery. Anti-*Aspergillus* prophylaxis and early introduction of amphotericin-B in the treatment of febrile neutropenia is probably advisable in all cases of AML.

©1997, Ferrata Storti Foundation

Key words: *Aspergillosis*, small bowel, mycotic thromboembolism

Clinical reports of gut involvement by *Aspergillus* with arterial infarctions are rare.¹⁻³ We report on an adult male affected by a favorable subtype of acute myeloid leukemia (AML M4-Eo) who succumbed to fatal intestinal aspergillosis (IA) after effective induction treatment.

Case report

AML, FAB M4-Eo with cytogenetic evidence of inv 16, was diagnosed in a 58-year-old male in November 1994. The patient was enrolled in the EORTC GIMEMA trial AML10 and received an induction course of chemotherapy that included arabinosylcytosine 25 mg/m² bolus i.v. then 100 mg/m² c.i. days 1-10, daunorubicin 50 mg/m² i.v. days 1, 3, 5 and etoposide 100mg/m² i.v. days 1-5. On day 11 after the start of therapy an irregular fever began that was not influenced by broad spectrum antibiotics and fluconazole. Microbiological studies and chest X-ray were negative. A few days later (day+15) the patient presented enterorrhagia followed by hypotension and peritonitis with signs of intestinal perforation. An urgent laparotomy showed intestinal dilation and enteric fluid in the peritoneal cavity. Wide necrotic areas with multiple large lacerations were found at level of the fourth duodenal segment and the proximal jejunal loops. Signs of thrombosis in proximal branches of the superior mesenteric artery were also observed, with typical triangular areas having the base on the intestinal wall and the apex on the mesenteric peduncle. A duodenal-jejunal resection with anastomosis on the right of the superior mesenteric artery was performed. Histologic examination

revealed diffuse mycotic infiltration of the intestinal wall with fungal emboli obturating the lumen of the superior mesenteric artery branches (Figures 1 and 2). Colonies of *A. fumigatus* grew from bowel fragment cultures. Melena persisted despite neutrophil recovery (which was accelerated by administration of G-CSF at 300 µg/d for 7 days) and treatment with 50 mg/d liposomal amphotericin, chosen because the patient was in severe renal failure (plasma creatinine 5 mg/dL). The patient died of complications of hemorrhagic shock one week after surgery.

Discussion

In patients with hematological malignancies, invasive fungal infections are mainly produced by *Candida* and *Aspergillus*.⁴ *Aspergillus* spores are airborne and then inhaled; less frequently they can be found in food. The incidence of invasive aspergillosis is increasing.⁵ The main localizations are the lung and cranial sinuses; secondary dissemination to the brain, gut, liver, kidney, thyroid, bone, eye, skin and heart has been reported.⁶ Local spreading is caused by the production of lytic enzymes that give *Aspergillus* the capacity to overcome natural tissue barriers such as cartilage, fascial sheaths and muscle, including the tunica media of blood vessels. In this particular case, infarction by septic thromboembolism is possible.²

Well-known risk factors for IA include prolonged, severe and recurrent neutropenia, acute and chronic GVHD, nasal colonization, air pollution from building construction inside or near the hospital, and the absence or pollution of air filters.^{7,8}

Correspondence: Dr. Lucio Catalano, Divisione di Ematologia Clinica, Nuovo Policlinico, via S. Pansini 5, 80131 Naples, Italy. Tel. international +39.81.7462111. Fax international +39.81.7462165.

Acknowledgements: the authors wish to thank Dr. Luigiana Luciano for the cytogenetic analysis and Nicola Hawe for critical reading of the manuscript. Received September 2, 1996; accepted January 2, 1997.

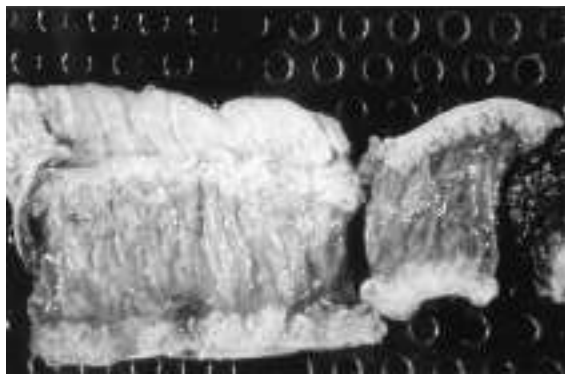


Figure 1. A resected small bowel segment showing multiple areas of necrosis and ulceration.

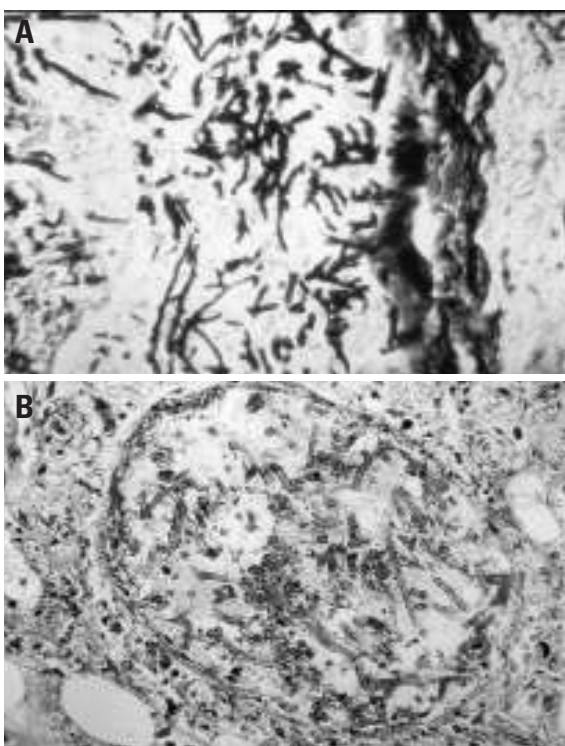


Figure 2. A: *Aspergillus* hyphae in the wall of the resected bowel. Staining: silver impregnation. B: a small intestinal vessel with a mycotic embolus.

Diagnosis of IA is not easy; blood and sputum cultures are negative in the majority of cases and reliable serological tests are not available.⁵ Diagnosis of extrapulmonary localizations is based upon histology and microbiology, most often on post-mortem specimens, since bioptical procedures can be hindered by the critical condition of the patient.¹ This is the case of rare bowel infarction as an early manifestation of IA (refs. #1-3, and present report). Anecdotal cases of gut involvement without lung infection have been documented in classic autopsy

studies of neoplastic patients,⁶ raising the possibility that enteric mucosa damage caused by cytotoxic drugs could allow *Aspergillus* to spread into blood vessels. The observation of the skin as the primary site of entry of *Aspergillus* via bandage-induced skin lesions could further support possible extrapulmonary entry.⁹ However, in our case subclinical primary lung infection cannot be ruled out since autopsy was not performed. *Ante mortem* diagnosis of intestinal fungal invasion is rare¹ because symptoms of abdominal pain and gastrointestinal hemorrhage are not specific, and radiological and echographic studies are not characteristic. In our patient, the unusual isolated parietal duodeno-jejunal localization did not allow an early diagnosis, and even a peroral endoscopy would not have been helpful due to the distal site of the lesions. Diffuse mycotic embolization of the intestinal wall is an uncommon event that in our case proved to be irreversible: surgical resection of the macroscopically involved segments did not stop the diffusion of the ischemic process, despite appropriate antifungal treatment and hematologic recovery.

Our experience may have implications for the treatment of acute myeloid leukemia.¹⁰ This case underlines: (i) the importance of considering the possibility of visceral localizations of *Aspergillus* species in severely neutropenic patients, even in the absence of clinical pulmonary involvement;¹⁰ (ii) the timeliness of adding amphotericin-B early in the treatment of fever in neutropenic patients; (iii) the necessity of developing new, effective and easy-to-use drugs for prophylaxis; (iv) the possibility that prolonged continuous infusions of cytotoxic drugs can open the way to gut infection by ingested conidia.

References

1. Cohen R, Heffner JE. Bowel infarction as the initial manifestation of disseminated aspergillosis. *Chest* 1992; 101:877-9.
2. Case records of the Massachusetts General Hospital. Case 37-1976. *N Engl J Med* 1976; 295:608-14.
3. Weingrad DN, Knapper WH, Gold J, Mertelsmann R. *Aspergillus* peritonitis complicating perforated appendicitis in adult acute leukemia. *J Surg Oncol* 1982; 19:5-8.
4. Bodey G, Buelmann B, Duguid W, et al. Fungal infections in cancer patients. An international autopsy survey. *Eur J Clin Microbiol Infect Dis* 1992; 11:99-109.
5. Cohen J. Clinical manifestations and management of aspergillosis in the compromised patient. In: Warnock DW, Richardson MD, eds. *Fungal infection in the compromised patient*. 2nd ed. Chichester: John Wiley & Son; 1991. p. 117-52.
6. Young RC, Bennett JE, Vogel CL, Carbone PP, DeVita VT. *Aspergillus*: the spectrum of the disease in 98 patients. *Medicine* 1970; 49:147-73.
7. Martino P, Raccach R, Gentile G, Venditti M, Girmenia C, Mandelli F. *Aspergillus* colonization of the nose and pulmonary aspergillosis in neutropenic patients: a retrospective study. *Haematologica* 1989; 74:263-5.
8. Uzun O, Anaissie EJ. Antifungal prophylaxis in patients with hematologic malignancies: a reappraisal. *Blood* 1995; 86:2063-72.
9. Prystowsky SD, Vogelstein B, Ettinger DS, et al. Invasive aspergillosis. *N Engl J Med* 1976; 295:655-8.
10. Bassan R, Barbui T. Remission induction therapy for adults with acute myelogenous leukemia: towards the ICE age? *Haematologica* 1995; 80:82-90.