

Rethinking the elusive boundaries of EBV-associated T/NK-cell lymphoproliferative disorders

With great interest we read the article published in *Haematologica* by Dr. Fernandez-Pol and colleagues entitled “*Defining the elusive boundaries of chronic active Epstein-Barr virus infection*”.¹ EBV-associated T/NK-cell lymphoproliferative disorders (EBV-T/NK-LPDs) is a spectrum of diseases from infection to malignancy, and all patients suffering these diseases (except infectious mononucleosis (IM)) are in danger. Studying this spectrum from diagnosis to clinical management is extremely urgent. The authors reviewed the recent progress of chronic active EBV infection (CAEBV), in particular adult onset CAEBV, and discussed other entities of EBV-T/NK-LPDs. They summarized the characteristics of different EBV-T/NK-LPDs types and proposed many burning issues that we confront in daily practice: 1) the overlapped histological features and immunophenotype, 2) inconsistent association with hemophagocytic lymphohistiocytosis (HLH), 3) insufficient indicators of malignancy (such as monoclonality), 4) lack of effective markers to predict the biological behavior of the diseases. We highly appreciated this work which inspired us to rethink the elusive boundaries of EBV-T/NK-LPDs; herein, we would like to propose two suggestions regarding the diagnosis of EBV-T/NK-LPDs.

Within the current framework of this spectrum, IM is

considered a self-limiting disease which occurs most often in children and young adults. Although IM is often regarded as a proliferation of B cells, T/NK-cell IM has also recently been reported.² The pathological features of T/NK-cell IM share many similarities with other entities of EBV-positive T/NK-cell lymphoproliferative diseases in biopsy. Especially in the early stage, it is extremely difficult to identify which patients may resolve spontaneously or proceed to chronic stage or recurrent in a short time, even progress rapidly to death. Even many experienced hematopathologists cannot make a precise diagnosis. Besides, EBV-associated HLH (EBV-HLH), which has been proposed as a separate diagnosis, is currently also a challenge for pathologists. The conspicuous morphologic clue is erythrophagocytosis which is not specific and insufficient for diagnosing HLH. Additionally, EBV-HLH is an exclusive diagnosis after ruling out other entities of EBV-T/NK-LPDs accompanied by HLH and familial HLH,³ nearly all entities in this spectrum could be associated with HLH. It is often the underlying EBV-T/NK-LPDs rather than the HLH that confuses the diagnosis. Therefore, how to define EBV-HLH is worthy of consideration.

We therefore modified the current framework of the EBV-T/NK-LPDs spectrum, from two aspects (Figure 1). Corresponding to CAEBV, we proposed systemic acute EBV infection (SAEBV) which is defined as non-neoplastic lesions with systemic symptoms of EBV infection within 3 months, including IM and other acute EBV

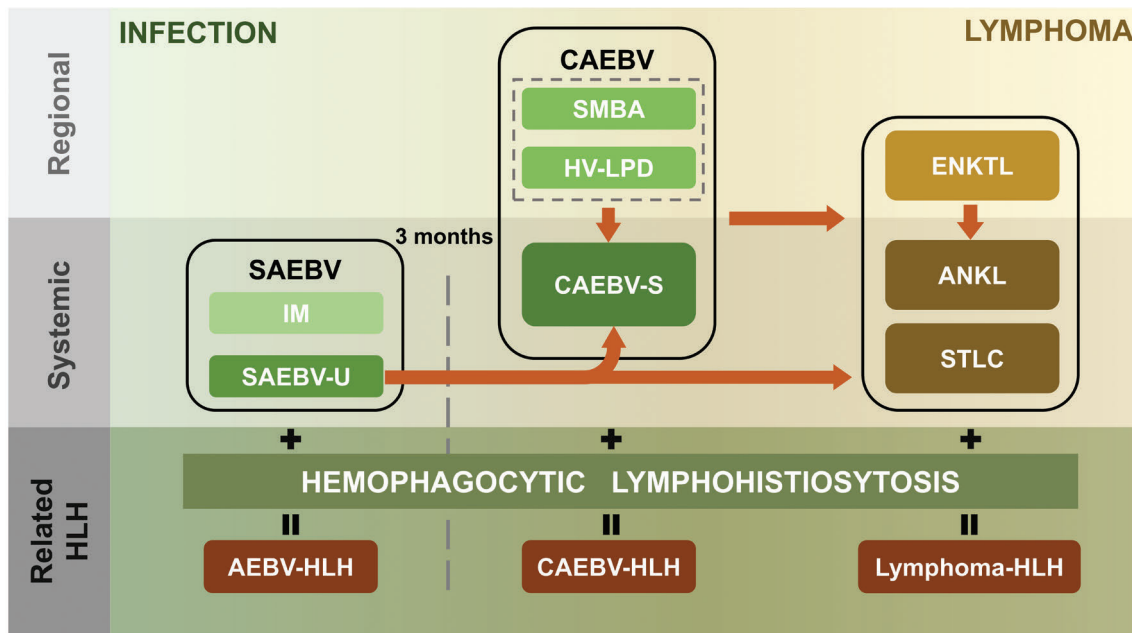


Figure 1. The spectrum of EBV-associated T/NK-cell lymphoproliferative disorders. This spectrum consists of a series of diseases from infection to malignancy. SAEBV is defined as non-neoplastic lesions with systemic symptoms of EBV infection within 3 months, including IM and SAEBV-U. Under the umbrella of SAEBV, IM is considered a self-limiting disease, but SAEBV-U could progress to CAEBV or transform to more invasive T/NK-cell neoplasms (ENKTL, ANKL or STLC) directly within 3 months. Moreover, all forms of CAEBV (HV-LPD, SMBA and CAEBV-S) could also progress to T/NK-cell malignancies and cutaneous CAEBV (HV-LPD and SMBA) may present obvious systemic symptoms to become CAEBV-S. Additionally, all the diseases in this spectrum (except IM) could be accompanied by HLH. SAEBV: systemic acute EBV infection; IM: infectious mononucleosis; SAEBV-U: systemic acute EBV infection, unclassifiable; CAEBV: chronic active EBV infection; SMBA: severe mosquito bite allergy; HV-LPD: hydroa vacciniforme-like lymphoproliferative disorders; CAEBV-S: chronic active EBV infection-systemic form; ENKTL: extranodal NK/T-cell lymphoma; ANKL: aggressive NK-cell leukemia; STLC: systemic EBV-positive T-cell lymphoma of childhood. HLH: hemophagocytic lymphohistiocytosis.

infections. Meanwhile, IM can still be diagnosed retrospectively after follow up for more than 3 months, which is consistent with the current framework. Correspondingly, the cases which would progress to CAEBV or transform to more invasive T/NK-cell neoplasm directly within 3 months are called systemic acute EBV infection, unclassifiable (SAEBV-U), before progression and/or transformation. This modification has many advantages. From an infectious disease point of view, this modified framework is consistent with the general process of viral infection: from acute to chronic infection. From a pathology and/or pathophysiology point of view, the differential diagnosis of IM and SAEBV-U requires long-term follow up due to the significantly overlapped clinical features, morphologic characteristics and immunophenotype. Thus, SAEBV could be an acceptable initial diagnosis that reflects all the known characteristics of the disease at that time. For clinicians, SAEBV may bring their attention to inconsistent prognoses of patients with acute EBV infection, rather than them relaxing their vigilance and regarding all cases as IM. Furthermore, it is a reminder that therapy is to be chosen as a result of a comprehensive analysis of clinical behavior and pathological findings, instead of just focusing on one aspect.

Another suggestion regards EBV-HLH. We suggest considering it as AEBV accompanied by HLH, which that means regarding HLH as a concomitant diagnosis. Currently, there is no clear evidence to distinguish between EBV-HLH and other entities of EBV-T/NK-LPDs associated with HLH (especially systemic EBV-positive T-cell lymphoma of childhood).⁴ Conversely, they share numerous similarities in various aspects. Pathophysiologically, cytotoxic T-cell and/or NK-cell dysfunction is the causative factor of HLH.⁵ Clinically, consistent features such as fever, pancytopenia, splenomegaly, elevated ferritin and other laboratory abnormalities are presented among all EBV-T/NK-LPDs when accompanied by HLH. Prognostically, similar overall survival was noted among the patients with EBV-T/NK-LPDs associated with HLH.⁴ Additionally, because the diagnosis of HLH requires a comprehensive analysis of clinical manifestations, laboratory tests and pathological findings, pathologists could not make such a diagnosis based solely on the specimen. Therefore, EBV-HLH may not be suitable as a separate pathological diagnosis; it is more appropriate to consider HLH as a concomitant diagnosis. The clinicians could make a comprehensive clinical diagnosis like AEBV-associated HLH (AEBV-HLH), based on pathological diagnosis, clinical presentation and genetic testing.

In summary, although the subdivision of EBV-T/NK-LPDs has cast a lot of light on our understanding of these diseases, we still need to be cautious about dividing this spectrum before having clear evidence. Such modification of the current framework could just partly solve the diagnostic dilemmas. We still face many problems: 1) finding early markers to discriminate between IM and SAEBV-U; 2) defining the boundary between infection and malignancy since clonality might not be an adequate marker; 3) predicting clinical behavior such as by combining HLH or evaluating the risk of death in early stage. Clinical and the preclinical studies are urgently needed to aid the diagnosis and clinical management of EBV-T/NK-LPDs.

Zihang Chen¹ and Pujun Guan^{2,3}

¹Department of Pathology, West China Hospital, Sichuan University; ²Department of Radiology, Huaxi Magnetic Resonance Research Centre (HMRR), West China Hospital, Sichuan

University, Chengdu and ³Department of Hematology, West China Hospital, Sichuan University, China

Correspondence:

ZIHANG CHEN - ianchan_0704@hotmail.com

PUJUN GUAN - guanpujun@163.com

doi:10.3324/haematol.2018.215186

Acknowledgments: the authors would like to thank our colleagues, Prof. Weiping Liu and Prof. Sha Zhao for their inspiration and encouragement, and to thank Prof. Li Zhang and Prof. Ling Pan for their help.

Information on authorship, contributions, and financial & other disclosures was provided by the authors and is available with the online version of this article at www.haematologica.org.

References

1. Fernandez-Pol S, Silva O, Natkunam Y. Defining the elusive boundaries of chronic active Epstein-Barr virus infection. *Haematologica*. 2018;103(6):924-927.
2. Jianlan X, Yuhua H, Yuanyuan Z, et al. Acute Epstein-Barr virus-positive cytotoxic T cell lymphoid hyperplasia in the upper aerodigestive tract, mimicking extranodal natural killer/T cell lymphoma, nasal type. *Virchows Arch*. 2018 Nov 28. [Epub ahead of print]
3. Koh KN, Im HJ, Chung NG, et al. Clinical features, genetics, and outcome of pediatric patients with hemophagocytic lymphohistiocytosis in Korea: report of a nationwide survey from Korea Histiocytosis Working Party. *Eur J Haematol*. 2015;94(1):51-59.
4. Smith MC, Cohen DN, Greig B, et al. The ambiguous boundary between EBV-related hemophagocytic lymphohistiocytosis and systemic EBV-driven T cell lymphoproliferative disorder. *Int J Clin Exp Pathol*. 2014;7(9):5738-5749.
5. Ramos-Casals M, Brito-Zerón P, López-Guillermo A, Khamashta MA, Bosch X. Adult haemophagocytic syndrome. *Lancet*. 2014; 383(9927):1503-1516.