

Usefulness of initial plasma dabigatran concentration to predict rebound after reversal

Nicolas Gendron,^{1,2,3} Juliette Gay,^{1,2} Marine Lemoine,⁴ Pascale Gaussem,^{1,2,3} Agnès Lillo-Le-Louet⁴ and David M. Smadja^{1,2,3}

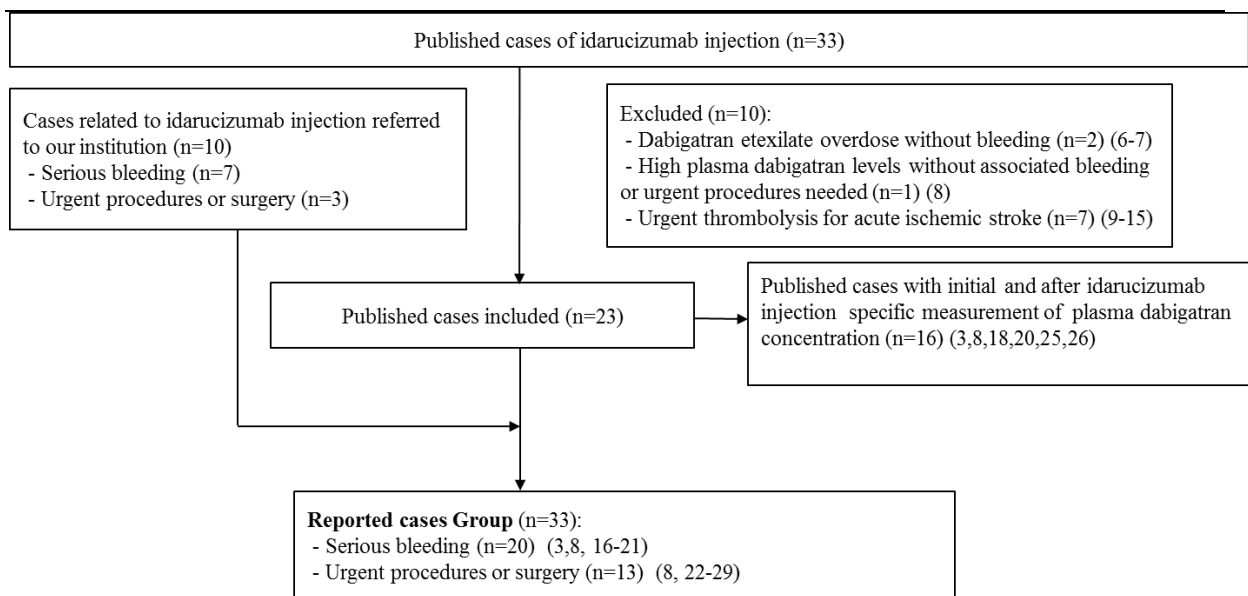
¹AP-HP, European Hospital Georges Pompidou, Hematology Department, Paris; ²Université Paris Descartes, Sorbonne Paris Cité; ³Inserm UMR-S1140, Paris and ⁴AP-HP, European Hospital Georges Pompidou, Regional Center of Pharmacovigilance, Paris, France

Correspondence: david.smadja@aphp.fr
doi:10.3324/haematol.2017.183400

Usefulness of Initial plasma dabigatran concentration to predict rebound after reversal.

Gendron et al.

Supplementary figure 1: Flow chart of all case analyzed and reported in literature until February 2017.



Additional References

1. Chai-Adisaksopha C, Crowther M, Isayama T, Lim W. The impact of bleeding complications in patients receiving target-specific oral anticoagulants: a systematic review and meta-analysis. *Blood*. 9 oct 2014;124(15):2450- 8.
2. Pollack CV, Reilly PA, Eikelboom J, Glund S, Verhamme P, Bernstein RA, et al. Idarucizumab for Dabigatran Reversal. *N Engl J Med*. 6 août 2015;373(6):511- 20.
3. Gendron N, Feral-Pierssens AL, Jurcisin I, de Raucourt E, Bouton V, Fischer AM, et al. Real-world use of idarucizumab for dabigatran reversal in three cases of serious bleeding. *Clin Case Rep*. février 2017;n/a-n/a.
4. Tripodi A. The recommended dose of idarucizumab may not always be sufficient for sustained reversal of dabigatran: comment. *J Thromb Haemost JTH*. sept 2017;15(9):1882- 3.
5. Pollack CV, Reilly PA, van Ryn J, Eikelboom JW, Glund S, Bernstein RA, et al. Idarucizumab for Dabigatran Reversal - Full Cohort Analysis. *N Engl J Med*. 03 2017;377(5):431- 41.
6. Peetermans M, Pollack C, Reilly P, Liesenborghs L, Jacquemin M, Levy JH, et al. Idarucizumab for dabigatran overdose. *Clin Toxicol Phila Pa*. sept 2016;54(8):644- 6.
7. Shapiro S, Bhatnagar N, Khan A, Beavis J, Keeling D. Idarucizumab for dabigatran overdose in a child. *Br J Haematol*. 13 oct 2016;

Usefulness of Initial plasma dabigatran concentration to predict rebound after reversal.

Gendron et al.

8. Šlechtová J, Hajšmanová Z, Lavičková A, Šigutová P. [The first experience with dabigatran antidote in the University Hospital Pilsen]. *Cas Lek Cesk.* 2016;155(8):442- 4.
9. Schäfer N, Müller A, Wüllner U. Systemic Thrombolysis for Ischemic Stroke after Antagonizing Dabigatran with Idarucizumab-A Case Report. *J Stroke Cerebrovasc Dis Off J Natl Stroke Assoc.* août 2016;25(8):e126-127.
10. Berrouschot J, Stoll A, Hogh T, Eschenfelder CC. Intravenous Thrombolysis With Recombinant Tissue-Type Plasminogen Activator in a Stroke Patient Receiving Dabigatran Anticoagulant After Antagonization With Idarucizumab. *Stroke.* juill 2016;47(7):1936- 8.
11. Kafke W, Kraft P. Intravenous Thrombolysis after Reversal of Dabigatran by Idarucizumab: A Case Report. *Case Rep Neurol.* août 2016;8(2):140- 4.
12. Gawehn A, Ayari Y, Heuschkel C, Kaste M, Kermer P. Successful thrombolysis with recombinant tissue plasminogen activator after antagonizing dabigatran by idarucizumab: a case report. *J Med Case Reports.* 29 sept 2016;10(1):269.
13. Schulz JG, Kreps B. Idarucizumab elimination of dabigatran minutes before systemic thrombolysis in acute ischemic stroke. *J Neurol Sci.* 15 nov 2016;370:44.
14. Mutzenbach JS, Pikija S, Otto F, Halwachs U, Weymayr F, Sellner J. Intravenous thrombolysis in acute ischemic stroke after dabigatran reversal with idarucizumab - a case report. *Ann Clin Transl Neurol.* nov 2016;3(11):889- 92.
15. Turine G, Peeters A, Hermans C, Eeckhoudt S, Duprez T. Intravenous thrombolysis after reversal of dabigatran by idarucizumab: a moment to be a pioneer. *Acta Neurol Belg.* 30 janv 2017;
16. Alhashem HM, Avendano C, Hayes BD, Winters ME. Persistent life-threatening hemorrhage after administration of idarucizumab. *Am J Emerg Med.* janv 2017;35(1):193.e3-193.e5.
17. Marino KK, Santiago RA, Dew RB, Berliner N, Connors JM, Connell NT, et al. Management of Dabigatran-Associated Bleeding with Two Doses of Idarucizumab Plus Hemodialysis. *Pharmacotherapy.* 1 sept 2016;
18. Rottenstreich A, Jahshan N, Avraham L, Kalish Y. Idarucizumab for dabigatran reversal – Does one dose fit all? *Thromb Res.* oct 2016;146:103- 4.
19. Hofer S, Philipsenburg C, Weigand MA, Brenner T. Reversal of Anticoagulation With Dabigatran in an 82-Year-Old Patient With Traumatic Retroperitoneal Arterial Bleeding Using the New Antidote Idarucizumab: A Case Report. *Case Rep.* 1 déc 2016;7(11):227- 31.
20. Quintard H, Viard D, Drici M-D, Ruetsch C, Samama CM, Ichai C. Idarucizumab administration for reversing dabigatran effect in an acute kidney injured patient with bleeding. *Thromb Haemost.* 5 janv 2017;117(1):196- 7.

Usefulness of Initial plasma dabigatran concentration to predict rebound after reversal.

Gendron et al.

21. Held V, Eisele P, Eschenfelder CC, Szabo K. Idarucizumab as Antidote to Intracerebral Hemorrhage under Treatment with Dabigatran. *Case Rep Neurol.* déc 2016;8(3):224- 8.
22. Mazur P, Darocha T, Filip G, Grudzień G, Drwiła R, Kapelak B. Idarucizumab for dabigatran reversal in patients with atrial fibrillation undergoing emergency surgery for acute aortic syndrome. *Pol Arch Med Wewn.* 25 juill 2016;126(7- 8):579- 81.
23. Henderson RS, Deshpande S, Williams B, Taylor BS, Tanaka KA. Idarucizumab for Dabigatran Reversal in Emergency Type-A Aortic Dissection. *J Cardiothorac Vasc Anesth.* 13 mai 2016;
24. Thorborg C, Horn E-P, Mofid H, Langer F. Reversal by the specific antidote, idarucizumab, of elevated dabigatran exposure in a patient with rectal perforation and paralytic ileus. *Br J Anaesth.* sept 2016;117(3):407- 9.
25. Sauter TC, Blum S, Nagler M, Schlittler FL, Ricklin ME, Exadaktylos AK. Reversal of Dabigatran Using Idarucizumab in a Septic Patient with Impaired Kidney Function in Real-Life Practice. *Case Rep Emerg Med.* 2016;2016:1393057.
26. Rosenberg L, Gerstrøm G, Nybo M. Idarucizumab for Reversal of Dabigatran Prior to Acute Surgery: A Schematic Approach Based on a Case Report. *Basic Clin Pharmacol Toxicol.* 31 oct 2016;
27. Braemswig TB, Eschenfelder CC, Nolte CH. Emergency lumbar puncture in a patient receiving dabigatran after antagonization with idarucizumab — A case report. *Am J Emerg Med* [Internet]. [cité 6 mars 2017]; Disponible sur: <http://www.sciencedirect.com/science/article/pii/S0735675716307859>
28. Rimsans J, Rhoten M, Sylvester K, Singh SK, Connors JM. Idarucizumab for urgent reversal of dabigatran for heart transplant: A case report. *Am J Hematol.* mars 2017;92(3):E34- 5.
29. Tomaszuk-Kazberuk A, Łopatowska P, Młodawska E, van Ryn J, Reilly PA, Pollack CV. Successful use of idarucizumab as a reversal agent for dabigatran in a patient with acute dissected aortic aneurysm. *Pol Arch Intern Med.* 31 janv 2017;127(1):68- 70.