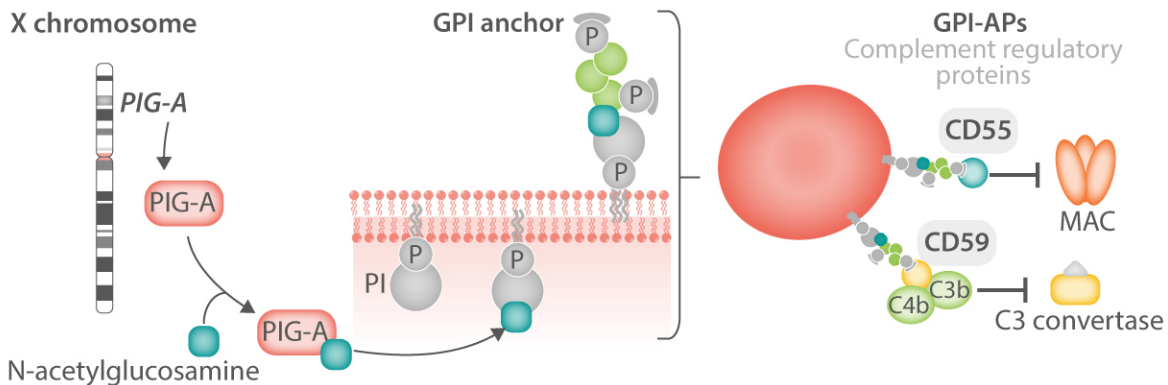
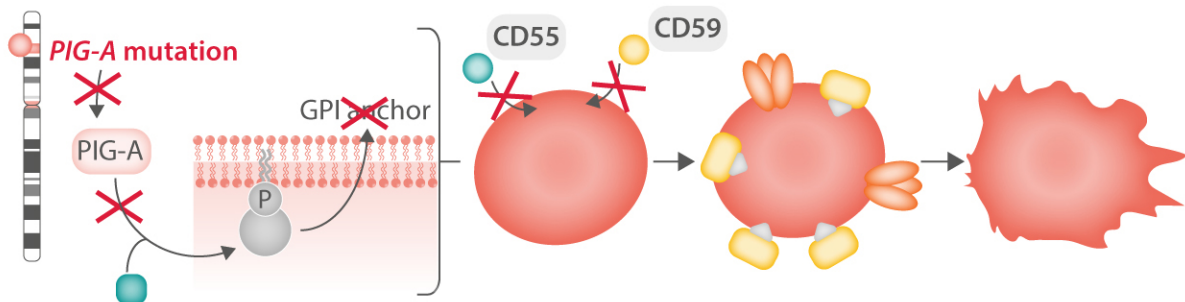


The complex and multifaceted prothrombotic state in paroxysmal nocturnal hemoglobinuria (PNH)

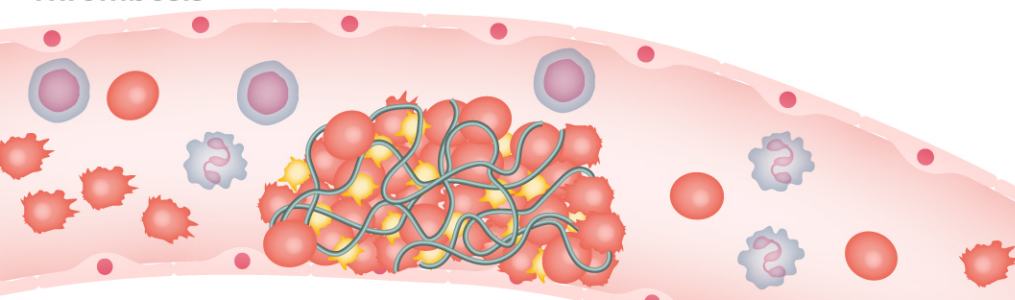
Normal hemopoietic cells



PNH hemopoietic cells



Thrombosis



- Erythrocyte lysis
- Platelet activation
- Intravascular hemolysis
- Neutrophil/monocyte activation