

RAPID LIVER FAILURE RELATED TO CHRONIC C HEPATITIS IN AN HIV SEROPOSITIVE HEMOPHILIC PATIENT WITH SEVERE IMMUNODEPRESSION

Francesco Dragoni, Maria Gabriella Mazzucconi, Arturo Cafolla, Giuseppe Gentile, Monica Peraino, Margarita Gonzalez

Hematology, Department of Human Biopathology, University "La Sapienza", Rome, Italy

ABSTRACT

We report the case of a young HIV seropositive patient with severe hemophilia A who presented rapid liver failure related to his chronic C hepatitis. The patient had been receiving factor VIII:C clotting factor concentrates (mean 60,000 U/year) since 1975. In 1984 alanine aminotransferase presented abnormal levels. The CD4 lymphocyte count in 1991 was normal and ultrasonographic scan showed normal liver morphology. In 1991 the patient were found to be seropositive for HCV antibodies as detected by the ELISA method and confirmed by the RIBA method. One year later, a progressive increase in policlonal γ -globulin and a decrease in the CD4⁺ lymphocyte count to below 500/ μ L were detected in concomitance with ultrasonographic evidence of a progressive increase in the longitudinal diameters of the liver and spleen and signs of liver inhomogeneity. A significant inverse correlation was observed between the increase in the longitudinal diameter of the liver and the decline in albumin levels, and between the increase in the longitudinal diameter of the liver and the drop in platelet count. Elevated levels of ammonemia, γ -glutamyl transpeptidase, alkaline phosphatase and IgA were detected. Moreover, decreased levels of the C4 and C3 complement fractions were documented. At this time (1994), esophagogram and esophagogastroscopy evidenced varicosities in the lower esophageal section (stage F1). The patient died in 1995 March at the age of 29 years of sudden septic shock related to *Pseudomonas aeruginosa* infection.

Key words: hepatitis C virus, HIV infection, hemophilia A, liver failure

The introduction of clotting factor concentrates in 1970 has improved the treatment of coagulopathic patients. Early and self-administration of these concentrates has resulted in a longer life span and a better life quality due to the rapid resolution of bleeding episodes. However, a rise in acute hepatitis was observed following the use of clotting factor concentrates.¹ Before the introduction of virucidal procedures in the processing of factor concentrates, over 50% of hemophilic patients showed previous infections due to hepatitis B (HBV) and non A-non B viruses. This prevalence was higher than that observed in the normal population.² A significant proportion of

coagulopathic patients with chronic aggressive hepatitis showed cirrhotic evolution.³ The onset of clinical cirrhosis is estimated at between 12-18 years from the start of using clotting factor concentrates.⁴ In a recent study, liver failure occurred more frequently in HCV-positive hemophiliacs who were coinfectd with HIV;⁵ moreover, HCV-RNA levels were significantly higher in HIV seropositive than in HIV seronegative hemophiliacs.⁶ In yet another experience,⁷ a high risk of developing hepatocellular carcinoma in HCV-positive hemophilic patients, especially those with concomitant HIV infection, was suggested. Recently, Lee⁸ outlined that the progression of hepatitis C to

Correspondence: Dr. Maria Gabriella Mazzucconi, Department of Human Biopathology, University "La Sapienza", via Benevento 6, 00161 Rome, Italy. Tel. international +39.6.857951 Fax. international +39.6.44241984.

Acknowledgements: bibliographic research was supported by AIDSLINE database, National Library of Medicine, Bethesda, MD, USA.

Received February 8, 1996; accepted May 10, 1996.

severe liver failure in coagulopathic patients with HIV coinfection will put a considerable drain on resources in the coming years.

We report the case of a young HCV- and HIV seropositive hemophilic patient who presented rapid liver failure accelerated by severe deterioration of the immune system.

Case Report

The patient was first observed in 1974. He was eight years old and presented a history of recurrent hematomas and hemarthroses. He was diagnosed as suffering from severe hemophilia A (factor VIII:C < 1 U/dL). In 1975 the patient began receiving factor VIII:C concentrates. In 1984 and during subsequent follow-up we observed altered alanine aminotransferase (ALT) levels. In 1985 the patient was found to be seropositive for HIV infection, which was later confirmed by the Western blot method. The patient also showed seropositivity for HCV infection (1991) with the ELISA test, and this was confirmed by the RIBA method.⁹ HBsAg was negative. Up to 1991 (Table 1) ultrasound scans showed only a slight increase in the longitudinal diameter of the liver and a normal splenic longitudinal diameter without parenchymal alterations. In 1992 treatment with didanosine was started (400 mg/day) for a CD4⁺ lymphocyte

count below 500 μ L (Table 1). After six months the antiretroviral therapy was interrupted because of severe gastralgia. A marked decrease in the CD4⁺ lymphocyte count without HIV-related symptoms followed (Table 1). A progressive rise in polyclonal γ -globulin levels was observed (IgG = 5,070 mg/dL - normal range 800-1,700 mg/dL; IgA = 2,380 mg/dL - normal range 100-470 mg/dL). Moreover, at this time the low levels of the C3 (17.9 mg/dL - normal range 50-90 mg/dL) and C4 (< 11 mg/dL - normal range 11-40 mg/dL) complement fractions were associated with abnormal levels of γ -glutamyl transpeptidase (125 IU/L), alkaline phosphatase (447 IU/L), total bilirubin (3.9 mg/dL) and ammonemia (125 μ mol/L). A drop in platelet count and an ultrasound-documented increase in the longitudinal hepatic and splenic diameters with inhomogeneity of the liver parenchyma and enlargement of the portal vein (13 mm) were progressively observed (Table 1). Duplex doppler hemodynamic studies with an electrically focused 3.75 MHz sectorial probe (Toshiba SSH 140-A) demonstrated a reduction of the mean flow velocity in the portal vein (10 cm/sec. - normal range 19 \pm 2 cm/sec.) and a flat spectrum of the flow in the suprahepatic veins. Esophagogram and esophagogastroscoy evidenced varicosities in the lower esophageal section (stage F1 by esophagogastroscoy). Begin-

Years		1989	1990	1991	1992	1993	1994
	Normal range						
CD4 ⁺ lymphocytes (N./ μ L)	(600-1800)	700	680	510	410	150	51
Platelet count* (N. \times 10 ⁹ /L)	(150-400)	210 \pm 30	200 \pm 39	199 \pm 45	123 \pm 39	71 \pm 9	49 \pm 17
Total proteins (g/dL)	(6.5-8.5)	7.5	8.1	8.2	8.4	8.3	9.2
Albumin (g/dL)	(3.5-5.5)	4.5	4.2	4.1	2.9	2.4	1.9
γ -globulins (%)	(13-21)	20	26	27	32	55	70
Longitudinal liver diameter (mm) (< 120)		127	129	130	141	145	154
Longitudinal spleen diameter (mm) (< 115)		112	112	115	122	135	155

Table 1. Outcome of immunological, hematological, biochemical and morphological parameters evaluated in the patient studied.

* $\bar{x} \pm$ standard deviation is reported.

ning in 1994, albumin levels of less than 2 g/dL and evidence of edema in the lower limbs required substitutive treatment. In March 1995, sudden septic shock occurred that resulted in death within a few hours despite large spectrum antibiotic treatment. Many hemocultures performed at the time of admission had been positive for *Pseudomonas aeruginosa*. The patient was 29-year-old.

Statistical evaluation through linear regression showed a significant inverse correlation between the increase in the longitudinal diameter of the liver and the decrease in albumin levels (R-squared 0.98, $p = 0.0001$) and between the increase in the longitudinal diameter of the liver

and the decrease in platelet count (R-squared 0.97, $p = 0.0004$) (Figure 1).

Discussion

Before virucidal methods were introduced in the processing of plasma derived clotting factor concentrates, infections due to transfusion-transmitted viruses were frequent among hemophiliacs and more than 90% of post-transfusion hepatitis were caused by HCV virus.^{2,3,10} Among our population of 64 coagulopathic HIV-positive patients treated before 1985 with non-inactivated plasma derived concentrates, we found a prevalence of 85.9% HCV seropositive patients.

Recent studies⁵⁻⁸ have hypothesized a higher risk of rapid progression to cirrhosis and liver failure for patients with chronic C virus hepatitis who are coinfecting with HIV. The outcome of our patient was characterized by slight liver involvement and a normal ultrasonographic scan as long as the CD4⁺ lymphocyte count remained above 500 per μL .

Biochemical parameters and hepatic ultrasonographic morphology rapidly worsened when the CD4⁺ lymphocyte count dropped below this level (Table 1).

The abnormal levels of albumin, the C3 and C4 complement fractions, platelet count and the reduced mean flow velocity in the portal vein suggested a rapid progression of liver failure.

The outcome of our case seems to indicate that liver failure was accelerated by the CD4⁺ lymphocyte count falling to lower than 200/ μL , which is an independent parameter associated with progression to AIDS.¹¹

It is interesting to note that a significant correlation between the CD4⁺ lymphocyte count and the grade of cirrhosis is also reported in HIV seronegative patients with chronic C hepatitis.¹² Moreover, *Pseudomonas aeruginosa* and other Gram-negative infections are a frequent deadly complication in the natural history of cirrhotic patients.

Our case confirms that the hypothesis⁵ of rapid liver failure in HCV positive hemophiliacs coinfecting with HIV is accelerated by severe immunodeficiency and poorly related to anti-retroviral treatment.

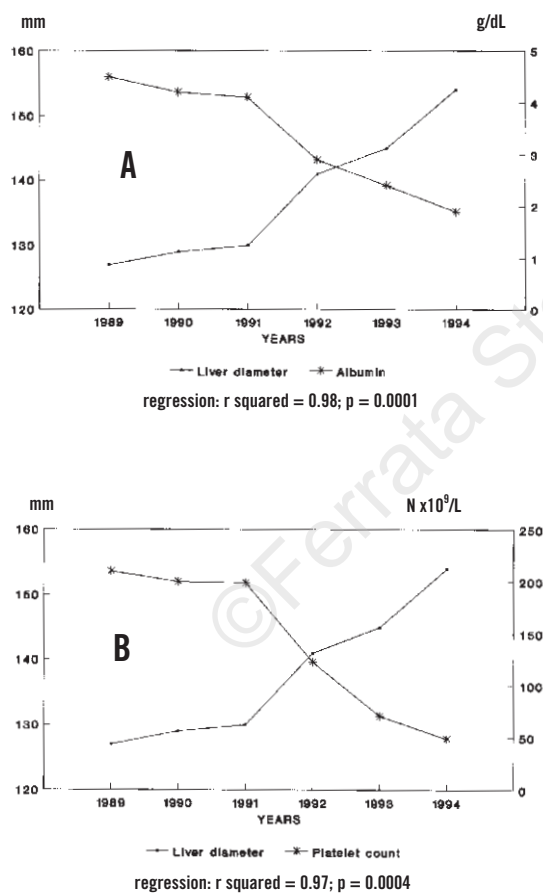


Figure 1. Correlation analysis (linear regression) regarding the outcome of biochemical and morphological parameters evaluated in the patient studied.

Panel A: correlation between longitudinal liver diameter and albumin levels. Panel B: correlation between longitudinal liver diameter and platelet count.

References

1. Kasper CK, Kipnis SA. Hepatitis and clotting factor concentrates. *J Am Med Assoc* 1972; 221:510.
2. Brettler DB, Alter HJ, Dienstag J, Forsberg AD, Levine PH. Prevalence of hepatitis C virus antibody in a cohort of hemophilia patients. *Blood* 1990; 76:254-6.
3. Schimpf K. Liver disease in hemophilia. *Lancet* 1989; 1:323.
4. Triger DR, Preston FE. Chronic liver disease in haemophiliacs. *Br J Haematol* 1990; 74:241-5.
5. Eyster ME, Diamondstone LS, Lien JM, Ehmann WC, Quan S, Goedert JJ. Natural history of hepatitis C virus infection in multitransfused hemophiliacs: effect of coinfection with human immunodeficiency virus. *J AIDS* 1993; 12:602-10.
6. Eyster ME, Fried MW, Di Bisceglie AM, Goedert JJ. Increasing hepatitis C virus RNA levels in hemophiliacs: relationship to human immunodeficiency virus infection and liver disease. *Blood* 1994; 84:1020-3.
7. Colombo M, Mannucci PM, Brettler DB, et al. Hepatocellular carcinoma in hemophilia. *Am J Hematol* 1991; 37:243-6.
8. Lee CA. Hepatitis C and haemophilia. *Br Med J* 1995; 310: 1619-20.
9. Chistolini A, Filoni V, Dragoni F, Piro L, Mazzucconi MG, Isacchi G. Hepatitis C virus antibody in coagulopathic patients: Elisa and Riba methods. *Haematologica* 1993; 4:252-4.
10. Brettler DB, Levine PH. Factor concentrates for treatment of haemophilia: which one to choose? *Blood* 1989; 73:2067-73.
11. Arcieri R, Puopolo M, Baudo F, et al. The impact of antiviral therapy with zidovudine: a retrospective study on HIV-positive hemophiliacs in Italy. *Haematologica* 1994; 80:25-30.
12. Lombardo L, Capaldi A, Poccardi G, Vineis P. Peripheral blood CD3 and CD4 T-lymphocyte reduction correlates with severity of liver cirrhosis. *Int J Clin Res* 1995; 25:153-6.