

CRYOPRECIPITATE-POOR PLASMA FRACTION (CRYOSUPERNATANT) IN THE TREATMENT OF THROMBOTIC THROMBOCYTOPENIC PURPURA AT ONSET. A REPORT OF FOUR CASES

Cesare Perotti, Lorella Torretta, Ermete Molinari^o, Laura Salvaneschi

Servizio di Immunoematologia e Trasfusione I.R.C.C.S. Policlinico San Matteo, Pavia; ^o Istituto di Medicina Interna ed Oncologia Medica, Università di Pavia, I.R.C.C.S. Policlinico San Matteo, Pavia, Italy

ABSTRACT

Treatment of thrombotic thrombocytopenic purpura (TTP) with cryoprecipitate-poor plasma (cryosupernatant) as substitution liquid has brought a portion of the relapsing forms of this syndrome under control. We experimented the use of plasma exchange (PE) with CPP as plasma substitute in the initial treatment of four patients with TTP at onset, in an attempt to elicit a faster response to therapy. We observed a clinical response in the four patients treated; however, laboratory indices of complete and stable response (platelet count, serum lactate dehydrogenase level) did not normalize in concert with clinical improvement.

Key words: thrombotic thrombocytopenic purpura, plasmapheresis, cryoprecipitate-poor plasma fraction

Thrombotic thrombocytopenic purpura (TTP) is a rare condition of unknown etiology characterized by microangiopathic hemolytic anemia, thrombocytopenia, bizarre fluctuating neurological signs, fever and possible renal involvement. A pathogenetic role in the disease has been variously attributed to the presence of proaggregating agents in plasma, to the lack of an inhibitor of platelet aggregation, to a defect in prostacyclin production due to endothelial damage, or to the absence of a plasma factor capable of stimulating prostacyclin production.¹⁻⁵

The presence of unusually large multimers of von Willebrand factor (ULvWF), synthesized and stored primarily by endothelial cells, may be responsible for the heightened platelet aggregability characteristic of this syndrome.⁶⁻⁷ Nowadays, TTP cases that do not respond to fresh frozen plasma (FFP) are successfully treated with cryoprecipitate-poor plasma (CPP) lacking ULvWF multimers.⁸ In fact, the cryosupernatant, like FFP, possesses ULvWF process-

ing activity able to avoid the formation and build-up of ULvWF multimers, and it is also free of the large multimers retained in the cryoprecipitate.⁹

Materials and Methods

We investigated four patients with acute idiopathic TTP. The laboratory parameters used to evaluate treatment response were platelet count ($\times 10^9/L$) and serum lactate dehydrogenase level (LDH IU/L). Plasma exchange (PE) procedures were performed every day at the beginning of treatment until a platelet count of $100 \times 10^9/L$ and normal LDH values were achieved; thereafter, PE was run on alternating days until complete remission.

Concurrent therapy consisted of prednisone 1-2 mg/kg/day and acetylsalicylic acid 1 g/day (when platelets rose above $50 \times 10^9/L$).

Cryosupernatant was obtained by thawing FFP to 4°C over 16-24 hours and then centrifuging it at 4°C and 4,000 rpm.

Case reports

Case 1. A 32-year-old woman was admitted with neurological symptoms, hemolytic anemia (Hb 7.1 g/dL, total bilirubin 5.6 mg/dL), thrombocytopenia (plt $25 \times 10^9/L$), high LDH level (4400 IU/L), normal fibrinogen degradation products and ECG signs of myocardial ischemia. Ten PE procedures (6 consecutive and 4 on alternating days) were required for a complete and lasting response.

Case 2. A 43-year-old man admitted with headache, microangiopathic hemolytic anemia (Hb 8.3 g/dL, total bilirubin 2.26 mg/dL, marked schistocytosis, thrombocytopenia (plt $13 \times 10^9/L$), high LDH level (3670 IU/L) underwent 12 PE procedures before remission.

Case 3. A 57-year-old woman presented with severe headache, petechiae and mucosal bleeding. Laboratory findings revealed hemolytic anemia (Hb 8.2 g/dL, total bilirubin 3.9 mg/dL), marked thrombocytopenia (plt $12 \times 10^9/L$), high LDH level (1245 IU/L), normal coagulation parameters. A partial remission was obtained with five consecutive PE, then 9 more procedures were required to achieve a stable remission.

Case 4. A 46-year-old man presented with asthenia, fever, ecchymoses, hemoglobinuria, but no neurological symptoms. Blood tests revealed thrombocytopenia (plt $22 \times 10^9/L$), microangiopathic hemolytic anemia (Hb 9.9 g/dL, total bilirubin 3.64 mg/dL) with marked anisopoikilocytosis, high LDH level (1740 IU/L), normal FDP. Remission was obtained with seven PE. An early relapse required 11 additional procedures.

Discussion

TTP is a disease for which excellent results have been obtained in spite of ignorance regarding its causes. Nowadays, a complete, long-term response is achieved in about 90% of patients. Plasma exchange with fresh frozen plasma is the therapy of choice, but other therapeutic strategies (e.g. intravenous immunoglobulins, prostacyclin, vincristine, splenectomy) have been proposed in an attempt to better dominate the syndrome.^{10,11} Cryoprecipitate-

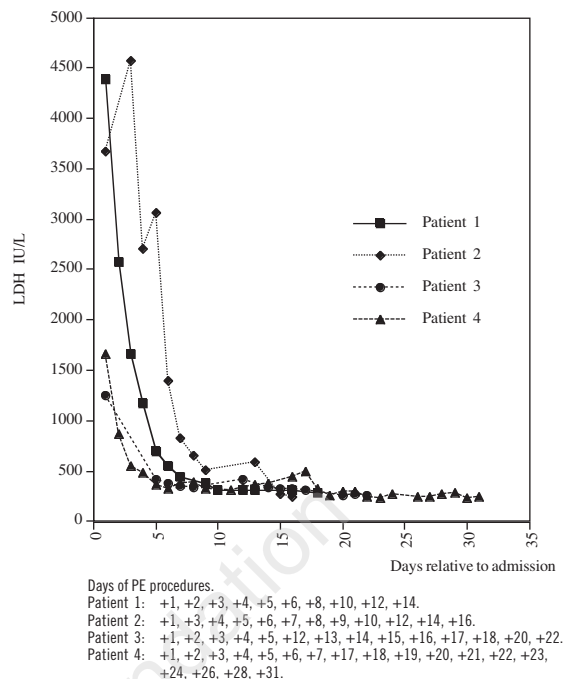


Figure 1. LDH level (IU/L) in the four patients investigated.

poor plasma is a low-cost choice that has produced good results in non-responsive or relapsing patients.¹²

The clinical response in our patients was immediate, with prompt recovery from neurological symptoms. On the other hand, we observed an indolent improvement in platelet counts and LDH values.

Patients #1 and 2 (Figures 1 and 2), who demonstrated a progressive response to treatment and did not relapse, required about the same number of plasma exchanges as our historical patients submitted to PE with FFP (mean 10-12 procedures; unpublished data). Patients #3 and 4, however, suffered an early relapse (plt $< 50 \times 10^9/L$; LDH > 400 IU/L) not associated with a reappearance of clinical symptoms (Figures 1 and 2). Therefore it was necessary to submit them to an additional cycle of PE with CPP until a definitive normalization of the laboratory findings was obtained; this required a total of 14 and 18 plasmaphereses, respectively.

After a median follow-up of 26 months, no relapses have been observed. Daily PE with CPP

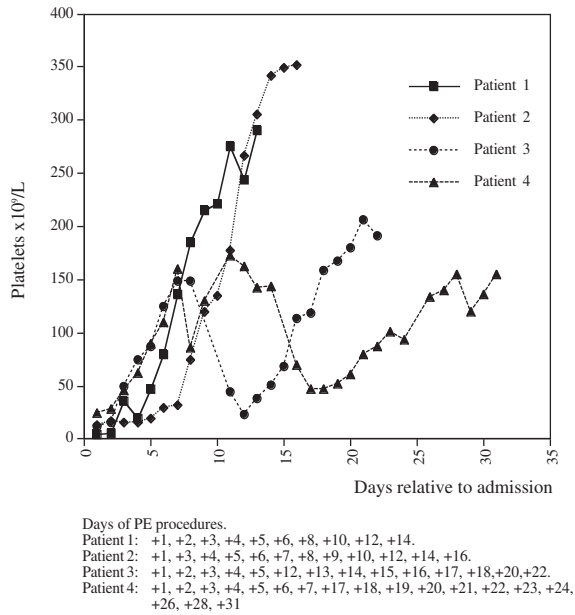


Figure 2. Platelet values ($\times 10^9/L$) in the four patients investigated.

did not result in any significant alteration of the coagulation parameters that required suspending or delaying the procedures.

Despite a prompt clinical response, the laboratory values (platelet count, LDH level) did not normalize as quickly as expected. Probably ULvWF multimers are not the only pathogenic factors. It is likely that CPP is partially lacking in some activity that favors stable restoration of normal platelet aggregability. In our experience PE with CPP as *first-line therapy* proved to be effective in all patients, but it did not offer any advantage in terms of shortening the time needed to establish a stable response. It will be interesting to have a long-term follow-up to observe whether CPP offers

patients a better safeguard against long-term relapses.

References

1. Murphy WG, Moore JC, Kelton JG. Calcium-dependent cysteine protease activity in the sera of patients with thrombotic thrombocytopenic purpura. *Blood* 1987; 70:1683.
2. Wu KK, Hall ER, Rossi EC, Papp AC. Serum prostacyclin binding defects in thrombotic thrombocytopenic purpura. *J Clin Invest* 1985; 75:168-72.
3. Lian ECY. The role of increased platelet aggregation in thrombotic thrombocytopenic purpura. *Semin Thromb Haemost* 1980; 6:401-15.
4. Nawroth PP, Kiesel W, Stern DM. The role of the endothelium in the homeostatic balance of haemostasis. *Clin Haematol* 1985; 14:531-7.
5. Remuzzi G, Misiani R, Mecca G, de Gaetano G, Donati MB. Thrombotic thrombocytopenic purpura: a deficiency of plasma factor regulating platelet-vessel wall interaction. *N Engl J Med* 1978; 299:311.
6. Moake JL, Rudy CK, Troll JH, et al. Unusually large plasma factor VIII: von Willebrand factor multimers in chronic relapsing thrombotic thrombocytopenic purpura. *N Engl J Med* 1982; 307:1432-5.
7. Moake JL, Rudy CK, Troll JH. von Willebrand factor abnormalities and endothelial cell perturbation in acute thrombotic thrombocytopenic purpura. *Am J Med Sci* 1985; 29:47.
8. Obrador GT, Zeigler ZR, Shaddock RK, et al. Effectiveness of cryosupernatant therapy in refractory and chronic relapsing thrombotic thrombocytopenic purpura. *Am J Hematol* 1993; 42:217-20.
9. Byrnes JJ, Moake JL, Klug P, Periman P. Effectiveness of the cryosupernatant fraction of plasma in the treatment of refractory thrombotic thrombocytopenic purpura. *Am J Hematol* 1990; 34:169-74.
10. Centurioni R, Bobbio-Pallavicini E, Porta C, et al. Treatment of thrombotic thrombocytopenic purpura with high-dose immunoglobulins. Results in 17 patients. *Haematologica* 1995; 80:325-31.
11. Bobbio-Pallavicini E, Porta C, Tacconi F, et al. Intravenous prostacyclin (as epoprostenol) infusion in thrombotic thrombocytopenic purpura. Four case reports and review of the literature. *Haematologica* 1994; 74:429-37.
12. Molinari E, Costamagna L, Perotti C, Isernia P, Pagani A, Salvaneschi L. Refractory thrombotic thrombocytopenic purpura: successful treatment by plasmapheresis with plasma cryosupernatant. *Haematologica* 1993; 78:389-92.