

SWEET'S SYNDROME IN A PATIENT WITH IDIOPATHIC MYELOFIBROSIS AND THYMOMA-MYASTHENIA GRAVIS-IMMUNODEFICIENCY COMPLEX: EFFICACY OF TREATMENT WITH ETRETINATE

Gianfranco Altomare, Giovanni Luigi Capella, Elena Frigerio

Istituto di Dermatologia, Università degli Studi di Milano, IRCCS Ospedale Maggiore, Milan, Italy

ABSTRACT

Here we present the case of a patient affected with a unique association of Sweet's syndrome, idiopathic myelofibrosis, spindle-cell thymoma, myasthenia gravis and Good's syndrome (a rare form of thymoma-related, combined immunodeficiency presenting with recurrent respiratory infections). Conventional therapies (corticosteroids, colchicine, DDS, clofazimine) were ineffective or were contraindicated. Treatment with etretinate (50 mg/day) proved effective on skin lesions. Moreover, the patient's general condition unexpectedly improved, with long-lasting (11 months) suppression of respiratory infections and a slight but consistent improvement of hematological parameters such as Hct, MCV, Hb level, RBC, WBC and lymphocyte absolute counts.

Key words: Sweet's syndrome, retinoids, thymoma, myelofibrosis, Good's-syndrome

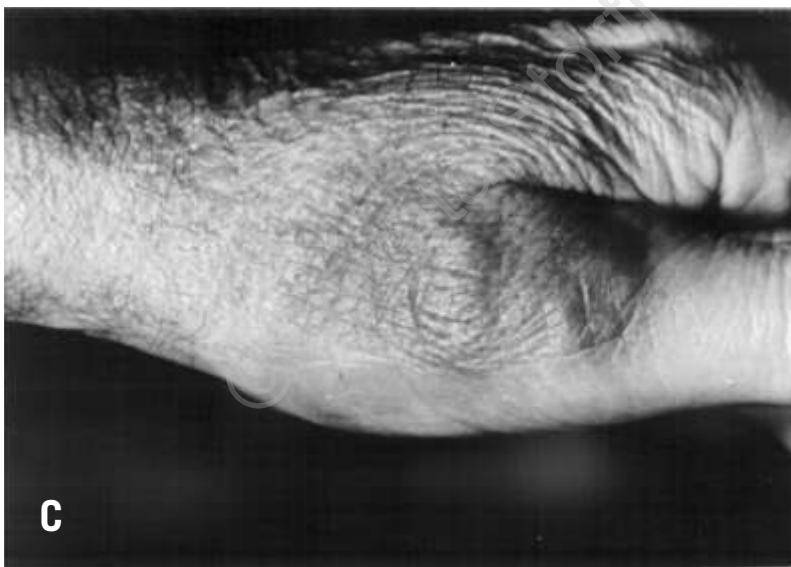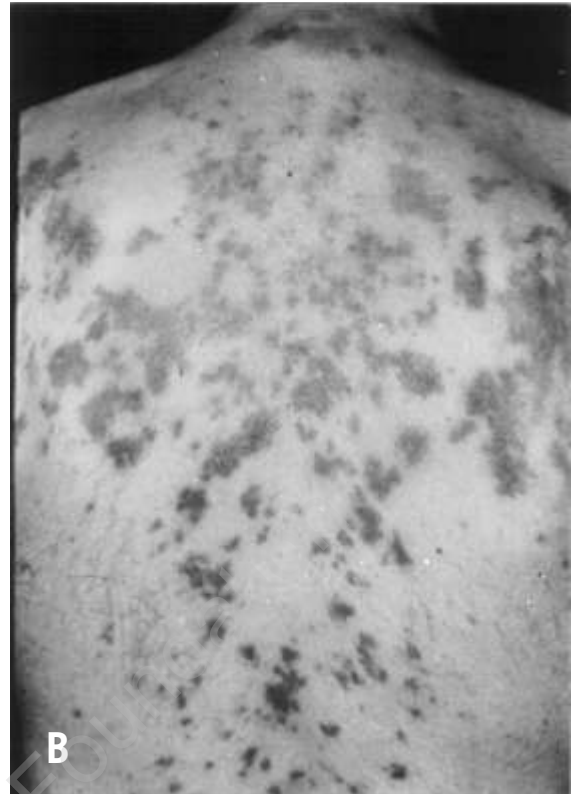
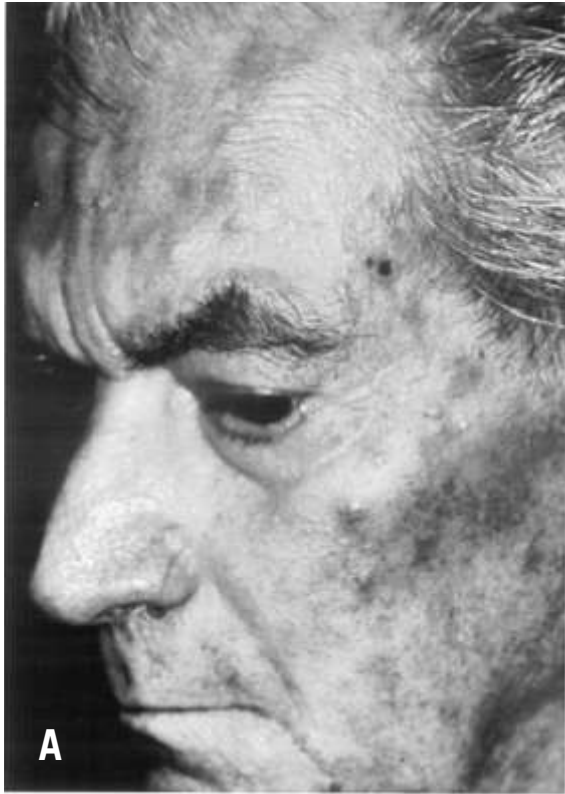Sweet's syndrome (acute febrile neutrophilic dermatosis), first described by Sweet in 1964,¹ is characterized by fever, neutrophilic leukocytosis, and painful plaque-forming inflammatory papules on the limbs, neck, face and back. Histologically, the lesions display a heavy, diffuse dermal infiltrate, mainly of neutrophils. Perivascular leukocytoclasia is marked, giving the impression of vasculitis at low magnification. Sweet's syndrome has been known to be associated with malignancy for many years (in 20% of cases²), especially with myelodysplastic or myeloproliferative disorders such as idiopathic myelofibrosis,³ as in our patient. Sweet's syndrome is usually treated with corticosteroids, colchicine, potassium iodide, clofazimine, diaminodiphenylsulphone (DDS), with fairly good results, but not in our case.

The association of spindle-cell thymoma (SCT) with myasthenia gravis (MG) is well-known, as is the association between SCT and immunological abnormalities such as Good's syndrome, a poorly studied condition character-

ized by hypogammaglobulinemia and various alterations of cellular and seric immunity leading to respiratory infections. Here we present a case characterized by a singular constellation of the disease associations presented above. This patient posed difficult management problems, which were solved with the empiric decision to treat him with etretinate, the well-known aromatic retinoid active on leukocyte chemotaxis and on proliferation/differentiation of epithelial and lymphoid tissues. The clinical response to this uncodified extemporaneous treatment seemed quite favorable, with rapid disappearance of the plaque skin lesions, slight improvement in the significant hematological parameters, and unexpected regression of respiratory infections due to immunological alterations.

Case report

A 71-year-old man with typical Sweet's syndrome (Figure 1 a,b,c) was referred to our Department. Clinical diagnosis was subsequently confirmed histologically. Presumably he could



Figures 1 a,b,c. Sweet's syndrome associated with idiopathic myelofibrosis: typical involvement of the face (A), of the trunk (B), and of the hands (C) before the administration of etretinate therapy.

have been affected with idiopathic myelofibrosis (IMF, agnogenic myeloid metaplasia) since 1983, as documented by previous routine laboratory examinations (marked anemia, thrombocytosis, raised levels of LDH_{2,3} isoenzymes), but a definitive diagnosis was posed only in 1991

when he underwent thymectomy with mediastinal radical lymphadenectomy through an anterior sternal split for a mediastinal mass which proved to be a SCT. Before surgery, he had been suffering for months from typical MG, which persisted after thymectomy, although in milder

form (i.e. the neuromuscular disease could be easily controlled with prednisone 10 mg po on alternate days, and suspension of prostigmin administration had not been followed by relapse of the neuromuscular disease). At admission, physical examination revealed marked hepatosplenomegaly. Lymphadenopathy was absent. Body temperature was 38.5 °C.

Laboratory data of interest were as follows (normal range in brackets): RBCs $2.82 \times 10^{12}/L$ ($4.2\text{--}5.8 \times 10^{12}$); Hb 7.9 g/dL (13.5-17.0); Hct 22% (38-48); MCV 79.6 fL (80-100); platelets $586 \times 10^9/L$ ($150\text{--}450 \times 10^9$); WBCs $5.5 \times 10^9/L$ ($3.5\text{--}10 \times 10^9$), neutrophils 34%, eosinophils 0%, basophils 9% (myeloid series left-shifted), lymphocytes 30%, monocytes 3%, agranular and granular blasts 8%, neutrophilic promyelocytes 5%, neutrophilic myelocytes 4%, neutrophilic metamyelocytes 5%, orthochromatic erythroblasts 2%. RBC morphology: severe anisopoikilocytosis with the presence of dacryocytes, elliptocytes, spherocytes and acanthocytes, and rare Jolly's bodies. Lactate dehydrogenase 37.2 $\mu\text{kat}/L$ (1.46-3.82). Indexes of kidney and liver function were normal, including alkaline phosphatase levels. Plasma proteins: total 53 g/L (60-80); albumin 54.7%; $\alpha 1$ 6.3%; $\alpha 2$ 8.4%; β 12.9%; γ 21.7%, with a true monoclonal IgG- λ peak (immunoelectrophoretic confirmation). IgG 12.85 g/L (8.0-18.0); IgA 1.01 g/L (0.80-4.20); IgM 0.36 g/L (0.50-3.0). C3 690 mg/L (550-1200), C4 190 mg/L (150-450). Serum iron 15 $\mu\text{mol}/L$ (9-31), TIBC 29 $\mu\text{mol}/L$ (45-82), ferritin 941 $\mu\text{g}/L$ (20-400). ESR 60 mm/hr (0-16). C-reactive protein 19 mg/L (0.0-10.0). Leukocyte alkaline phosphatase (LAP) 3+. Total lymphocyte count: $1600 \times 10^6/L$ (2000 ± 1000). Lymphocyte subpopulations: CD2 54.4% (85 ± 4), CD3 47.1% (74 ± 7), CD4 12.5% (48 ± 8), CD8 37.1% (19 ± 7), CD4/CD8 ratio 0.33 (1.7 ± 0.7), CD20 (panB) 2.9% (10 ± 4), HLA-DR 38.5% (16 ± 7), CD57 (NK) 19% (18 ± 8), CD3-HLA-DR coexpression 12.0% (5 ± 4). Bone marrow biopsy: mild dyserythropoiesis with stromal abnormalities typical of IMF. Ph₁-chromosome and other chromosomal abnormalities were absent. In the past this patient had been given four blood transfusions but HIV, HBV and HCV serology were nega-

tive. Skin cell immunity (patch-test; intradermal test) could not be assessed because of the severe cutaneous involvement. *In vitro* lymphocyte proliferation tests were not performed.

Other causes of Sweet's syndrome and secondary myelofibrosis were ruled out, since careful history taking and appropriate investigations were not able to demonstrate occult infections, cancer, or previous exposure to aromatic hydrocarbons or other chemicals.

This patient had never undergone splenectomy because of either good hematological compensation or recurrent episodes of pneumococcal pneumonia and upper respiratory tract infections. Indeed his chest X-ray was clear at admission but during hospitalization another episode of pneumonia ensued, which was successfully controlled with penicillin. Response to antibiotic treatment was immediate, and sputum culture revealed the growth of *Streptococcus pneumoniae*; this circumstantial evidence allowed us to rule out a neutrophilic aseptic respiratory disease. The skin involvement was severe and treatment choice soon proved to be a thorny question. High doses of steroids (up to 100 mg/d methylprednisolone) as well as potassium iodide and clofazimine were tried but proved ineffective. Colchicine and DDS could have done further damage the hemopoietic marrow, so they were immediately ruled out. Thus we decided to treat this patient with etretinate (see below, *Discussion*). The effect of this drug (25 mg bid) on Sweet's syndrome was spectacular, with regression of plaque lesions in less than 5 days. Moreover, lymphocyte and RBC absolute counts unexpectedly increased to $4000 \times 10^6/L$ and $3.29 \times 10^{12}/L$, respectively (Figures 2-3), while the platelet count decreased to 330×10^9 . On the contrary, no substantial variations of immunoglobulin levels and pattern were observed and the CD4/CD8 ratio increased only slightly (Figure 4).

The patient was discharged on etretinate (50 mg/d) and methylprednisolone (25 mg/d), and has been doing well for 11 months. In particular, he has been free from respiratory infections since beginning etretinate treatment, and peripheral blood cell counts have steadily improved, ranging in the above mentioned lev-

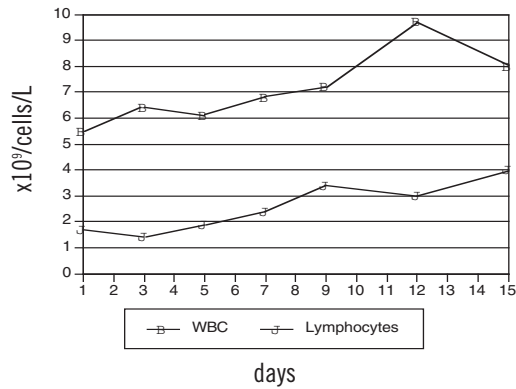


Figure 2. Absolute WBC and lymphocyte count improvement after starting etretinate administration.

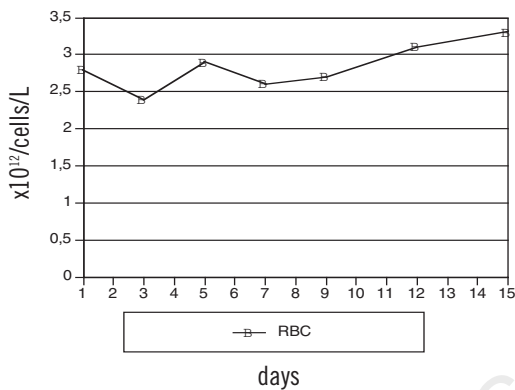


Figure 3. Absolute RBC count also seems to respond to etretinate treatment, but improvement is slighter than that observed in white cell counts. Further follow-up has not demonstrated RBC counts exceeding $3.4 \times 10^{12}/L$ cells. The best Hb level, Hct and MCV were 9.4 g/dL, 27%, and 86.7 fL, respectively.

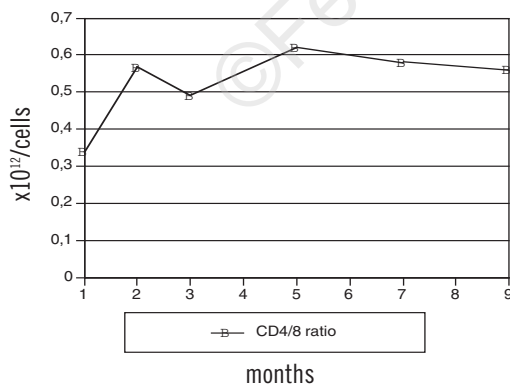


Figure 4. The improvement in the CD4/CD8 ratio, although substantial, has never reached the lower level of normality (range 1.7 ± 0.7). Nevertheless, clinical improvement strongly suggests that CD4/CD8 ratio doubling is significant, at least as an indirect index of improved immunological conditions.

els. Follow-up bone marrow biopsies have so far been refused by the patient.

Discussion

This unlucky patient was the meeting point for an astonishingly intricate constellation of unusual diseases. The associations between MG and SCT and between Sweet's syndrome and IMF are well known. Moreover, Sweet's syndrome itself can be associated with monoclonal gammopathy. In our case leukocytosis was not present, but this finding could be explained in terms of white series depression due to marrow disease, since white count did not reach $10 \times 10^9/L$ even at the recurrence of pneumonia. SCT can be associated with several hematological diseases and nonthymic malignant lesions, such as multiple myeloma, various parenchymatous neoplasms, pure red cell aplasia, and immunoglobulin abnormalities.^{4,5}

A thorough bibliographic and MEDLINE search showed no previous reports linking myelofibrosis with SCT; in any case, our patient undoubtedly presented overt immunological alterations. The occurrence of recurrent upper respiratory tract infections and pneumococcal pneumonia coupled with the immunological laboratory pattern displayed by this patient prompted us to pose a diagnosis of associated Good's syndrome, as a working hypothesis at least. Good's syndrome, first described by Good in 1954,⁶ is a rare association of thymoma with hypogammaglobulinemia; clear-cut criteria for diagnosis have not been formulated because of its rarity, but typical elements of the syndrome are presentation with upper respiratory tract and lung infections,⁷ lymphopenia with a decrease of B and T4 lymphocytes and CD4/CD8 ratio inversion, cutaneous anergia, and eosinopenia.^{5,8,9}

Hypogammaglobulinemia in our patient was apparently restricted to IgM, but spuriously high values of total IgG could be due to the coexisting monoclonal IgG- λ gammopathy, as it was for IgM in the patient described by Jeandel and coworkers.⁵ Indeed immunoelectrophoretic findings were consistent with this interpretation. Moreover, six patients with

monoclonal gammopathy associated with a thymic tumor have been described.⁵

The aromatic retinoid etretinate is widely used by dermatologists for its modulating effects on epithelial and lymphoid cell proliferation and differentiation. Moreover, it inhibits polymorphonuclear chemotaxis,¹⁰ enhances host immune defenses,¹¹ and antagonizes the action of proliferative polypeptide hormones.¹² In fact, this drug curtailed the clinical expression of Sweet's syndrome in our patient, and this was expected since retinoids are known to dampen the chemotactic processes leading to neutrophilic infiltration in Sweet's syndrome.¹³ The unexpected event was the significant and long-lasting improvement of the patient's general condition. Remarkably, the tendency to upper respiratory tract infection recurrences has completely vanished, the worsening trend in hematological parameters has reversed, and for the first time in years this patient has experienced a sense of physical well-being. Etre-tinate probably shares differentiation-influencing actions displayed by other retinoids used in leukemia chemotherapy, such as all-trans-retinoic acid (ATRA); however, etretinate has induced nothing resembling the *retinoic acid crises* caused by ATRA in leukemia patients.¹⁴ Our experience emphasizes the need for studies evaluating further potential applications of etretinate in oncohematology and in immunotherapy, and the importance of empiric decisions when treating intricate conditions for which codified therapy is unavailable.

References

1. Sweet RD. An acute febrile neutrophilic dermatosis. *Br J Dermatol* 1964; 76:349-56.
2. Breier F, Hobisch G, Groz S. Sweet-Syndrom. Akute neutrophilische Dermatose bei multiplem Myelom. *Hautarzt* 1993; 44:229-31.
3. Su WP, Alegre VA, White WL. Myelofibrosis discovered after diagnosis of Sweet's syndrome. *Int J Dermatol* 1990; 29:201-4.
4. Souadjian JV, Silverstein MN, Titus JL. Thymoma and cancer. *Cancer* 1968; 22:1221-5.
5. Jeandel C, Gastin I, Blain H, et al. Thymoma with immunodeficiency (Good's syndrome) associated with selective cobalamin malabsorption and benign IgM-k gammopathy. *J Intern Med* 1994; 235:179-82.
6. Good RA. Agammaglobulinemia - a provocative experiment of nature. *Bull Univ Minn Hosp Med Found* 1954; 26:1-19.
7. Fox MA, Lynch DA, Make BJ. Thymoma with hypogammaglobulinemia (Good's syndrome): an unusual cause of bronchiectasis. *Am J Roentgenol* 1992; 158:1229-30.
8. Saito R, Isogami K, Fujimura S, Ookuda K. OKT4 epitope deficiency in a patient with thymoma and hypogammaglobulinemia. *Nippon Kyobu Shikkan Gakkai Zasshi* 1990; 28: 1120-4.
9. Watts RG, Kelly DR. Fatal varicella infection in a child associated with thymoma and immunodeficiency (Good's syndrome). *Med Pediatr Oncol* 1990; 18:246-51.
10. Bauer R, Schutz R, Orfanos CE. Impaired motility and random migration of vital polymorphonuclears in vitro after therapy with oral aromatic retinoid in psoriasis. *Int J Dermatol* 1984; 23:72-7.
11. Shapiro PE, Edelson RL. Effects of retinoids on the immune system. In: Saurat JH, ed. *Retinoids: New Trends in Research and Therapy*. Basel:Karger, 1985:225-35.
12. Sporn MB. Retinoids: new developments in their mechanism of action as related to control of proliferative diseases. In: Orfanos CE, Braun-Falco O, Farber EN, Grupper Ch, Polano MK, Schuppli R, eds. *Retinoids. Advances in Basic Research and Therapy*. Berlin: Springer-Verlag, 1981:73-6.
13. Kaplan SS, Wechsler HL, Basford RE, Zdziarski UE, Kuhns DB. Increased plasma chemoattractant in Sweet's syndrome. *J Am Acad Dermatol* 1985; 12:1013-21.
14. Marinakis T, Papadimitriou CA, Koufos C, Fertakis A. A recently recognized entity associated with the treatment of acute promyelocytic leukemia: the retinoic acid syndrome. *Haematologica* 1993; 78:192-4.