

AUTOIMMUNE HEMOLYTIC ANEMIA IN MULTICENTRIC CASTLEMAN'S DISEASE

Nicola Lucio Liberato, Paola Bollati, Francesco Chiofalo, Mauro Filipponi, Maurizio Poli

Divisione di Medicina, Ospedale C. Mira, Casorate Primo, Italy

ABSTRACT

We report on a patient affected by multicentric Castleman's disease who developed an acute immunohemolytic anemia due to warm antibody. The clinical course was characterized by refractoriness to the steroidal treatment and by a dramatic improvement of the hematological and objective picture following combination chemotherapy (CHOP regimen). The possible existence of a link between the lymphoproliferative syndrome and the immunological derangement is also discussed.

Key words: Castleman's disease, autoimmune hemolytic anemia

Castleman's disease (CD) is a relatively rare lymphoproliferative disorder of uncertain origin, histologically characterized by the presence of small hyaline follicles with interfollicular capillary proliferation (hyaline-vascular type) or, alternatively, of hyperplastic follicles with interfollicular plasma cell accumulation (plasma cell type). While the former is generally localized with involvement of the mediastinum or of extrathoracic organs, the latter, besides being localized, can also be diffuse (multicentric CD) with generalized lymphadenopathy and multiple organ involvement. This form is generally associated with systemic symptoms (fever, fatigue, weight loss) and laboratory investigations show an increase of ESR, positivity of the inflammation indices, a polyclonal hypergammaglobulinemia and variable positivity of immunological tests (cryoglobulins, rheumatoid factor, anti-smooth muscle antibodies, etc.). Furthermore, positivity of the Coombs' tests is not infrequent, although no sign of hemolysis is usually present.

In this report we describe a case of multicentric CD associated with severe autoimmune hemolytic anemia (AIHA) due to warm anti-

body. Steroid treatment was unsuccessful but polychemotherapy (CHOP) induced sudden cessation of the hemolytic process.

Case report

MCF, a 72-year-old man, was admitted to our Division because of a two-month history of fever, arthralgia, fatigue, dyspnea. The past medical history revealed anterior myocardial infarction at the age of 65; eight months before coming to our observation he had been admitted to another hospital because of profound dyspnea. A diagnosis of cardiac failure was made, and at physical examination hepatosplenomegaly was found but was not investigated further. Upon release treatment with diuretics (furosemide, spironolactone) at standard doses was prescribed.

At admission to our Division the physical examination revealed skin pallor, bibasilar crepitant rales, moderate hepatomegaly (3 cm below the right costal margin) and splenomegaly (5 cm below the left costal margin), and generalized enlargement of the superficial lymph nodes.

Correspondence: Dr. Nicola Lucio Liberato, Laboratorio di Informatica Medica, IRCCS Policlinico S. Matteo, 27100 Pavia, Italy. Tel. international +39.382.503637. Fax. international +39.382.502508.

Acknowledgements: we wish to thank Dr. Paola Isernia for her helpful comments and suggestions.

Received September 13, 1995; accepted November 25, 1995.

Laboratory investigations found a hemoglobin value of 8.2 g/dL, a mean cell volume of 85 fL, a white blood cell count of $4.9 \times 10^9/L$ (with normal differential), a platelet count of $351 \times 10^9/L$ and a γ -globulin level of 2.57 g/dL. Serum immunoglobulin determination showed an increase of IgG (4020 mg/dL) with a normal level of IgA (430 mg/dL) and IgM (70 mg/dL); serum and urinary immunoelectrophoresis revealed no M component or Bence Jones protein. Erythrocyte sedimentation rate was 60 mm/h, serum ferritin 538 ng/mL. Serum erythropoietin, determined by radioimmunoassay, was 80 mU/mL (normal value 15-28). Serum HBsAg, HBcAb, HBeAb and anti-HCV were all negative. A reversed $CD4^+/CD8^+$ ratio was found, while anti-HIV1 and anti-HIV2 were negative. LE-cell test, serum complement, rheumatoid factor, circulating immunocomplexes, cryoglobulins, antinuclear antibodies, direct and indirect Coombs' tests, antimitochondrial antibodies, anti-smooth muscle antibodies were all normal or negative. FSH, LH, ACTH, cortisol, T3, T4, TSH and testosterone were all within the normal range. Abdominal echotomography showed a slight enlargement of the liver and spleen, without focal lesions and without evident lymphadenomegaly. Abdominal CT scan, besides confirming the presence of hepatosplenomegaly,

disclosed enlarged lymph nodes (maximum diameter 2 cm) in the lombo-aortic and iliac regions. Enlarged mediastinal lymph nodes of similar dimensions were found by thoracic CT scan. Needle electromyography was normal.

Biopsy of the left axillary lymph node showed a histological picture of CD, plasmacellular type. A trephine bone marrow biopsy revealed only moderate signs of dyserythropoiesis.

Because of a further decrease in the hemoglobin level (7.9 g/dL) the patient was transfused with two units of packed red blood cells. He was discharged two weeks after admission without any therapy while awaiting the results of biopsies and CT scans; hemoglobin was 10.2 g/dL.

The patient was readmitted 10 days later: hemoglobin was 9.0 g/dL, total bilirubin 1.2 mg/dL. In the next few days there was an acute onset of severe anorexia and fatigue, jaundice and worsening pallor, together with a progressive decrease of the hemoglobin value and an increase of the bilirubin level (as shown in Figure 1); reticulocytes were $170 \times 10^9/L$, LDH 312 U/L, direct Coombs' test was positive (IgG, C3d) as was the indirect Coombs' test. The autoantibody eluted from erythrocyte surfaces revealed panagglutinin specificity (the same specificity as the antibody found in the serum). A diagnosis of AIHA due to warm antibody was made and steroid treatment with methylpred-

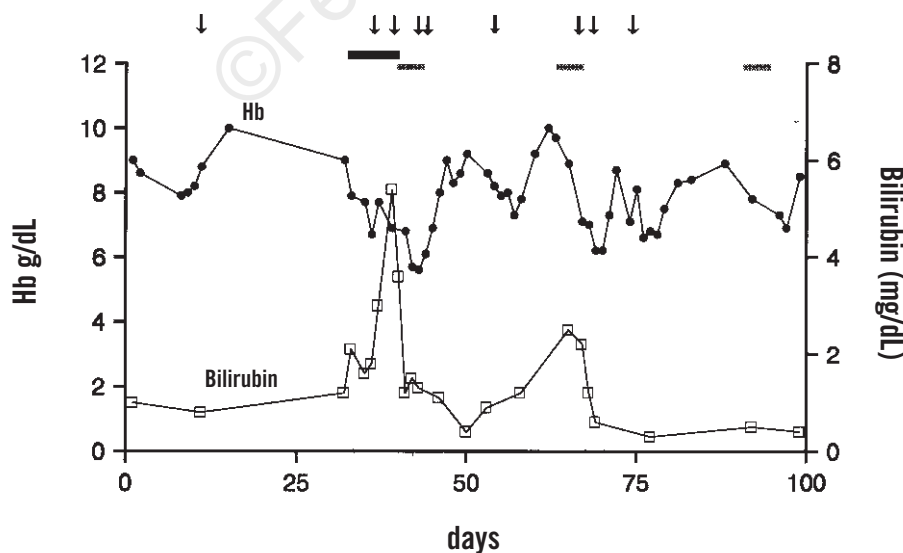


Figure 1. Summary of the main hematological data and therapeutic interventions during the entire period of follow-up. The arrows indicate red cell transfusions, the black bars steroid treatment, the grey bars polychemotherapy.

nisolone (1 mg/kg/day i.v.) begun. This was continued for ten days, but no evident improvement in the hemolytic process could be detected; moreover, transfusion of less compatible units of packed red blood cells caused a peak of the bilirubin levels. Therefore a polychemotherapy regimen was planned (CHOP). This was followed by a progressive decrease in fatigue and anorexia and an increase of the hemoglobin levels, while bilirubin and LDH returned to the normal range (0.8 mg/dL and 195 U/L, respectively).

Eighteen days after the start of the first course of CHOP a new episode of acute hemolytic anemia was documented; a second cycle of chemotherapy was started, again with improvement in hematological parameters. A third course of CHOP treatment was then given, followed by maintenance monochemotherapy (cyclophosphamide, 100 mg/day) because of reduced patient compliance. Physical examination at the end of the third cycle documented complete disappearance of the superficial lymphadenomegalies, while hepatosplenomegaly remained unmodified. A CT scan revealed the complete disappearance of the mediastinal, lomboarctic and pelvic lymphadenomegalies, and a slight reduction in splenic enlargement. Twenty days after discharge from the hospital and after beginning monochemotherapy, the patient died suddenly while eating at his home; no autopsy was performed.

Discussion

Castleman's disease, first described in 1956 as a benign hyperplasia of the mediastinal lymph nodes, today must be considered a heterogeneous lymphoproliferative disorder whose classification stems from a combination of pathological and clinical parameters. In fact, in 1988 Frizzera¹ distinguished: 1) a localized hyaline type; 2) a localized plasma cell form; 3) a multicentric form. Although distinction between the two main histological aspects is important, the main parameter influencing prognosis is the extension of the disease; in fact, in the solitary forms, independently of the histological type, surgical treatment is curative, while in the mul-

ticentric form no medical treatment is resolute and the prognosis remains poor.

Anemia is almost invariably present in the plasma cell variant (localized as well as multicentric) of CD, generally with the features of anemia of chronic disorders (low serum iron and transferrin levels, normal or high ferritinemia), in some cases representing the main clinical feature of the disease;² in the localized forms of CD complete hematological recovery is associated with surgical excision of the mass.^{2,3} The pathogenesis of the anemia follows the same determinants (inhibition of erythropoiesis by tumor necrosis factor and interleukin-1, impairment of erythropoietin response to anemia, alteration of iron metabolism) as in other inflammatory diseases; in CD an additional mechanism could be represented by increased production of interleukin-6, which possesses inhibitory activity on erythropoiesis.⁴

Our patient's anemia at diagnosis showed these characteristics; moreover, in order to evaluate his eligibility for treatment with recombinant human erythropoietin the serum hormone (sEpo) was assayed; despite normal renal function, an inappropriately low value (80 mU/mL) was found for the level of anemia (8.2 g/dL). However, some days after the diagnosis of multicentric CD was established the patient developed severe acute AIHA, which proved to be unresponsive to full-dose steroidal treatment. A polychemotherapy regimen (CHOP) was then started, and this was followed by a dramatic improvement in the patient's well-being and in his main hematological parameters. The progressive increase in his hemoglobin concentration was only interrupted by a slight decrease, probably attributable to a transitory chemotherapy-induced suppression of erythropoiesis.

AIHA can occur during the course of many lymphoproliferative disorders, mainly chronic lymphocytic leukemia (B-CLL). The presence of clinical AIHA in the course of multicentric CD is rare,⁵⁻⁸ despite the relative frequency of a positive Coombs' test without signs of hemolysis; furthermore, an association of AIHA with immune-mediated thrombocytopenia (Evan's syndrome) has been described.⁹ The pathogenesis

of AIHA occurring in multicentric CD is unknown, but as in other lymphoproliferative disorders it could arise from profound dysregulation of immune mechanisms during the course of such diseases.¹⁰ Impairment of cellular immune mechanisms, as expressed by an inversion of the normal CD4⁺/CD8⁺ ratio, has been claimed to be an important determinant of the autoimmune complications in B-CLL. The same mechanism could have operated in our patient, who presented this inversion as a result of an increase of CD8⁺ while CD4⁺ was in the range of normality. Alternative mechanisms however could be hypothesized. Multicentric CD, unlike the localized form that is generally regarded as a reactive process, can be considered a lymphoproliferative disorder; the proliferating B-cell clone(s), as already suggested for B-CLL, could autonomously produce AIHA-inducing autoantibodies.¹¹ Lastly, Yoshizaki *et al.* suggested that IL-6 may play a role in determining the systemic manifestations of CD, including the autoimmune phenomena, through stimulation of plasma cell production and differentiation.⁴

Various immunosuppressive approaches have been attempted in multicentric CD-associated AIHA. Steroids can be considered the treatment of choice, since they possess a strong suppressive effect on immune mechanisms as well as on IL-6 production; in fact, in some cases a clearly beneficial effect has been described.^{7,8} In our patient, steroid treatment was ineffective and, as in other cases in the literature, chemotherapy was effective in producing some improvement.^{7,9} A recently described new approach to the treatment of multicentric CD, potentially useful for the management of IL-6-related complications, is represented by the use of anti-IL-6 monoclonal antibody.¹²

In conclusion, the biological evolution of CD in our patient indicates that AIHA is a complication that is pathogenetically-linked to the primary immunoproliferative disorder. In this case, polychemotherapy determined a rapid improvement in the systemic symptoms as well as in the hematological picture.

References

1. Frizzera G. Castleman's disease and related disorders. *Semin Diagn Pathol* 1988; 5:346-64.
2. Featherstone T, Bayliss AP, Ewen SWB, Brunt PW, Dawson AA. Obscure anemia and hepatic dysfunction in Castleman's disease. *Gut* 1990; 31:834-7.
3. Rojas R, Martin C, Roman J, Garcia JM, Marchal T, Torres A. Autoimmune haemolytic anaemia presenting 9 years prior to Castleman's disease. *Br J Haematol* 1994; 86:431-2.
4. Yoshizaki K, Matsuda T, Nishimoto N, et al. Pathogenic significance of interleukin-6 (IL-6/BSF-2) in Castleman's disease. *Blood* 1989; 74:1360-7.
5. Kessler E. Multicentric giant lymph node hyperplasia: a report of seven cases. *Cancer* 1985; 56:2446-51.
6. Weisenburger DD, Nathwani BN, Winberg CD, Rappaport H. Multicentric angiofollicular lymph node hyperplasia. A clinicopathologic study of 16 cases. *Hum Pathol* 1985; 16:162-72.
7. Brice P, Marolleau JP, D'Agay MF, Epardeau B, Gisselbrecht C. Autoimmune hemolytic anemia disclosing Hodgkin's disease associated with Castleman's disease. *Nouv Rev Fr Hematol* 1991; 33:273-4.
8. Hisatake J, Ishiyama T, Akimoto Y, et al. Autoimmune hemolytic anemia associated with multicentric Castleman's disease with a 28-year history. *Rinsho Ketsueki* 1994; 35:768-73.
9. Marsh JH, Colbourn DS, Donovan V, Staszewski H. Systemic Castleman's disease in association with Evan's syndrome and vitiligo. *Med Pediatr Oncol* 1990; 18:169-72.
10. Caligaris-Cappio F, Bertero MT, Bergui L. Autoimmunity, autoimmune diseases and lymphoproliferative disorders. *Haematologica* 1994; 79:487-92.
11. Stoeber ZM, Stoeber D, Shtalrid M, Sigler E, Geltner D, Berrebi A. Mechanism of autoimmune hemolytic anemia in chronic lymphocytic leukemia. *Am J Hematol* 1993; 43:259-64.
12. Beck JT, Hsu SM, Wijdenes J, et al. Alleviation of systemic manifestations of Castleman's disease by monoclonal anti-interleukin-6 antibody. *N Engl J Med* 1994; 330:602-5.