

Development of classical Hodgkin's lymphoma in an adult with biallelic *STXBP2* mutations

Maciej Machaczka,¹ Monika Klimkowska,² Samuel C.C. Chiang,³ Marie Meeths,^{4,5} Martha-Lena Müller,³ Britt Gustafsson,⁶ Jan-Inge Henter,⁴ and Yenan T. Bryceson^{3,7}

¹Division of Hematology, Department of Medicine, Karolinska Institutet, and Hematology Center Karolinska, Karolinska University Hospital Huddinge, Stockholm, Sweden; ²Department of Clinical Pathology and Cytology, Karolinska University Hospital Huddinge, Stockholm, Sweden; ³Centre for Infectious Medicine, Department of Medicine, Karolinska Institutet, Karolinska University Hospital Huddinge, Stockholm, Sweden; ⁴Childhood Cancer Research Unit, Department of Women's and Children's Health, Karolinska Institutet, Karolinska University Hospital Solna, Stockholm, Sweden; ⁵Clinical Genetics Unit, Department of Molecular Medicine and Surgery, Karolinska Institutet, Karolinska University Hospital Solna, Stockholm, Sweden; ⁶Department for Clinical Science Intervention and Technology, Karolinska Institutet, Karolinska University Hospital Huddinge, Stockholm, Sweden; and ⁷Broegelmann Research Laboratory, The Gades Institute, University of Bergen, Bergen, Norway

ABSTRACT

Experimental model systems have delineated an important role for cytotoxic lymphocytes in the immunosurveillance of cancer. In humans, perforin-deficiency has been associated with occurrence of hematologic malignancies. Here, we describe an Epstein-Barr virus-positive classical Hodgkin's lymphoma in a patient harboring biallelic mutations in *STXBP2*, a gene required for exocytosis of perforin-containing lytic granules and associated with familial hemophagocytic lymphohistiocytosis. Cytotoxic T lymphocytes were found infiltrating the tumor, and a high frequency of Epstein-Barr virus-specific cytotoxic T lymphocytes were detected in peripheral blood. However, lytic granule exocytosis and cytotoxicity by cytotoxic T lymphocytes, as well as natural killer cells, were severely impaired in the patient. Thus, the data suggest a link between defective lymphocyte exocytosis and development of lymphoma in *STXBP2*-deficient patients. Therefore, with regards to treatment of familial hemophagocytic lymphohistiocytosis patients with mutations in genes required for lymphocyte exocytosis, it is important to consider both the risks of hemophagocytic lymphohistiocytosis and malignancy.

Introduction

Historically wrought in controversy, numerous studies in experimental model systems have in the past decade provided strong evidence for a role of the immune system in controlling spontaneously occurring cancers.¹ In this regard, perforin-deficient mice have been reported to spontaneously develop B-cell lymphomas, implicating lymphocyte cytotoxicity in immunosurveillance of hematologic malignancies.² In humans, perforin-deficiency caused by hypomorphic mutations in *PRF1* have been associated with hematologic malignancies, ranging from lymphoma to leukemia, in children and adults.^{3,4}

Autosomal recessive, nonsense mutations in *PRF1* typically present with hemophagocytic lymphohistiocytosis (HLH) in infancy.⁵ HLH is a hyperinflammatory disorder characterized by unremitting fever, hepatosplenomegaly, hyperferritinemia, cytopenia, and sometimes hemophagocytosis and is diagnosed on the basis of fulfillment of at least five of eight clinical and laboratory criteria.^{6,7} Besides *PRF1*, mutations in genes required for exocytosis of perforin-containing vesicles may also present with HLH in infancy. For example, in addition to mutations in *PRF1*, familial HLH (FHL) has been associated with mutations in *UNC13D*, *STX11*, and *STXBP2*.⁸ Moreover, HLH is also associated with Griscelli syndrome type 2 and Chediak-Higashi syndrome caused by mutations in *RAB27A* and *LYST*,

respectively, which impair vesicle biogenesis and exocytosis.

So far, there are few data linking defects in cytotoxic lymphocyte exocytosis to development of hematologic malignancies. Here, we report the development of an Epstein Barr virus (EBV)-positive classical Hodgkin's lymphoma (cHL) in a patient in remission for HLH caused by biallelic mutations in *STXBP2*.

Design and Methods

Patients and controls

The studies were approved by the ethics committee at the Karolinska Institutet. Written consent was obtained from the patient.

Western blot analysis of Munc18-2 expression

Peripheral blood mononuclear cells (PBMC) from patients and healthy controls were lysed in lysis buffer (20 mM Tris, pH 7.4, 1 mM EDTA, 1% Triton X-100, 150 mM NaCl) with protease inhibitors (Roche). Cells were disrupted and centrifuged for 15 min at 14,000 g. Protein content was determined by the Bradford assay (Bio-Rad), and 50 µg protein was loaded per lane and analyzed using SDS-PAGE separation and Western blotting (NuPAGE, Invitrogen). The rabbit polyclonal antibodies to Munc18-2 (raised against amino acids 1-236) or Rab27a were used for Western blotting (both from Protein Technologies Group).

©2013 Ferrata Storti Foundation. This is an open-access paper. doi:10.3324/haematol.2012.073098

Manuscript received on June 27, 2012. Manuscript accepted on October 4, 2012.

Correspondence: Maciej.Machaczka@ki.se or Yenan.Bryceson@ki.se

Immunohistochemistry

Immunohistochemical stains were performed on deparaffinized tissue sections in a semi-automated manner with Bond Polymer Refine and Bond DAB Enhance on a Bond-Max stainer, as recommended by the manufacturer (Vision Biosystems, Leica Microsystems). Anti-CD3 (LN10, Novocastra), anti-CD8 (4B11, Novocastra), anti-CD15 (Carb-3, Dako), anti-CD20 (L26, Dako), anti-CD30 (1G12, Novocastra), anti-CD68 (PG-M1, Dako), anti-Bcl2 (3.1, Novocastra), anti-Ki67 (MIB-1, Dako), anti-PAX5 (1EW, Novocastra), anti-perforin (5B10, Novocastra), and anti-granzyme B (11F1, Novocastra) antibodies were used. Fluorescence *in situ* hybridization for EBV-encoded RNA (EBER) was also performed on a Bond-Max stainer, using fluorescein-conjugated oligonucleotide probes (EBER Probe, Leica Biosystems).

Functional assays

For assessment of NK cell-mediated cytotoxicity, a standard 4-h ^{51}Cr assay was used.⁹ A value below 10 LU was considered pathological.⁶ Cytotoxic lymphocyte exocytosis was assessed by flow cytometric quantification of CD107a surface expression on gated CD3⁺CD56⁺ natural killer (NK) and CD3⁺CD8⁺CD57⁺ effector T cells in response to incubation with different target cells, as previously described.¹⁰ To quantify responses to EBV, PBMC were mixed with synthetic peptides pools of LMP-1, BZLF-1, or EBNA-3A (all JPT Technologies), incubated for 6 h with GolgiPlug (BD Bioscience) added after 1 h, followed by extracellular staining of lineage markers and CD107a and intracellular staining of TNF- α . All samples were acquired on a LSR Fortessa cell analyzer (BD Biosciences) and analyzed using Flowjo 9.4 (Tree Star).

Results and Discussion

We have already detailed the clinical presentation of a 17-year old previously healthy girl carrying biallelic *STXBP2* mutations c.1294C>A (p.Gln432X) and

c.1634C>T (p.Ser545Leu).¹¹ The combination of the mutations causes a loss of Munc18-2 expression, the protein encoded by *STXBP2* (Figure 1). Briefly, the patient developed a life-threatening HLH triggered by a primary EBV infection and was successfully treated with immunochemotherapy according to a modification of the HLH-94 protocol.¹² Following treatment, the patient was administered intravenous immunoglobulin once a month due to hypogammaglobulinemia. Since completion of treatment, the patient remained in remission of HLH and did well.

At the age of 20 years, 45 months after the clinical presentation of HLH, the patient developed a rapidly progressive unilateral swelling of the neck (Figure 2A). The patient complained of malaise and drowsiness, but denied fever, sweating or weight loss. Computed ^{18}F -labeled fluorodeoxyglucose-positron emission tomography (^{18}F -FDG-PET) disclosed a localized lymphadenopathy (10×2×2 cm; Figure 2B). The patient underwent a partial surgical removal of affected cervical lymph nodes. Light microscopic examination of the tissue revealed morphological

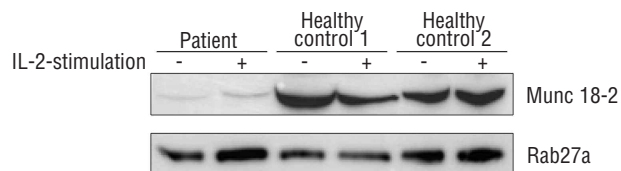


Figure 1. Munc18-2 expression in a patient with biallelic nonsense and missense *STXBP2* mutations. PBMC from the patient or 2 healthy controls, unstimulated or treated with 500 IU/mL IL-2 overnight, were lysed and protein content was analyzed by SDS-PAGE and Western blotting. Rabbit polyclonal antibodies for detection of Munc18-2 and Rab27a were used.

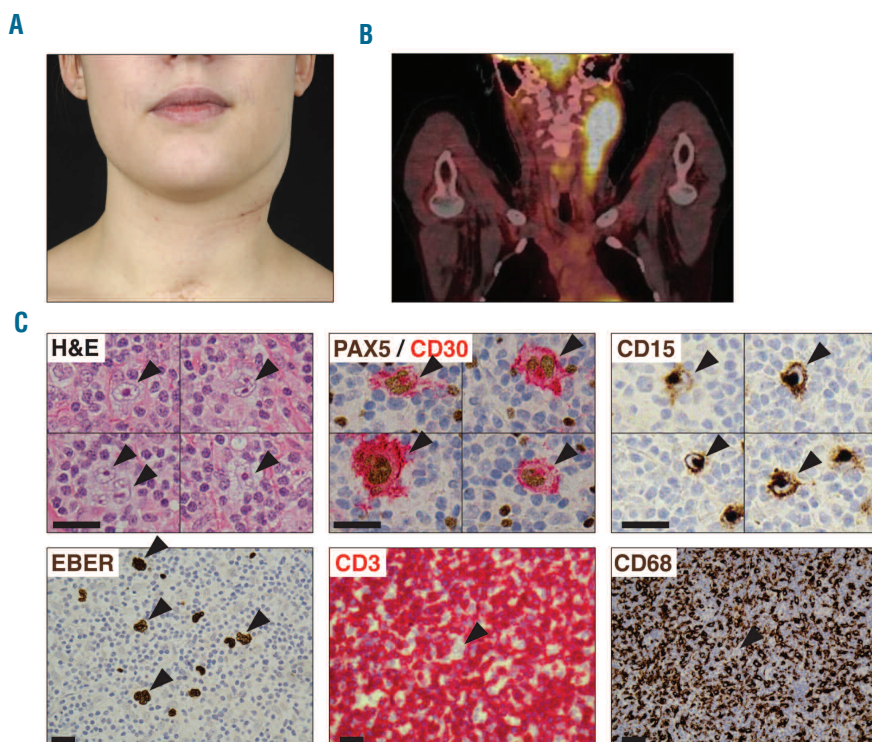


Figure 2. Hodgkin's lymphoma in a Munc18-2-deficient patient in remission for HLH. (A) Unilateral swelling of the left side of the neck. (B) Increase in FDG-uptake by pathological mass of the enlarged left cervical lymph nodes as revealed by a ^{18}F -FDG-PET/CT scan. (C) Diagnosis of classical Hodgkin's lymphoma of mixed cellularity by histological examination of left cervical lymph nodes. Panels show sections stained with hematoxylin and eosin (H&E), anti-PAX5 (brown) and anti-CD30 (red) antibodies, anti-CD15 antibody, *in situ* hybridization for EBV-encoded RNA (EBER), as well as anti-CD3 or anti-CD68 antibodies, as indicated. The arrowheads indicate malignant cells with HRS morphology.

structure effaced by lymphohistiocytic proliferation (Figure 2C). A population of dispersed, large atypical cells with Hodgkin-Reed-Sternberg (HRS) morphology could be identified (Figure 2C). These cells expressed PAX5,

CD15, CD30, and Ki67, transcribed EBER, but were negative for CD3, CD20, and ALK1 (Figure 2C and *data not shown*). Based on these findings, the patient was diagnosed with EBV⁺ cHL stage IA of mixed cellularity type. The

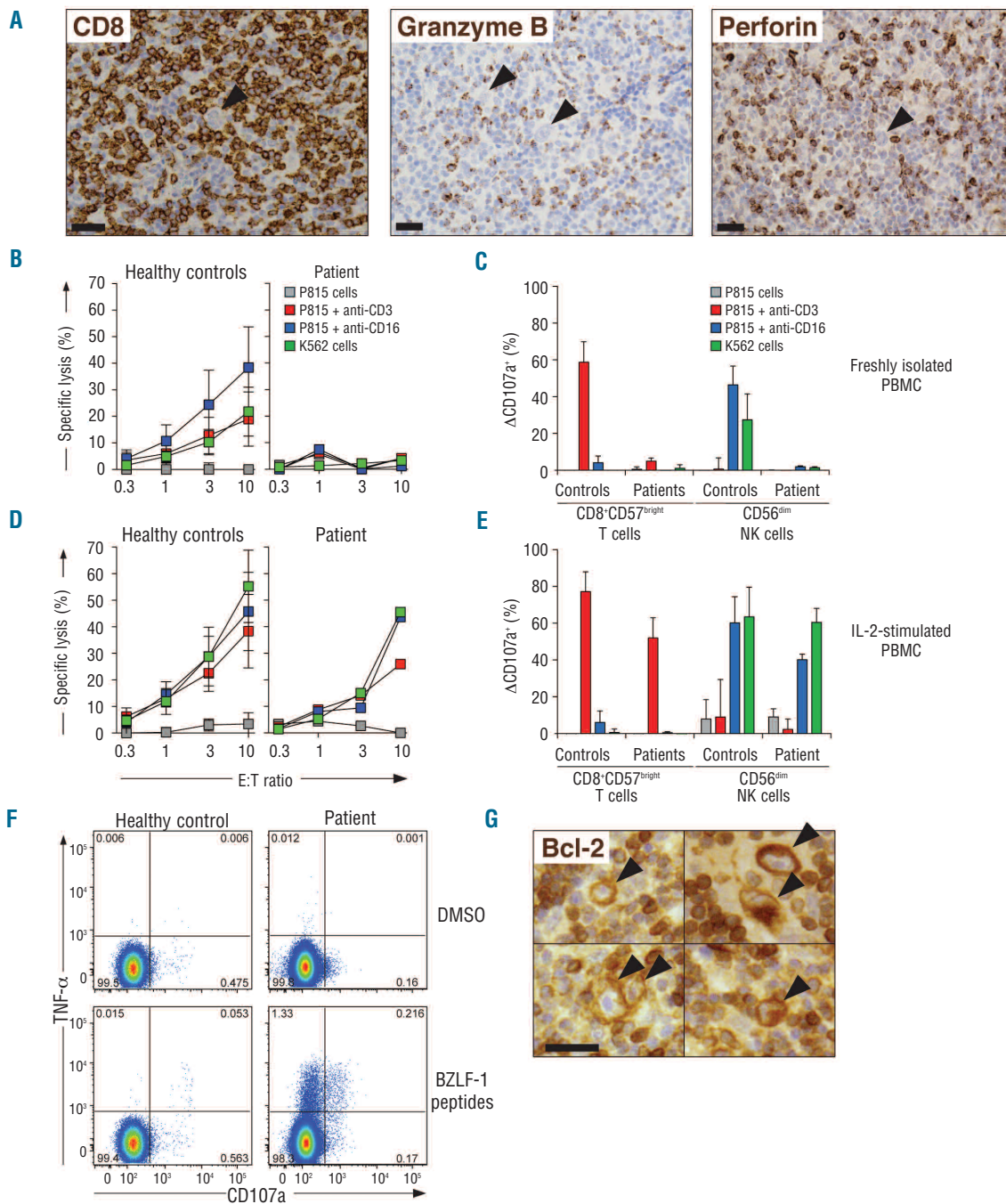


Figure 3. Characterization of tumor infiltrating cytotoxic T lymphocytes and evaluation of peripheral blood cytotoxic lymphocyte function in a Munc18-2-deficient patient. (A) Characterization of infiltrating lymphocytes by immunohistochemical examination of left cervical lymph nodes. Panels show sections stained with anti-CD8, anti-granzyme B, and anti-perforin antibodies, as indicated. (B-E) The arrowheads indicate malignant cells. (B) Defective exocytosis and cytotoxicity by CTL and NK cells. Freshly isolated or (D) IL-2-stimulated PBMC were mixed with ⁵¹Cr-labeled target cells as indicated. Specific lysis was calculated after 4 h of stimulation. Values represent the mean of 10 healthy, age-matched controls as well as the patient. Bars indicate the SD. One representative experiment of 3 is shown. (C) Freshly isolated or (E) IL-2-stimulated PBMC were mixed with target cells as indicated. Surface expression of CD107a was quantified after 3 h of stimulation on CTL or NK cells. Values represent the mean of 30 healthy controls and 4 repeat samples of the patient. Bars indicate the SD. (F) PBMC from a healthy donor or the patient were mixed with synthetic peptides to the EBV protein BZLF-1 and stimulated for 6 h. Plots display CD107a and TNF- α expression on CD8⁺ T cells. (G) Expression of the tumor oncogene Bcl-2 in HRS cells. Panels show sections stained with an anti-Bcl-2 antibody. The arrowheads indicate malignant cells.

accompanying population of small lymphocytes was dominated by CD8⁺ T cells (Figures 2C and 3A). Remarkably, spleen size was within normal limits and the patient did not fulfill clinical HLH criteria at the time of the cHL diagnosis (hemoglobin 139 g/L; platelets 202×10⁹/L; neutrophils 1.6×10⁹/L; ferritin 23 µg/L; fasting triglycerides 0.79 mmol/L; fibrinogen 1.8 g/L; sCD25 631 U/mL). Quantification of EBV in serum revealed only 50-500 copies/mL. One course of standard adriamycin, bleomycin, vinblastine, and dacarbazine (ABVD) chemotherapy resulted in complete remission, as documented clinically and by ¹⁸F-FDG-PET. The patient completed four courses of ABVD and local radiotherapy, followed by allogeneic hematopoietic stem cell transplantation (HSCT).

Experimental models have indicated important roles for NK and γδ T cells in perforin-mediated control of B-cell lymphomas.¹⁵ Moreover, human tonsillar NK cells can restrict EBV-mediated transformation though IFN-γ production.¹⁴ However, in our patient, among tumor infiltrating lymphocytes, very few CD56⁺ cells were observed, whereas CD3⁺ and CD8⁺ cells were abundant, with many expressing granzyme B and/or perforin (Figure 2C,3A, and *data not shown*). Thus, the immunological response to the lymphoma cells appeared to be dominated by cytotoxic T cells (CTLs). Experimental models have shown a central role for CD8⁺ T cells in protective immunity to EBV.^{15,16} Longitudinal analyses of lymphocyte cytotoxicity in the patient demonstrated an absence of exocytosis and cytotoxicity by both CTL and NK cells (Figure 3B,C), which was partially restored by IL-2 stimulation (Figure 3D,E). Relative to a healthy control, EBV-specific T cells in the patient produced TNF-α, but displayed impaired degranulation in response to BZLF-1 peptides (Figure 3F). Compared to healthy controls, in whom 78% of the TNF-α⁺ CD8⁺ T cells also were CD107a⁺, only 14% of the TNF-α⁺ CD8⁺ T cells were CD107a⁺ in our patient. By comparison, peptide pools of EBNA-3A or LMP-1 did not elicit significant T-cell responses in the patient (*data not shown*). Of note, mouse models indicate tumor immunogenicity is dictated by oncogene expression.^{17,18} Whereas overexpression of Myc or loss of p53 does not confer immunogenicity, overexpression of Bcl-2 does. cHL cells in our patient expressed Bcl-2 (Figure 3G), possibly reflecting impaired immunological sculpting.¹⁷⁻¹⁹

In summary, the present patient suggests the possibility of an association of hypomorphic *STXBP2* mutations with lymphoma. The cumulative dose of etoposide received during HLH-therapy was low (0.2 g/m²). Furthermore, etoposide-induced malignancies are typically myeloid-derived.²⁰ Thus, impaired immunosurveillance of EBV-infected and transformed cells is a plausible cause of cHL in our patient.²¹ Notably, we have previously reported development of acute myeloid leukemia and myelodysplastic syndrome in 2 *STX11*-deficient patients who received 3.1 and 23.9 g/m² of etoposide/teniposide,

respectively, so these malignancies could also be secondary to chemotherapy.²² Strengthening the notion of a causal link between defective exocytosis and lymphoma, Pagel and colleagues recently reported a patient homozygous for a c.1247-1G>C splice error mutation in *STXBP2* who initially presented with cHL stage IIIB and HLH features at the age of nine years.²³ The patient was successfully treated for lymphoma, but an HLH relapse occurred at the age of ten years. Thus, similar to what has been reported in patients with biallelic mutations in *PRF1* or *LYST*, which both impair lymphocyte cytotoxicity,^{3,4,24} patients with severe biallelic mutations in *STXBP2* that abrogate exocytosis most likely present with HLH in infancy, whereas patients with hypomorphic mutations may present with hematologic malignancies later in life. Notably, the present patient did not manifest HLH at the time of lymphoma development. Therefore, studies of the frequencies of mutations in FHL-associated genes are warranted in lymphoma patients. An interesting question is whether mutations in certain FHL-associated genes more strongly predispose to development of lymphoma than others. Although the genes are all required for lymphocyte cytotoxic function, *PRF1* mutations do not prevent release of granzymes and other granule constituents, whereas mutations in *UNC13D*, *STXBP2*, and *STX11* do. Whereas perforin-deficiency specifically impairs lymphocyte cytotoxicity, the latter genes also affect other exocytic, but non-cytotoxic, functions of diverse immune cells, as well as platelets. This may have consequences for susceptibility to lymphoma development.

These findings have important clinical implications. Allogeneic hematopoietic stem cell transplantation (HSCT) represents the only cure for FHL. The cumulative risk of HLH and malignancies should be taken into consideration when determining whether to perform HSCT. We, therefore, currently favor HSCT in patients with defined disease-causing mutations in FHL genes. A molecular diagnosis may be difficult to obtain in some patients, e.g. due to non-coding aberrations.²⁵ In this setting, reproducible defects in cytotoxic lymphocyte function also may warrant HSCT.

Acknowledgments

We thank Hans-Gustaf Ljunggren for insightful discussions and suggestions regarding the manuscript. This work was supported by the Swedish Research Council, Swedish Cancer Foundation, Swedish Children's Cancer Foundation, Histiocytosis Association, Clas Groschinsky's Memorial Fund, Jeansson's Foundation, Åke Olsson Foundation for Hematological Research, Åke Wiberg Foundation, Karolinska Institute Research Foundation, and the Stockholm County Council (ALF project).

Authorship and Disclosures

Information on authorship, contributions, and financial & other disclosures was provided by the authors and is available with the online version of this article at www.haematologica.org.

References

- Vesely MD, Kershaw MH, Schreiber RD, Smyth MJ. Natural Innate and Adaptive Immunity to Cancer. *Annu Rev Immunol*. 2011;29:235-71.
- Smyth MJ, Thia KY, Street SE, MacGregor D, Godfrey DI, Trapani JA. Perforin-mediated cytotoxicity is critical for surveillance of spontaneous lymphoma. *J Exp Med*. 2000;192(5):755-60.
- Clementi R, Locatelli F, Dupre L, Garaventa A, Emmi L, Bregni M, et al. A proportion of patients with lymphoma may harbor mutations of the perforin gene. *Blood*. 2005;105(11):4424-8.
- Chia J, Yeo KP, Whisstock JC, Dunstone MA, Trapani JA, Voskoboinik I. Temperature sensitivity of human perforin mutants unmasks subtotal loss of cytotoxicity, delayed FHL, and a predisposition to cancer. *Proc Natl Acad Sci USA*. 2009;106(24):9809-14.
- Stapp SE, Dufourcq-Lagelouse R, Le Deist F, Bhawan S, Certain S, Mathew PA, et al. Perforin gene defects in familial hemo-

- phagocytic lymphohistiocytosis. *Science*. 1999;286(5446):1957-9.
6. Henter JL, Home A, Arico M, Egeler RM, Filipovich AH, Imashuku S, et al. HLH-2004: Diagnostic and therapeutic guidelines for hemophagocytic lymphohistiocytosis. *Pediatr Blood Cancer*. 2007;48(2):124-31.
 7. Janka GE. Familial and acquired hemophagocytic lymphohistiocytosis. *Annu Rev Med*. 2012;63:233-46.
 8. Pachlopnik Schmid J, Cote M, Menager MM, Burgess A, Nehme N, Menasche G, et al. Inherited defects in lymphocyte cytotoxic activity. *Immunol Rev*. 2010;235(1): 10-23.
 9. Bryceson YT, Rudd E, Zheng C, Edner J, Ma D, Wood SM, et al. Defective cytotoxic lymphocyte degranulation in syntaxin-11 deficient familial hemophagocytic lymphohistiocytosis 4 (FHL4) patients. *Blood*. 2007;110(6):1906-15.
 10. Chiang SC, Theorell J, Entesarian M, Meeths M, Mastafa M, Al-Herz W, et al. Comparison of primary human cytotoxic T-cell and natural killer cell responses reveal similar molecular requirements for lytic granule exocytosis but differences in cytokine production. *Blood*. 2013; 121(8):1345-56.
 11. Meeths M, Entesarian M, Al-Herz W, Chiang SC, Wood SM, Al-Ateeqi W, et al. Spectrum of clinical presentations in familial hemophagocytic lymphohistiocytosis (FHL) type 5 patients with mutations in STXBP2. *Blood*. 2010;116(15):2635-43.
 12. Trottestam H, Home A, Arico M, Egeler RM, Filipovich AH, Gadner H, et al. Chemoimmunotherapy for hemophagocytic lymphohistiocytosis: long-term results of the HLH-94 treatment protocol. *Blood*. 2011;118(17):4577-84.
 13. Street SE, Hayakawa Y, Zhan Y, Lew AM, MacGregor D, Jamieson AM, et al. Innate immune surveillance of spontaneous B cell lymphomas by natural killer cells and gamma-delta T cells. *J Exp Med*. 2004;199(6): 879-84.
 14. Strowig T, Brilot F, Arrey F, Bougras G, Thomas D, Muller WA, et al. Tonsillar NK cells restrict B cell transformation by the Epstein-Barr virus via IFN-gamma. *PLoS Pathog*. 2008;4(2):e27.
 15. Strowig T, Gurer C, Ploss A, Liu YF, Arrey F, Sashihara J, et al. Priming of protective T cell responses against virus-induced tumors in mice with human immune system components. *J Exp Med*. 2009;206(6):1423-34.
 16. Zhang B, Kracker S, Yasuda T, Casola S, Vanneman M, Homig-Holzel C, et al. Immune surveillance and therapy of lymphomas driven by Epstein-Barr virus protein LMP1 in a mouse model. *Cell*. 2012; 148(4):739-51.
 17. Bolitho P, Street SE, Westwood JA, Edelmann W, Macgregor D, Waring P, et al. Perforin-mediated suppression of B-cell lymphoma. *Proc Natl Acad Sci USA*. 2009; 106(8):2723-8.
 18. Schuster C, Berger A, Hoelzl MA, Putz EM, Frenzel A, Simma O, et al. The cooperating mutation or "second hit" determines the immunologic visibility toward MYC-induced murine lymphomas. *Blood*. 2011; 118(17):4635-45.
 19. Koebel CM, Vermi W, Swann JB, Zerafa N, Rodig SJ, Old LJ, et al. Adaptive immunity maintains occult cancer in an equilibrium state. *Nature*. 2007;450(7171):903-7.
 20. Imashuku S. Etoposide-related secondary acute myeloid leukemia (t-AML) in hemophagocytic lymphohistiocytosis. *Pediatr Blood Cancer*. 2007;48(2):121-3.
 21. Kutok JL, Wang F. Spectrum of Epstein-Barr virus-associated diseases. *Annu Rev Pathol*. 2006;1:375-404.
 22. Rudd E, Goransdotter Ericson K, Zheng C, Uysal Z, Ozkan A, Gurgey A, et al. Spectrum and clinical implications of syntaxin 11 gene mutations in familial haemophagocytic lymphohistiocytosis: association with disease-free remissions and haematopoietic malignancies. *J Med Genet*. 2006;43(4):e14.
 23. Pagel J, Beutel K, Lehmborg K, Koch F, Maul-Pavicic A, Rohlf AK, et al. Distinct mutations in STXBP2 are associated with variable clinical presentations in patients with familial hemophagocytic lymphohistiocytosis type 5 (FHL5). *Blood*. 2012;119 (25):6016-24.
 24. Roder JC, Haliotis T, Klein M, Korec S, Jett JR, Ortaldo J, et al. A new immunodeficiency disorder in humans involving NK cells. *Nature*. 1980;284(5756):553-5.
 25. Meeths M, Chiang SC, Wood SM, Entesarian M, Schlums H, Bang B, et al. Familial hemophagocytic lymphohistiocytosis type 3 (FHL3) caused by deep intronic mutation and inversion in UNC13D. *Blood*. 2011;118(22):5783-93.