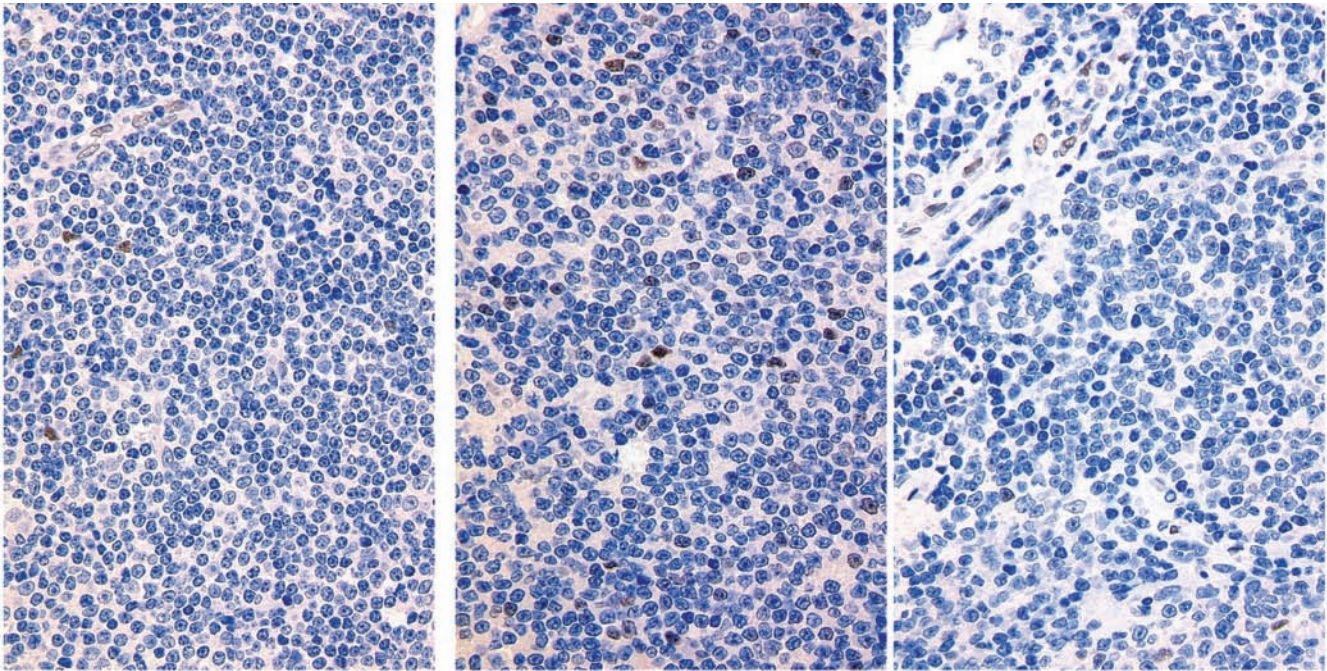


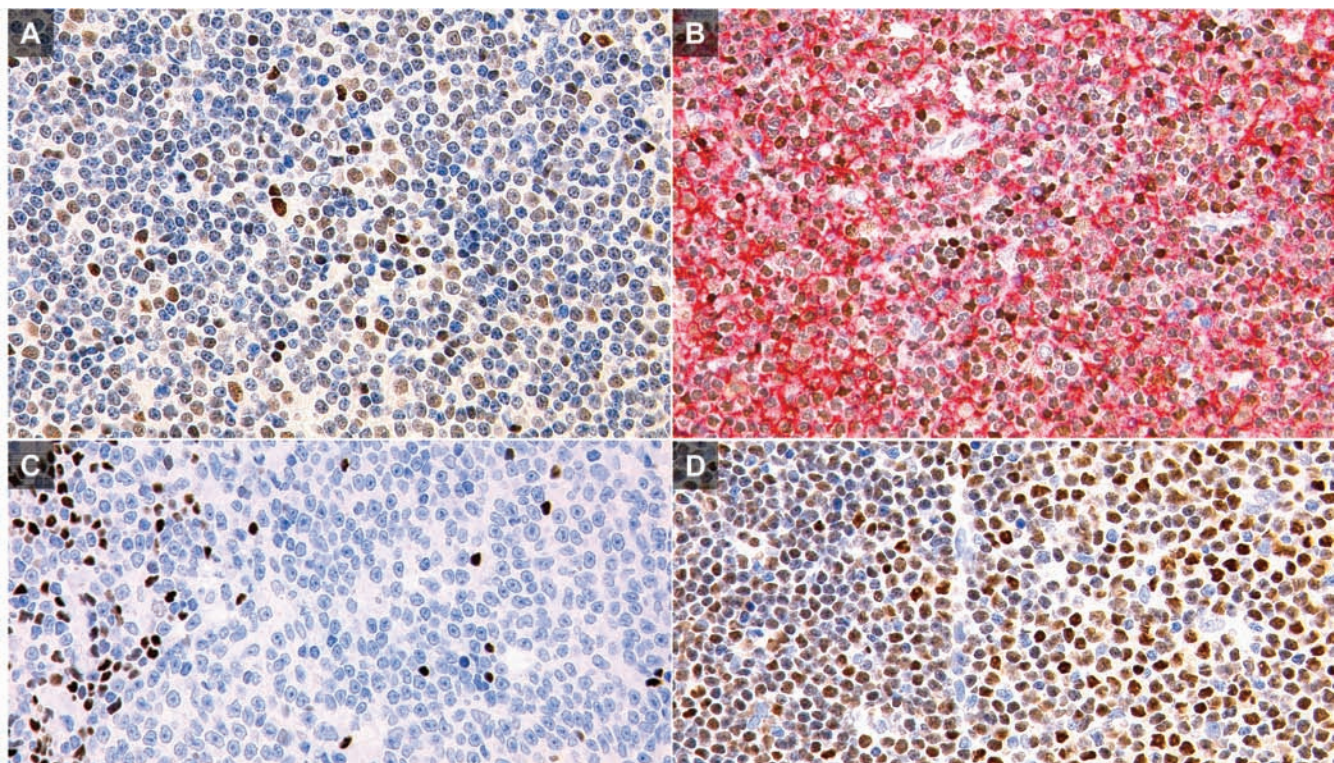
## A low-grade B-cell lymphoma with polymphocytic/ paraimmunoblastic proliferation and *IRF4* rearrangement

Kengo Takeuchi,<sup>1,2</sup> Seiji Sakata,<sup>1</sup> Reimi Asaka,<sup>1,2</sup> Naoko Tsuyama,<sup>2</sup> Akito Dobashi,<sup>1</sup> Masaaki Noguchi<sup>3</sup>

doi:10.3324/haematol.2012.076851



Online Supplementary Figure S1. LMO2: case 1 (left), case 2 (center and right) 40x objective.



Online Supplementary Figure S2. LEF1 In case 1, the lymphoma cells were weakly positive for LEF1 [(A) 40x objective]. The staining intensity was lower than that of reactive T cells. (B) LEF1: brown; CD20: red. 40x objective). The lymphoma cells in case 2 were negative for LEF1. [(C) 40x objective]. The cells of small lymphocytic lymphoma [(D) Positive control. 40x objective] were positive for LEF1, more intensely in proliferation center cells (upper right).