

## Dendritic cell, monocyte, B and NK lymphoid deficiency defines the lost lineages of a new GATA-2 dependent myelodysplastic syndrome

Venetia Bigley and Matthew Collin

Institute of Cellular Medicine, Newcastle University, UK. E-mail: matthew.collin@ncl.ac.uk doi:10.3324/haematol.2011.048355

(Related Original Article on page 1221)

A novel immunodeficiency syndrome has recently been defined in young adults. Known variously as dendritic cell, monocyte, B and NK lymphoid (DCML deficiency),<sup>1</sup> ‘autosomal dominant and sporadic monocytopenia’<sup>2</sup> or ‘MonoMAC’ (monocytopenia with *Mycobacterium avium* complex),<sup>3</sup> it is characterized by a composite mononuclear cell deficiency, atypical mycobacterial and viral infection, and progression to myelodysplasia and leukemia. Strikingly, a number of patients also develop pulmonary alveolar proteinosis (PAP). Patients typically present in their 3<sup>rd</sup> or 4<sup>th</sup> decade, although historical blood counts may show pre-existing monocytopenia for ten years or more. A substantial number of patients develop autoimmune phenomena such as erythema nodosum/panniculitis or arthritis. Solid tumors are common, notably carcinoma *in situ* associated with chronic infection with human papilloma virus. Up to a third of cases have a family history with apparent autosomal dominant inheritance. Left untreated, many will die from infection, leukemia or respiratory failure. Loss of dendritic cells (DCs), monocytes and B/NK lymphoid cells is universal, hence the term DCML deficiency to describe this syndrome. Infection with *Mycobacterium avium* complex, alluded to in the term ‘MonoMAC’, is seen in the majority of patients but not all.

DCML deficiency/MonoMAC was first described by Steven Holland and colleagues at the National Institutes of Health, in a paper published in the journal *Blood* in 2010.<sup>2</sup> A smaller group of subjects were also described earlier this year in a report highlighting the loss of dendritic cells and specific deletion of bone marrow progenitor subsets. This study also demonstrated a marked increase in Flt-3 ligand and loss of regulatory T cells (Tregs).<sup>1</sup> As this article went to press, the genetic basis was solved in two papers which are shortly to be published in the journal *Blood*. *GATA-2* mutation has been found in nearly all cases, first in a candidate gene study from the Holland group<sup>4</sup> and second by exome sequencing of 4 unrelated patients.<sup>5</sup> In this issue of the journal, Calvo *et al.* from the Holland group take a more in depth look at the hematologic features as bone marrow failure progresses, providing evidence that DCML deficiency/MonoMAC inevitably becomes a more recognizable yet distinct form of myelodysplasia (MDS).<sup>3</sup> A model of the pathogenesis of this disorder incorporating these new findings is presented in Figure 1.

Through this careful description, Calvo and colleagues show clearly that advanced DCML deficiency overlaps with MDS; 61%-78% of their patients had an additional cytopenia and nearly half (39%) were pancytopenic. More than half (59%) also had cytogenetic abnormalities, most commonly monosomy 7/7q deletion, trisomy 8 and trisomy 1. The study subjects are necessarily a more advanced group of patients than previously reported as the inclusion criteria were defined as both a diagnosis of ‘MonoMAC’ and the development of “additional cytopenia(s) typically associated with MDS”. The combination of cytopenias and cytogenetics gave 15 of 18 patients intermediate to high scores according to the MDS

International Prognostic Scoring System (IPSS).

It is worth emphasizing at this point that DCML deficiency patients may have significant risk to their health before additional cytopenias evolve.<sup>2</sup> Disseminated mycobacterial infection, PAP and carcinoma *in situ* may all occur prior to the onset of an obvious myelodysplastic syndrome, underscoring the fact that immunodeficiency is a cardinal feature of the disorder. In the series of 4 subjects described in 2011, one had mild anemia (10.3 g/dL) and one mild thrombocytopenia ( $123 \times 10^9/L$ ), yet 2 required hematopoietic stem cell transplantation (one for refractory mycobacterial infection, one for PAP) and a third died of influenza H1N1 prior to transplantation.<sup>1</sup> In addition, many other factors may contribute to mild cytopenias, including: atypical mycobacterial infection, respiratory failure, autoimmune thrombocytopenia and hemolysis, and drug therapy.

The second finding from the current study is that although DCML deficiency can progress to a form of MDS as defined by standard criteria, it has some very particular and unusual features that make it distinct from typical MDS. The main diagnostic features are summarized in Table 1. Important

**Table 1. Diagnostic criteria for DCML deficiency/MonoMAC.**

History
Warts and carcinoma <i>in situ</i> <sup>1</sup>
Atypical mycobacterial infection
Respiratory failure <sup>2</sup>
Family history of chest disease/leukemia
Routine tests
Blood count: monocytopenia <sup>3</sup>
Lymphocyte subsets: B cell and NK cell deficiency
Normal immunoglobulins
Bone marrow:
megakaryocyte dysplasia (100%)
normo/hypocellularity (89%)
fibrosis (73%)
Further investigations
Blood:
absolute blood DC deficiency
elevated Flt-3 ligand (10-100 fold)
loss of peripheral Tregs
BM:
loss of MLP and reduction of GMP in BM CD34 <sup>+</sup> compartment
preservation of BM macrophages
CD56 <sup>+</sup> plasma cells present
Lungs:
pulmonary alveolar proteinosis without GM-CSF antibodies

<sup>1</sup>Associated with HPV and reduced mononuclear infiltrates; <sup>2</sup>may be a complex of atypical infection and PAP; <sup>3</sup>median  $0.01 \times 10^9/L$  compared with  $0.07 \times 10^9$  in hairy cell leukemia.

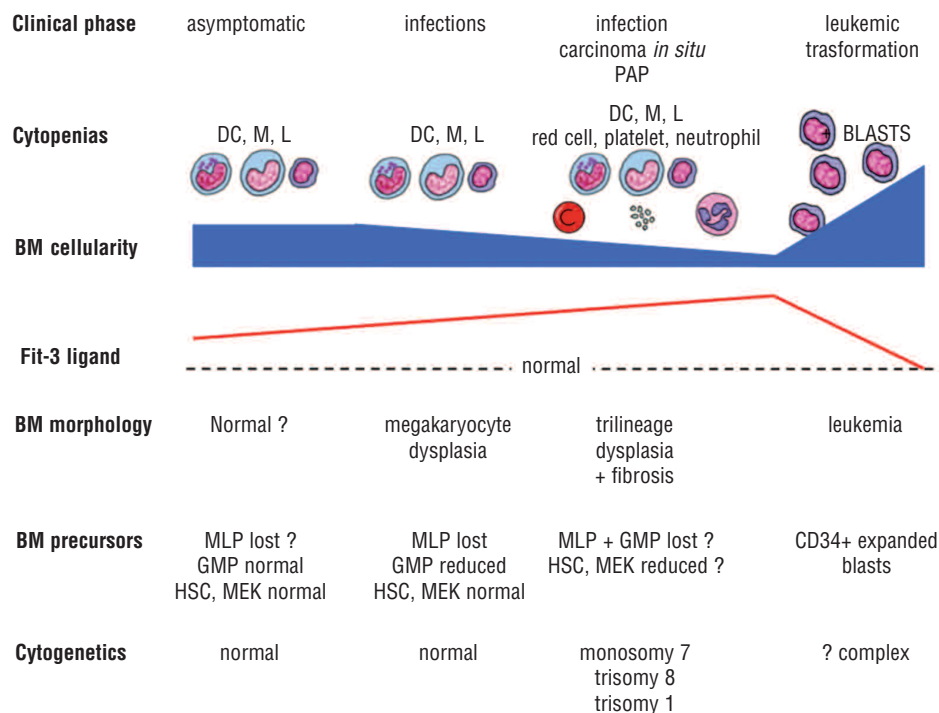
clues are often present in patients' case history such as a much younger age at presentation and longstanding problems with warts or poorly characterized autoimmune phenomena. Atypical infection, respiratory failure, cytopenias and family history are much stronger warnings that this is not typical MDS.

The most obvious laboratory finding is, of course, the loss of mononuclear cells: the 'lost lineages' of a failing marrow that are not recognized by the standard definitions of 'trilineage dysplasia'. In particular, it should be easy to identify monocytopenia from the usual monocytosis of sporadic MDS. It is important to note that monocytopenia may be the only deficit to be seen from automated counting because the loss of B cells and NK cells is masked by preservation of peripheral T cells. DCML deficiency has now earned its place in the textbook alongside hairy cell leukemia, as a differential diagnosis of monocytopenia. Vinh *et al.* previously observed that the monocyte deficit is usually much more profound in DCML deficiency than hairy cell leukemia ( $0.01 \times 10^9/L$  compared with  $0.07 \times 10^9/L$ ). It is also vital to recognize that patients may present to a number of different medical specialities, including genito-urinary medicine, infectious disease, respiratory medicine and rheumatology, and that failure to recognize monocytopenia in this context is likely to result in a missed diagnosis.

Calvo and colleagues present very convincing additional diagnostic findings that separate DCML deficiency from typical MDS. In most cases, megakaryocytes are dysplastic, even in the absence of thrombocytopenia, and there is a high rate of fibrosis (73%). Bone marrow cellularity tends to be normal or low (89%), even when additional cytopenias have begun to evolve; it is only the very advanced

leukemic phases in which cellularity finally begins to increase and become more like typical proliferative MDS. In the description of DCML deficiency, the elevation of Flt-3 ligand was highlighted.<sup>1</sup> Although this has been described in aplastic anemia,<sup>6</sup> it is not a typical feature of MDS and might become a useful measurement. The progenitor cell compartment was also characterized in detail showing selective loss of the multi-lymphoid progenitor (MLP), a recently described pluripotent cell which appropriately gives rise to DC, monocytes and lymphoid cells.<sup>7</sup> Granulocyte macrophage progenitors (GMP) are also depleted but are present in sufficient numbers to sustain granulopoiesis in the early phase of the disease. All these observations point to the mechanism of pathogenesis being an intrinsic stem cell defect that preferentially affects mononuclear cell production before progressing to global hematopoietic failure. This mechanism has now been confirmed by the discovery of *GATA-2* mutations which are likely to compromise stem cell survival and are also known to affect the formation of GMP, monocytes, B cells and NK cells in murine models of haplo-insufficiency.<sup>8,9</sup>

The evaluation of lung disease in DCML deficiency is also very important. Mycobacterial infection may promote the pathogenesis, yet also obscure the diagnosis, of underlying PAP. The critical test in DCML deficiency is that GM-CSF antibodies are not detected and there is no response to administration of GM-CSF, unlike most cases of acquired PAP.<sup>10</sup> Physicians evaluating respiratory problems define the PAP of DCML deficiency as 'secondary' to bone marrow failure, although this is not as straightforward as it appears.<sup>11</sup> Unexpectedly, tissue macrophages, including alveolar macrophages are present in normal numbers, despite the profound monocytopenia.<sup>12</sup> There is specula-



**Figure 1.** Evolution of DCML deficiency/MonoMAC. Schematic representation of the evolution of DCM deficiency beginning with an asymptomatic phase of cellular deficiency gradually evolving probably in the first decade of life. Infections begin in the second and third decade followed by increasing risk of carcinoma related to HPV, respiratory complications and finally overt leukemic transformation. BM cellularity declines and Flt-3 ligand probably rises in an inverse relationship until the proliferative phase of MDS occurs. This coincides with the acquisition of cytogenetic abnormalities and onset of cytopenias. MLP: multi-lymphoid progenitor; GMP: granulocyte-macrophage progenitor; HSC: hematopoietic stem cell; MEK megakaryocyte/erythroid progenitor.

tion about whether alveolar macrophages survive for very long periods, proliferate locally or are even derived from sources other than monocytes, but the fact remains that the resident cells in DCML deficiency must be defective in function rather than simply depleted in number. In support of this, there is evidence that GATA-2 plays a role in phagocytosis.<sup>12</sup> Case reports of secondary PAP in the context of monocytopenia or MDS have been known for a number of years and were very well reviewed in the original paper on DCML deficiency by Vinh *et al.*<sup>2</sup>

The new study by Calvo *et al.* is very informative about the later stages of bone marrow failure in DCML deficiency but also provides a framework for conceptualizing the entire evolution of the syndrome. Most patients have survived childhood vaccination and viral illness without incident and at presentation have specific anti-viral titres and normal levels of immunoglobulin. Calvo *et al.* also show plasma cells in the bone marrow and highlight the relative preservation of peripheral T cells, although there are interesting abnormalities of phenotype in both. Together, these observations suggest that immunity was intact in infancy allowing some B- and T-cell memory to form. Indeed, in the original case series, normal blood counts were found in one child in infancy, prior to the onset of atypical infection.<sup>2</sup>

Unravelling the genetic basis of this disorder is important to provide confirmatory testing for families with affected individuals and links DCML deficiency to a group of hereditary leukemias described in a third independent study.<sup>13</sup> In terms of therapy, the NIH group has already led the way, showing that hematopoietic stem cell transplantation is potentially curative, and can be performed even on patients with advanced respiratory failure, so rapid is the correction of the alveolar macrophage defect. It is very likely that many more cases exist, probably a pedigree or a number of sporadic cases in every major city. The discovery and successful treatment of these patients will depend upon the recognition of monocytopenia as the vital clue in revealing the many guises of DCML deficiency.

*Venetia Bigley is George Walker Fellow in Haematology at Newcastle University and Honorary Consultant Haematologist at Newcastle upon Tyne Hospitals, UK. Matthew Collin is Professor*

*of Hematology at Newcastle University and Honorary Consultant Hematologist at Newcastle upon Tyne Hospitals, UK. Financial and other disclosures provided by the author using the ICMJE (www.icmje.org) Uniform Format for Disclosure of Competing Interests are available with the full text of this paper at www.haematologica.org.*

## References

1. Bigley V, Haniffa M, Doulatov S, Wang XN, Dickinson R, McGovern N, et al. The human syndrome of dendritic cell, monocyte, B and NK lymphoid deficiency. *J Exp Med.* 2011;208(2):227-34.
2. Vinh DC, Patel SY, Uzel G, Anderson VL, Freeman AF, Olivier KN, et al. Autosomal dominant and sporadic monocytopenia with susceptibility to mycobacteria, fungi, papillomaviruses, and myelodysplasia. *Blood.* 2010;115(8):1519-29.
3. Calvo KR, Vinh DC, Maric I, Wang W, Noel P, Stetler-Stevenson M, et al. Myelodysplasia in autosomal dominant and sporadic monocytopenia immunodeficiency syndrome: diagnostic features and clinical implications. *Haematologica.* 2011;96(8):1221-5.
4. Hsu AP, Sampaio EP, Khan J, Calvo KR, Lemieux JE, Patel SY, et al. Mutations in GATA2 are associated with the autosomal dominant and sporadic monocytopenia and mycobacterial infection (MonoMAC) syndrome. *Blood.* 2011 Jun 13. [Epub ahead of print]
5. Dickinson RE, Griffin H, Bigley V, Reynard LN, Hussain R, Haniffa M, et al. Exome sequencing identifies GATA-2 mutation as the cause of dendritic cell, monocyte, B and NK lymphoid deficiency. *Blood* 2011; 15:06-360313
6. Koijima S. Hematopoietic growth factors and marrow stroma in aplastic anemia. *Int J Hematol.* 1998;68(1):19-28.
7. Doulatov S, Notta F, Eppert K, Nguyen LT, Ohashi PS, Dick JE. Revised map of the human progenitor hierarchy shows the origin of macrophages and dendritic cells in early lymphoid development. *Nat Immunol.* 2010;11(7):585-93.
8. Rodrigues NP, Janzen V, Forkert R, et al. Haploinsufficiency of GATA-2 perturbs adult hematopoietic stem-cell homeostasis. *Blood.* 2005;106(2):477-84.
9. Rodrigues NP, Boyd AS, Fugazza C, May GE, Guo Y, Tipping AJ, et al. GATA-2 regulates granulocyte-macrophage progenitor cell function. *Blood.* 2008;112(13):4862-73.
10. Sakagami T, Uchida K, Suzuki T, Carey BC, Wood RE, Wert SE, et al. Human GM-CSF autoantibodies and reproduction of pulmonary alveolar proteinosis. *N Engl J Med.* 2009;361(27):2679-81.
11. Carey B, Trapnell BC. The molecular basis of pulmonary alveolar proteinosis. *Clin Immunol.* 2010;135(2):223-35.
12. Lasbury ME, Tang X, Durant PJ, Lee CH. Effect of transcription factor GATA-2 on phagocytic activity of alveolar macrophages from *Pneumocystis carinii*-infected hosts. *Infect Immun.* 2003;71(9):4943-52.
13. Scott HS, Hanh CN, Carmichael CL, Wilkins EJ, Chong C-E et al. GATA2 is a new predisposition gene for familial myelodysplastic syndrome (MDS) and acute myeloid leukaemia (AML). *ASH Annual Meeting Abstracts* 2010. 2010;116:21.

## Allogeneic stem cell transplantation for adult acute lymphoblastic leukemia: when and how

**Josep-Maria Ribera**

*Clinical Hematology Department, ICO-Hospital Germans Trias i Pujol, Josep Carreras Leukemia Research Institute, Universitat Autònoma de Barcelona, Spain. E-mail: jribera@iconcologia.net doi:10.3324/haematol.2011.0483480*

*(Related Original Article on page 1113)*

**A**llogeneic hematopoietic stem cell transplantation (HSCT) with a myeloablative conditioning regimen is considered the most potent post-remission antileukemic therapy in adult acute lymphoblastic leukemia (ALL).<sup>1,2</sup> However, an adequate balance should be established between its curative potential, the disadvantages (transplant-related mortality, late complications and reduced quality of life) and the improved outcome of the current chemotherapy regimens.<sup>3-7</sup> Large prospective

trials,<sup>8</sup> several meta-analyses of randomized trials<sup>9,10</sup> and modeling studies<sup>11</sup> have concluded that allogeneic HSCT with myeloablative conditioning is of benefit for high-risk adult patients in first complete remission. The benefit of HSCT in patients with standard-risk features is controversial. Although the largest randomized trial in adult ALL so far showed a significant advantage of HSCT in patients with standard-risk-ALL,<sup>8</sup> the results of the current pediatric-inspired protocols are better than those from the