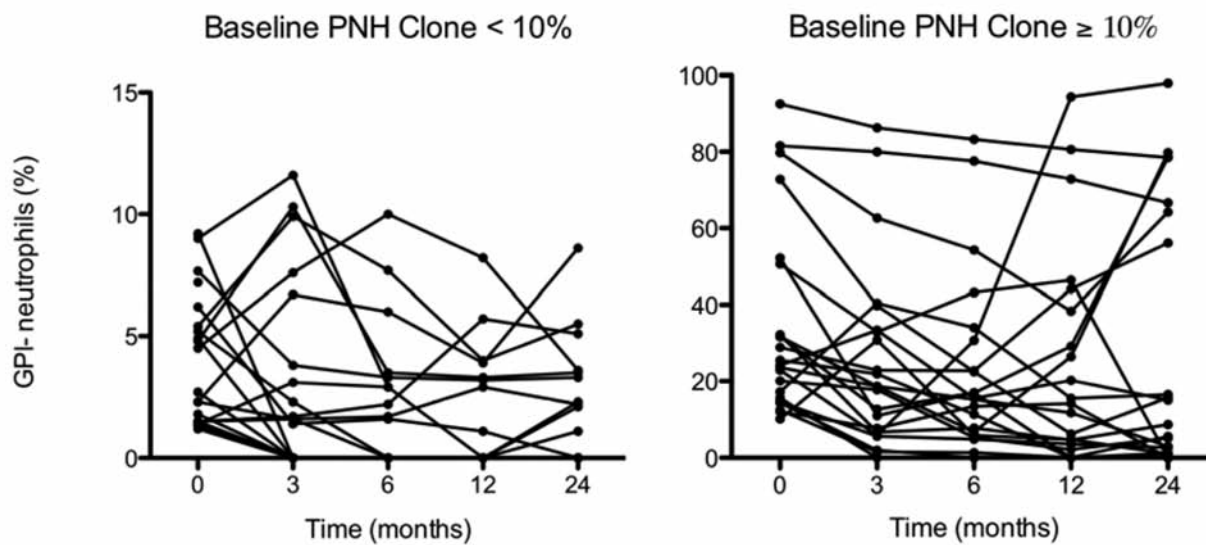


# Paroxysmal nocturnal hemoglobinuria clones in severe aplastic anemia patients treated with horse anti-thymocyte globulin plus cyclosporine

Phillip Scheinberg,<sup>1</sup> Michael Marte,<sup>2</sup> Olga Nunez,<sup>1</sup> and Neal S. Young<sup>1</sup>

<sup>1</sup>Hematology Branch, National Heart, Lung and Blood Institute, National Institutes of Health, Bethesda, and <sup>2</sup>Hematology-Oncology Service, Walter Reed Army Medical Center, Washington, USA

Citation: Scheinberg P, Marte M, Nunez O, and Young NS. Paroxysmal nocturnal hemoglobinuria clones in severe aplastic anemia patients treated with horse anti-thymocyte globulin plus cyclosporine. *Haematologica* 2010;95:1075-1080. doi:10.3324/haematol.2009.017889



Online Supplementary Figure S1. Trend of PNH clone size for each patient over time. Patients with a pre-treatment PNH clone size < 10% is shown on the left and those with a PNH clone size ≥ 10% is shown on the right. This figure corresponds to the right panel of Figure 1.