

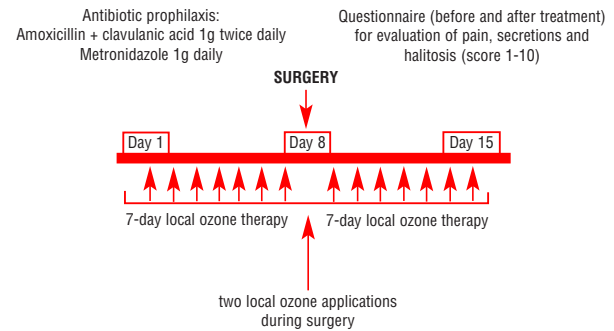
## Role of ozone therapy in the treatment of osteonecrosis of the jaws in multiple myeloma patients

**Current treatments for bisphosphonate-associated osteonecrosis of the jaw (ONJ) in multiple myeloma patients have limited efficacy. The biological effects of ozone indicate it may be therapeutic for ONJ. We, here, report the efficacy of a 15-day course of antibiotics, surgery and ozone therapy in 12 MM patients with ONJ.**

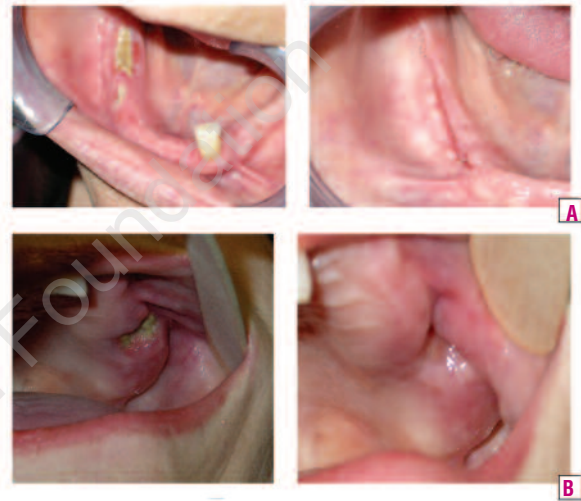*Haematologica* 2007; 92:1289-1290. DOI: 10.3324/haematol.11096

Multiple myeloma (MM) is characterized by a frequent involvement of the bone, ranging from osteoporosis to lytic lesions. Consequently, bisphosphonates such as pamidronate or zoledronic acid, which inhibit osteoclast activity,<sup>1</sup> are commonly prescribed for the prevention and treatment of pathological fractures in patients with MM.<sup>2</sup> Bisphosphonates are extremely effective in reducing the symptoms and complications of bone lesions, and have been shown to have a profound positive impact on quality of life for patients with MM.<sup>3</sup> However, since September 2003, several hundred cases of ONJ associated with bisphosphonate therapy in patients with MM or breast, prostate or lung cancer have been reported worldwide; usually, but not always, in those who have undergone head and neck radiotherapy or a dental procedure.<sup>4</sup> These lesions result from avascular necrosis of the bone, hypothetically due to inhibition of osteoclast activity and angiogenesis by bisphosphonates, with subsequent impaired healing and exposure to infection by oral bacteria.<sup>6</sup> Patients with bisphosphonate-associated ONJ do not respond well to surgical intervention and there are mixed results with antibiotics and/or mouthwashes and not enough data to evaluate the role of hyperbaric oxygen.<sup>5</sup> Thus, there is a need for more effective therapies. Ozone, which has antimicrobial and wound-healing properties, has been used therapeutically in dentistry and medicine for approximately 100 years, for a variety of indications including dental caries.<sup>6,7</sup> Consequently, we investigated the efficacy of ozone therapy in conjunction with antibiotics and surgery in patients with MM who developed ONJ following bisphosphonate therapy.

Since 1998 at our institute 22 of 311 patients with MM treated with intravenous (IV) pamidronate 90 mg/month and/or IV zoledronic acid 4 mg/month were referred with toothache, impaired healing after teeth extractions, dental abscesses and bone exposure. ONJ was diagnosed by a maxillo-facial surgeon based on the following criteria: exposed bone in the maxilla or mandible, associated or not with pain and soft-tissue swelling; unhealed necrotic bone (more than one month), usually (but not necessarily) after dental work; poorly demarcated radio-opaque area of the affected bone on X-ray. Thus, the incidence of bisphosphonate-associated ONJ (7%) is similar to that reported elsewhere.<sup>8-10</sup> After discontinuation of bisphosphonate therapy, patients received a 15-day course of treatment, consisting of antibiotic therapy (amoxicillin-clavulanic acid 1 g twice daily plus metronidazole 1 g daily) and daily ozone therapy from 7 days before to 7 days after surgery, with two more ozone applications during surgery. The schedule of treatment was chosen according to the results obtained by the maxillo-facial surgeon, in previous clinical experiences involving ozone



**Figure 1.** The protocol included antibiotic therapy, ozone therapy, surgery, and pre- and post-treatment assessments.



**Figure 2.** Photographs of the jaw of patients showing two examples each of (A) complete and (B) partial response to therapy.

applications. Questionnaires were administered to patients to evaluate pain, secretions and halitosis (each scored on a scale of 1 to 10) before and after treatment (Figure 1). The study was approved by the ethical committee, the Declaration of Helsinki was adhered to and all patients gave informed consent.

The median age of patients (11 with symptomatic MM treated with chemotherapy and one with smoldering myeloma) was 72 years (range 58–79) and 9 were women. Eight patients had immunoglobulin (Ig)G, three had IgA and one had light chain myeloma. Patients had been treated with bisphosphonates for a median duration of 19 months (range 6–63 months): seven with zoledronic acid and five with pamidronate followed by zoledronic acid. One patient had a wide bone exposition with orosinus fistula, 10 had impaired healing after tooth extractions or oral cleaning, and one developed ONJ spontaneously. All patients presented with pain, secretion and halitosis. The surgical procedures performed as part of the treatment schedule comprised one emimaxillectomy, seven curettages, three tooth extractions, and one extraction plus curettage. Eight patients (75%) achieved complete responses (resolution of ONJ) and four (25%) achieved partial responses (improvement with persistence of lesion), examples of which are shown in Figure 2.

In all patients, pain, secretions and halitosis were overcome. Partial responders had a longer history of disease, more previous cycles of bisphosphonate therapy, and were more likely to have undergone major surgery than complete responders. Although the small number of patients included in this study, these observations support findings reported elsewhere that suggest bisphosphonate exposure may be a risk factor for ONJ and that previous dental procedures are a triggering factor.<sup>8</sup>

While vigilant surveillance of patients receiving bisphosphonates may decrease both the incidence of ONJ and the extent of lesions, the combination of ozone therapy with antibiotics and surgery could be considered for treatment of cases that do arise, based on the positive results reported here. This strategy could be also used to prevent development of ONJ when oral surgery during bisphosphonate treatment cannot be avoided.

Maria Teresa Petrucci,\* Cristiano Gallucci,\* Alessandro Agrillo,<sup>o</sup>  
Maria Cristina Mustazza,<sup>o</sup> Robin Foà\*

\*Hematology, Department of Cellular Biotechnologies  
and Hematology; <sup>o</sup>Clinica Maxillo-Facial University  
"La Sapienza" of Rome, Italy

Key words: ozone therapy, osteonecrosis of the jaw,  
multiple myeloma, bisphosphonates

Correspondence: Maria Teresa Petrucci, MD, Hematology,  
Department of Cellular Biotechnologies and Hematology, University  
"La Sapienza", Via Benevento 6, 00161 Rome, Italy. Phone: inter-  
national +39.06.857951. Fax: international +39.06.441639810.  
E-mail: petrucci@bce.uniroma1.it

## References

1. Rodan GA, Fleisch HA. Bisphosphonates: mechanisms of action. *J Clin Invest* 1996;97:2692-6.
2. Berenson JR, Lichtenstein A, Porter L, Dimopoulos MA, Bordoni R, George S, et al. Long-term pamidronate treatment of advanced multiple myeloma patients reduces skeletal events. Myeloma Aredia Study Group. *J Clin Oncol* 1998;16:593-602.
3. Berenson JR, Hillner BE, Kyle RA, Anderson K, Lipton A, Yee GC, et al. American Society of Clinical Oncology clinical practice guidelines: the role of bisphosphonates in multiple myeloma. *J Clin Oncol* 2002;20:3719-36.
4. Migliorati CA, Siegel MA, Elting LS. Bisphosphonate-associated osteonecrosis: a long-term complication of bisphosphonate treatment. *Lancet Oncol* 2006;7:508-14.
5. Zervas K, Verrou E, Teleioudis Z, Vahtsevanos K, Banti A, Mihou D et al. Incidence, risk factors and management of osteonecrosis of the jaw in patients with multiple myeloma: a single-centre experience in 303 patients. *Br J Haematol* 2006; 134:620-3.
6. Dimopoulos MA, Kastritis E, Anagnostopoulos A, Melakopoulos I, Gika D, Moulouopoulos LA et al. Osteonecrosis of the jaw in patients with multiple myeloma treated with bisphosphonates: evidence of increased risk after treatment with zoledronic acid. *Haematologica* 2006; 91:968-71.
7. Migliorati CA, Schubert MM, Peterson DE, Senada LM. Bisphosphonate-associated osteonecrosis of mandibular and maxillary bone: an emerging oral complication of supportive cancer therapy. *Cancer* 2005;104:83-93.
8. Stubinger S, Sader R, Filippi A. The use of ozone in dentistry and maxillofacial surgery: a review. *Quintessence Int* 2006;37:353-9.
9. Bamias A, Kastritis E, Bamia C, Moulouopoulos LA, Melakopoulos I, Bozas G, et al. Osteonecrosis of the jaw in cancer after treatment with bisphosphonates: incidence and risk factors. *J Clin Oncol* 2005;23:8580-7.
10. Durie BG, Katz M, Crowley J. Osteonecrosis of the jaw and bisphosphonates. *N Eng J Med* 2005;353:99-102.