

Extracavitary tumor after primary effusion lymphoma: relapse or second distinct lymphoma?

HHV-8-associated solid lymphomas which develop in extracavitary sites during the course of primary effusion lymphoma (PEL) could represent the relapse of original PEL tumors in different anatomical sites, or newly occurring distinct HHV-8-associated lymphomas, such as multicentric Castleman disease-related microlymphomas. HHV-8 episome clonality might help identify which event takes place.

Haematologica 2007; 92:1275-1276. DOI: 10.3324/haematol.11364

Primary effusion lymphomas (PEL) usually develop as lymphomatous effusions in serous cavities. PEL tumor cells display pleiomorphic morphology and frequently lack B-cell lineage antigen expression, despite their B-cell monoclonal origin. These cells are latently infected with Human Herpesvirus-8 (HHV-8), and are in most cases co-infected with Epstein-Barr virus (EBV). Extracavitary PEL localizations have been previously described.¹⁻⁵ Recently, short series of human immunodeficiency virus type-1 (HIV-1)-infected patients who developed HHV-8-associated solid lymphomas in the absence of lymphomatous effusions have been reported.^{6,7} In these patients, lymphoma cells share many features with PEL tumor cells, e.g. morphology, immunophenotype and genotype. These cases are now considered as extracavitary PEL solid variants, and belong to the large spectrum of HHV-8-related diseases.

In our series of twenty-eight HIV-1-infected patients treated for PEL,⁵ fourteen patients achieved a complete remission. A PEL recurrence occurred in seven patients, 5-97 months after diagnosis. Three patients, originally described as cases #977, 993 and 1006,⁸ developed lymphomas with extracavitary localizations several months after PEL, involving the spleen (month 8), the maxillary sinus (month 36), and the mediastinum and heart cavities

(month 39) respectively. Secondary tumors and the matched primary PEL tumors were comparatively analyzed to distinguish the recurrence of original PEL tumor in a different anatomical site from the occurrence of novel HHV-8-associated lymphoma.

In cases #993 and 1006, the extracavitary lymphoma and PEL cells collected from the same patients demonstrated identical morphology (Figure 1A-B). Immunophenotype, λ light chain restriction, EBV and HHV-8 viral status, and monoclonal immunoglobulin heavy chain (IGH) gene rearrangement were also identical (Table 1). Similar levels of HHV-8 DNA load were also found in both lymphoma localizations. In both cases, the clonal identity between the PEL tumor and the extracavitary lymphoma localization was demonstrated by the IGH complementary determining region 3 (CDR3) sequencing. However, a cytoplasmic expression of CD3 antigen was observed in the mediastinal tumor cells from patient #1006, whereas the matched PEL cells were found to be CD3-negative (Table 1). Aberrant expression of CD3 by PEL cells has previously been reported in extraserosus PEL¹ and in extracavitary solid PEL variants.⁷ In such cases, the immunostaining was often cytoplasmic, weak or/and restricted to a minority of tumor cells.

In case #977, morphology, immunophenotype and molecular characteristics of the spleen lymphoma were consistent with HHV-8-associated multicentric Castleman disease (MCD)-related microlymphoma.^{9,10} In contrast to PEL cells collected from the same patient, the spleen tumor cells consisted of IgM-positive and CD138-negative HHV-8-infected plasmablasts (Figure 1C-D), characterized by a λ light chain restriction and an oligoclonal pattern of IGH gene rearrangements (Table 1). In the spleen, the HHV-8 DNA load was found to be 17-fold lower than in the matched PEL tumor. Furthermore, low levels of EBV DNA sequences were detected in the spleen whereas the corresponding PEL cells were found to be EBV-negative (Table 1).

Molecular analysis of HHV-8 clonality demonstrated an oligoclonal pattern of HHV-8 episomes in the PEL tumors of patients #977 (Figure 1E) and 1006 (Figure 1G). In case

Table 1. Pathologic, immunologic and molecular features of lymphoma cells at the time of diagnosis and recurrence.

Patient	Sample	Morphology	Immunophenotype	Light chain restriction	B-cell clonality*	Tumor cell percentage†	HHV-8 DNA load (copies/cell)‡	EBV DNA load (copies/cell)‡
993	Ascitis	PEL cells	CD3- CD20- cyt μ + CD30+ CD138+ LANA-1+	lambda	monoclonal	96%	27	5.8
	Maxillary sinus tumor	PEL-like cells	CD3- CD20- cyt μ + LANA-1+	lambda	monoclonal	>95%	20	2.1
1006	Pericardial effusion	PEL cells	CD3- CD20- CD30+ CD138+ LANA-1+	lambda	monoclonal	95%	76	negative
	Mediastinal tumor	PEL-like cells	cytCD3+ CD20- CD30+ CD138+ LANA-1+	lambda	monoclonal	>95%	61	negative
977	Pleural effusion	PEL cells	CD3- CD20- CD7+ CD30+ CD138+ LANA-1+	none	monoclonal	97%	221	negative
	Spleen	Plasmablasts	CD3- C20- IgM+ CD30- CD138- LANA-1+	lambda	oligoclonal	50%	13	0.013

PEL: primary effusion lymphoma; LANA-1: latency-associated nuclear antigen-1; EBV: Epstein-Barr virus; HHV-8: human herpesvirus-8; cyt μ +: cytoplasmic expression of μ heavy chain; cytCD3+: aberrant cytoplasmic expression of CD3 antigen. (*): assessed by PCR detection of monoclonal immunoglobulin heavy chain (IGH) gene rearrangements. (†): estimated by morphological analyses. (‡): determined by a quantitative real-time PCR assay (Taqman).

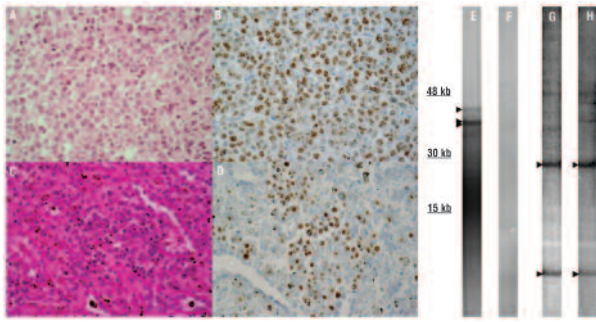


Figure 1. Left panel: morphologic and immunohistochemical analyses. (A, B) The mediastinal mass biopsy obtained from patient 1006 displayed a diffuse infiltration with large PEL-like tumor cells containing irregularly shaped nuclei and abundant cytoplasm. (A) Hematoxylin and Eosin (HE) stain, x400; latency-associated nuclear antigen-1 (LANA-1) immunostaining showed that most tumor cells exhibited the pattern of nuclear speckles characteristic of HHV-8-infected cells. (B) LANA-1, x400. C, D. The spleen of patient 977 was infiltrated with coalescent sheets of plasmablasts. These cells had a moderate amphophilic cytoplasm and a large rounded nucleus often peripherally located and containing one or more prominent nucleoli (C, HE stain, x400); they were HHV-8-infected. (D) LANA-1, x400. Right panel: HHV-8 clonality analysis. Southern blot hybridization of Taq-I -digested genomic DNA with a ^{32}P -labeled HHV-8 terminal repeat probe (803 bp *NotI* fragment, kindly provided by Y. Chang, Columbia University, NY) showed an oligoclonal pattern of HHV-8 episomes in PEL tumors from patients 977 (E, three bands) and 1006 (G, two major bands). The lack of detectable signal from the spleen of patient 977 (F) suggested a polyclonal pattern of episomes in HHV-8-associated microlymphoma. In the mediastinal mass biopsy from patient 1006 (H), the pattern of HHV-8 episomes was found to be similar to that detected in the matched PEL tumor, except for minor differences in a few faint bands of large size that suggested the occurrence of episome rearrangements during the course of PEL.

#1006, the pattern of HHV-8 episomes detected in the mediastinal tumor (Figure 1H) was similar to that observed in the matched PEL tumor, as both tumors contained two major bands of identical size. No signal was detectable in the spleen of patient #977 despite significant HHV-8 DNA loads, suggesting that the splenic microlymphoma might contain polyclonal HHV-8 episomes (Figure 1F). Several studies on HIV-1-infected patients have already suggested the clonal identity between PEL tumor and its extracavitary lymphoma localization. One patient simultaneously developed a pericardial PEL and multiple cutaneous lesions.² Another patient developed a small bowel mass 10 months after a pleural PEL,³ and a third developed a cardiac lymphoma 2 years after a pericardial PEL.⁴ However, no sequencing analysis of the CDR3 region was performed.

Therefore, HHV-8-associated solid lymphoma which develops in HIV-1-infected patients during the course of PEL may be the result from two phenomena: (i) the recurrence of the original PEL tumor in extracavitary sites, (ii) the occurrence of a second HHV-8-associated lymphoma distinct from the primary PEL tumor, such as MCD-related microlymphoma. We believe that in such cases, the molecular analysis of B-cell and HHV-8 episome clonality would help discriminate between these two possibilities by demonstrating the common cellular origin of the original PEL tumor and its extracavitary recurrence.

Emmanuelle Boulanger, Véronique Meignin,
Philippe V. Afonso, Renan Duprez, Eric Oksenhendler,
Félix Agbalika, Antoine Gessain

Service d'Immunopathologie Clinique, Département d'Immunologie Clinique, Hôpital Saint-Louis, Assistance Publique-Hôpitaux de Paris (AP-HP) (EB, EO); Laboratoire d'Anatomie Pathologique, Hôpital Saint-Louis, AP-HP (VM); Unité d'Epidémiologie et de

Physiopathologie des Virus Oncogènes, Département de Virologie, Institut Pasteur (PVA, RD, AG); Laboratoire de Virologie, Hôpital Saint-Louis, AP-HP, Paris, France (FA)

Key words: human herpesvirus 8, Kaposi sarcoma-associated herpesvirus, non-Hodgkin's lymphoma, primary effusion lymphoma, human immunodeficiency virus type 1.

Funding: EB has been financially supported by the French Foundation Sidaction-Ensemble contre le SIDA, RD by the Ligue Nationale contre le Cancer and the Régime Social des Indépendants, and PA by the Ministère Délégué à l'Enseignement Supérieur et à la Recherche. This work has been supported in part by the Association pour la Recherche sur le Cancer (ARC).

Acknowledgments: the authors are grateful to Sylviane Bassot (Unité d'Epidémiologie et de Physiopathologie des Virus Oncogènes, Institut Pasteur) and Patrick Villaresse (Laboratoire d'Hématologie, Hôpital Necker Enfants Malades) for their expert technical assistance, and to Pierre Boulanger (Laboratoire de Virologie et Pathogénèse Virale, Université Claude Bernard, Lyon) for his critical reading of the manuscript. The authors also acknowledge with thank the help of Marie-Thérèse Daniel (Laboratoire d'Hématologie, Hôpital Saint-Louis), Diane Damotte (Laboratoire d'Anatomie Pathologique, Hôpital Européen Georges Pompidou) and Josette Brière (Laboratoire d'Anatomie Pathologique, Hôpital Saint-Louis) for morphological analyses, and Elizabeth Macintyre for her interpretation of B-cell clonality.

Correspondence: Emmanuelle Boulanger, Département d'Immunologie Clinique, Hôpital Saint-Louis, 1 avenue Claude Vellefaux, 75 475 Paris cedex 10, France. Phone: international +33.142499690. Fax: international +33.14249 94 72. E-mail: emmanuelle.boulanger@sls.aphp.fr

References

- Otsuki T, Kumar S, Ensoli B, Kingma DW, Yano T, Stetler-Stevenson M, et al. Detection of HHV-8/KSHV DNA sequences in AIDS-associated extranodal lymphoid malignancies. *Leukemia* 1996;10:1358-62.
- Nakamura K, Katano H, Hoshino Y, Nakamura T, Hosono O, Masunaga A, et al. Human herpesvirus type 8 and Epstein-Barr virus-associated cutaneous lymphoma taking anaplastic large cell morphology in a man with HIV infection. *Br J Dermatol* 1999;141:141-5.
- Huang Q, Chang KL, Gaal K, Arber DA. Primary effusion lymphoma with subsequent development of a small bowel mass in an HIV-seropositive patient: a case report and literature review. *Am J Surg Pathol* 2002;26:1363-7.
- Maric I, Washington S, Schwartz A, Anandan V, Karcher DS. Human herpesvirus-8-positive body cavity-based lymphoma involving the atria of the heart: a case report. *Cardiovasc Pathol* 2002;11:244-7.
- Boulanger E, Gerard L, Gabarre J, Molina JM, Rapp C, Abino JF, et al. Prognostic factors and outcome of human herpesvirus 8-associated primary effusion lymphoma in patients with AIDS. *J Clin Oncol* 2005;23:4372-80.
- Chadburn A, Hyjek E, Mathew S, Cesarman E, Said J, Knowles DM. KSHV-positive solid lymphomas represent an extra-cavitary variant of primary effusion lymphoma. *Am J Surg Pathol* 2004;28:1401-16.
- Carbone A, Ghoghini A, Vaccher E, Cerri M, Gaidano G, Dalla-Favera R, et al. Kaposi's sarcoma-associated herpesvirus/human herpesvirus type 8-positive solid lymphomas: a tissue-based variant of primary effusion lymphoma. *J Mol Diagn* 2005;7:17-27.
- Boulanger E, Duprez R, Delabesse E, Gabarre J, Macintyre E, Gessain A. Mono/oligoclonal pattern of Kaposi sarcoma-associated herpesvirus (KSHV/HHV-8) episomes in primary effusion lymphoma cells. *Int J Cancer* 2005;115:511-8.
- Du MQ, Liu H, Diss TC, Ye H, Hamoudi RA, Dupin N, et al. Kaposi sarcoma-associated herpesvirus infects monotypic (IgM λ) but polyclonal naive B cells in Castleman disease and associated lymphoproliferative disorders. *Blood* 2001;97:2130-6.
- Oksenhendler E, Boulanger E, Galicier L, Du MQ, Dupin N, Diss TC, et al. High incidence of Kaposi sarcoma-associated herpesvirus-related non-Hodgkin lymphoma in patients with HIV infection and multicentric Castleman disease. *Blood* 2002;99:2331-6.