



## B-cell recovery after stem cell transplantation of Artemis-deficient SCID requires elimination of autologous bone marrow precursor-B-cells

Mirjam van der Burg\*  
Corry M.R. Weemaes\*  
Frank Preijers  
Paul Brons  
Barbara H. Barendregt  
Maarten J.D. van Tol  
Peter Hoogerbrugge  
Jacques J.M. van Dongen

Severe combined immunodeficiencies (SCID) are commonly fatal early in life. Adequate diagnosis and rapid institution of treatment, such as allogeneic stem cell transplantation (SCT), is essential. Several studies demonstrated that reconstitution of B-cell function after SCT is better in B-positive SCID than in B-negative SCID. We demonstrate that B-cell reconstitution in a B-negative SCID patient due to an *Artemis* mutation required the elimination of the autologous precursor-B-cells in bone marrow, probably to create physical space in the precursor-B-cell niches. Apparently, occupation of the precursor-B-cell niches is a potential dominant factor influencing repopulation of a functional B-cell compartment in B-negative SCID.

Key words: B-cell recovery, *Artemis*-deficient SCID, stem cell transplantation.

Haematologica 2006; 91:1705-1709

©2006 Ferrata Storti Foundation

\*These authors contributed equally

From the Erasmus MC, Dept. of Immunology, Rotterdam, The Netherlands (MvdB, BHB, JJMvdD); UMCN-St Radboud, Dept. of Pediatrics, Nijmegen, The Netherlands (CMRW); UMCN-St Radboud, Central Hematology Laboratory, Nijmegen, The Netherlands (CMRW, FP, PB, PH); Erasmus MC, dept. of Pediatrics, Rotterdam, The Netherlands (BHB); Leiden University Medical Center, Dept. of Pediatrics, section IHOBA, Leiden, The Netherlands (MJDvT).

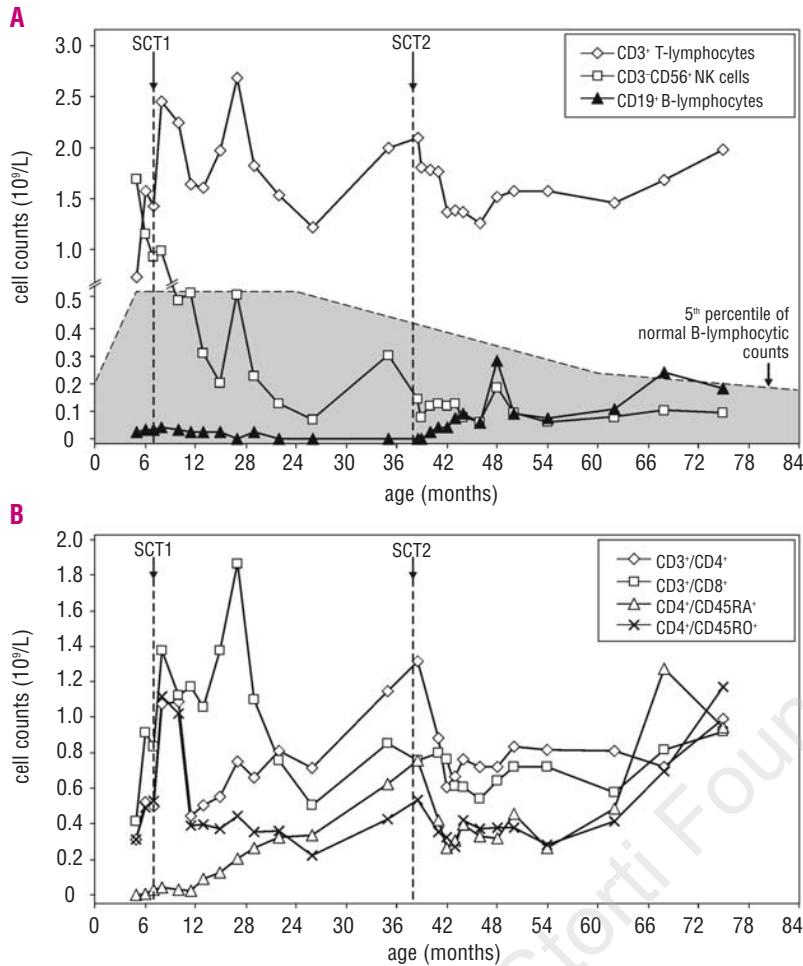
Correspondence:  
Jacques J.M. van Dongen, MD, PhD,  
Department of Immunology, Erasmus  
MC, Dr. Molewaterplein 50, 3015 GE  
Rotterdam, The Netherlands.  
E-mail:  
j.j.m.vandongen@erasmusmc.nl

Severe combined immunodeficiencies (SCID) constitute a heterogeneous group of inherited disorders, which are characterized by the absence of T cells accompanied by the absence of either B cells or NK cells depending on the SCID category. SCID result in severe impairment of both cellular and humoral immunity,<sup>1</sup> and in the absence of treatment lead to death during infancy due to persistent and severe infections with opportunistic micro-organisms. Stem cell transplantation (SCT) is the current treatment and produces a survival rate of around 80%; gene therapy has been explored for some SCID conditions.<sup>2-4</sup> Immunologically, two major categories of SCID can be identified. The first category comprises B-positive SCID, associated with mutations in *IL2RG* or *JAK3* (T<sup>+</sup>B<sup>+</sup>NK<sup>-</sup>SCID), or with mutations in *IL7RA* (T<sup>+</sup>B<sup>+</sup>NK<sup>+</sup>SCID).<sup>15</sup> The second category comprises B-negative SCID (T<sup>+</sup>B<sup>-</sup>NK<sup>+</sup>SCID), which are mainly due to defects in V(D)J recombination of immunoglobulin (Ig) and T-cell receptor (TCR) genes. In approximately 70% of these patients, mutations are found in the *RAG1* and *RAG2* genes;<sup>6,7</sup> and a subset of the remaining patients show hypersensitivity to ionizing radiation and have mutations in *Artemis* or *LIG4*.<sup>8-13</sup> In retrospective studies, it was demonstrated that the results of HLA non-identical T-cell-depleted SCT were significantly better in patients with B-positive SCID than in those with B-negative SCID.<sup>2,14,15</sup> The reduced survival of B-negative SCID patients appeared to be associated with a lower rate of engraftment (particularly in the absence of a

conditioning regimen), a higher frequency of chronic graft-versus-host disease (GVHD), increased severity of acute GVHD, and a slower and less complete recovery of T/B immune function.<sup>2,14,15</sup> In patients with B-negative SCID, engraftment of T-cell depleted bone marrow and post-SCT restoration of B-cell function might be increased through the use of a myeloablative conditioning regimen.<sup>2,14</sup> The latter observation has also specifically been made concerning children transplanted for SCID due to an *Artemis* gene defect.<sup>16</sup>

Detailed flow cytometric immunophenotyping of the precursor B cells in bone marrow has shown that in healthy children and B-positive SCID patients, pro-B-cells and pre-B-I cells represent 20% to 25% of the precursor B-cell compartment, which also contains small and large pre-B-II cells and immature B-cells. However, in B-negative SCID patients (including those with radiosensitive SCID with *Artemis* mutations) pro-B-cells and pre-B-I cells account for 95 to 100% of this compartment.<sup>9,17,18</sup> Since the total size of the precursor B-cell compartment in B-negative SCID is not smaller than in healthy children, it can be concluded that the earliest stages of B-cell development completely occupy the precursor B-cell niches.<sup>9,19</sup>

Based on these observations, we hypothesized that failure of B-cell reconstitution in B-negative SCID patients after SCT might be caused by lack of physical space in the bone marrow due to the presence of a high frequency of early precursor B-cells (pro-B and pre-B-I), which strongly adhere to their niches and



**Figure 1.** Absolute numbers of lymphocytes. **A.** Absolute numbers of CD3<sup>+</sup> T-lymphocytes, CD19<sup>+</sup> B-lymphocytes and CD3<sup>-</sup>/CD56<sup>+</sup> NK cells during the course of transplantation. The time points of SCT are indicated with arrows. **B.** Absolute numbers of different T-cell subsets (CD4, CD8, naïve CD4<sup>+</sup>/CD45RA<sup>+</sup> and effector/memory CD4<sup>+</sup>/CD45RO<sup>+</sup>).

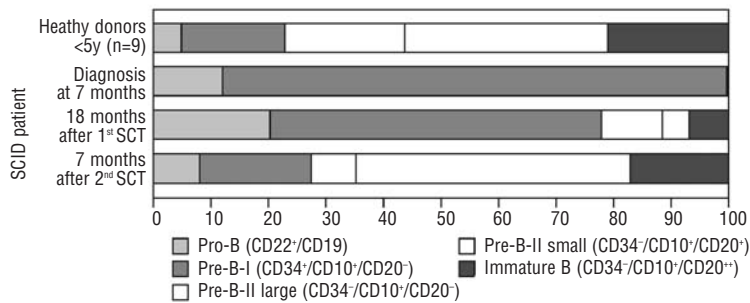
which need to be eradicated by pre-SCT conditioning regimens. We studied an *Artemis*-deficient SCID patient, who did not show circulating mature B-cells after being transplanted without conditioning. Re-transplantation with reduced intensity conditioning resulted in reconstitution of a functional B-cell system. These observations are in line with our hypothesis.

**Case report**

A female patient was referred at the age of 5 months for failure to thrive and dyspnea. She had interstitial pneumonia caused by *Pneumocystis carinii* and cytomegalovirus. Treatment with cotrimoxazole and ganciclovir induced recovery. Immunological studies revealed hypogammaglobulinemia, absence of B-lymphocytes, decreased numbers of T-lymphocytes, but normal NK-cell counts. Her T-cells appeared to be of maternal origin due to maternal engraftment. The diagnosis of SCID was made and we identified a homozygous G47T mutation in exon 5 of the *Artemis* gene.<sup>9</sup>

At the age of 7 months, the girl received a non-T-cell depleted bone marrow graft from her HLA-identical brother without infusion of antithymocyte globulin or

conditioning. After an uneventful post-transplantation course, a gradual rise in donor T-cells occurred and maternal T-cells gradually disappeared within 1 year. There were increases in the numbers of CD4-positive naïve T-cells as well as in CD8-positive T-cells (Figure 1). Monocytes, granulocytes and NK cells remained of host origin. B cells continued to be absent and the patient was dependent on immunoglobulin substitution. Therefore, at the age of 38 months she received a second non-T-cell-depleted bone marrow graft from the same donor. Conditioning consisted of busulfan 2 mg/kg at days -3 and -2. This reduced intensity conditioning did not result in neutropenia, anemia or thrombocytopenia. The start of B-cell reconstitution was observed at 1 month after the second SCT and the absolute number of B-cells increased to sub-normal levels (0.13×10<sup>9</sup>/L) by 5 months after the transplant. Eight months post-SCT chimerism analysis showed that B and T cells were exclusively of donor origin, whereas NK cells, monocytes and granulocytes were of recipient origin. Most importantly, the girl developed normal IgG and IgM serum levels, but no IgA. Upon vaccination she developed normal antibody titers against diphtheria, tetanus toxoid, poliomyelitis and *Haemophilus influenzae*.



**Figure 2.** Flow cytometric analysis of the composition of the bone marrow precursor B-cell compartment at diagnosis, and after the first and second transplants. At diagnosis only pro-B and pre-B-I cells were found with <2% pre-B-II cells and immature B-cells. Eighteen months after the first SCT (performed at the age of 7 months) only 20-25% pre-B-II small and immature B-cells were detected, but 7 months after the second SCT with conditioning (performed at the age of 38 months), the precursor-B-cell compartment was found to have a completely normal composition.

## Design and Methods

### Flow cytometry

The precursor-B-cell compartment was analyzed at diagnosis, 18 months after the first SCT and 7 months after the second SCT.<sup>9</sup> From the post-SCT bone marrow samples four CD19-positive precursor-B-cell subsets were sorted with a FACS Digital Vantage (DiVa) cell sorter (BD Biosciences, Santa Clara, CA, USA) after four-color staining with CD34-FITC, CD20-PE (Leu-16), CD19-PerCP, CD10-APC (HI10a) (BD Biosciences): (i) pre-B-I (CD34<sup>+</sup>CD10<sup>+</sup>CD20<sup>-</sup>), (ii) pre-B-II large (CD34<sup>+</sup>CD10<sup>+</sup>CD20<sup>-</sup>), (iii) pre-B-II small (CD34<sup>+</sup>CD10<sup>+</sup>CD20<sup>+</sup>), and (iv) immature B-cells (CD34<sup>+</sup>CD10<sup>+</sup>CD20<sup>+</sup>).<sup>20</sup>

### Chimerism analysis

DNA was extracted from the sorted cell fractions using 20  $\mu$ L lysis buffer (10 mM Tris-HCl (pH 7.6), 50 mM NaCl, 6.25 mM MgCl<sub>2</sub>, 0.045% NP40, 0.45% Tween-20). One microliter of Prot K (20 mg/mL) was added followed by incubation overnight at 56°C and inactivation by incubation at 95°C for 15 minutes. The chimerism status was determined using the PowerPlex16 kit (Promega, Madison, WI, USA).

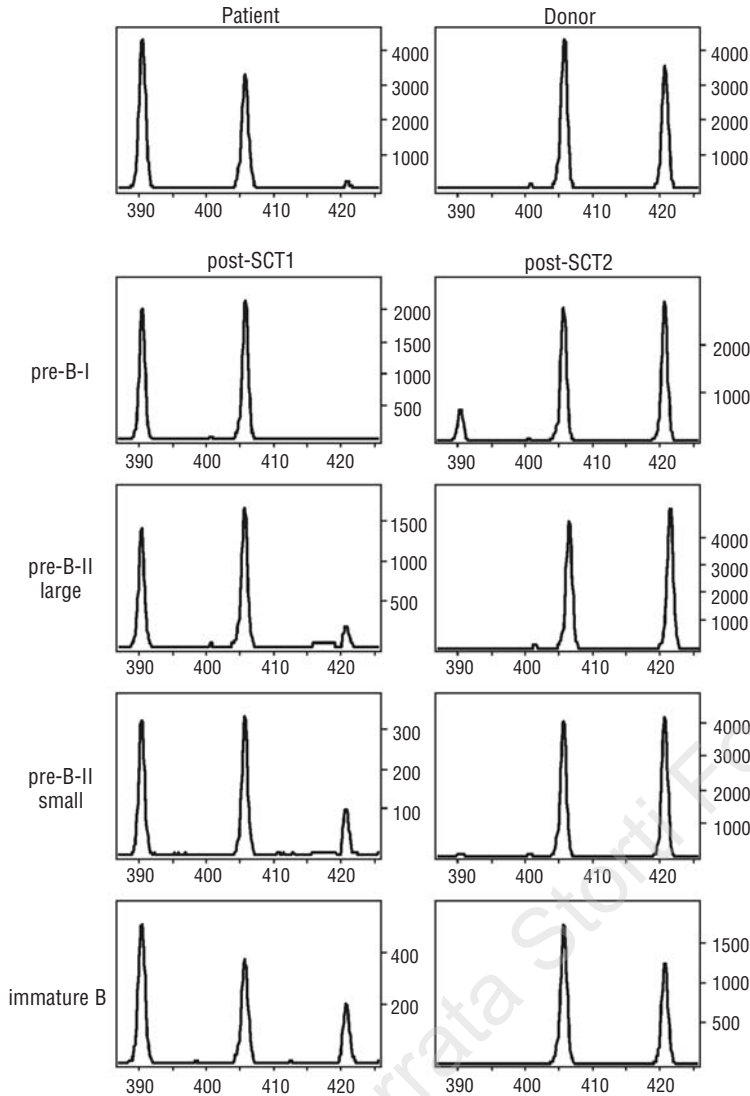
## Results and Discussion

Reconstitution of B-cell function after SCT is more common in B-positive SCID patients than in B-negative SCID ones.<sup>2,15</sup> The origin (host or donor) of peripheral blood B-cells in B-positive SCID patients after SCT will have an impact on B-cell function, but is often not reported. We hypothesized that the impaired B-cell reconstitution in B-negative SCID patients after SCT might be caused by lack of physical space in the precursor B-cell compartment in bone marrow due to the presence of a high frequency of early precursor B cells (pro-B and pre-B-I), which probably adhere tightly to their breeding sites.

We describe an *Artemis*-deficient SCID patient, who initially received a SCT without conditioning and did not show B-cell reconstitution in the peripheral blood. This

patient was re-transplanted following conditioning consisting of a low dose of busulfan. The precursor B-cell compartment in the bone marrow was analyzed at diagnosis, as well as after the first and second transplant.<sup>9</sup> At diagnosis we observed a complete block in B-cell maturation before the pre-B-II cell stage. After the first SCT, the precursor B-cell compartment showed an incomplete block with the presence of low proportions of cells at the pre-B-II cell and immature B-cell stages. After the second SCT, the composition of the precursor-B-cell compartment was normal, being comparable to that of age-matched healthy controls (Figure 2). The four CD19-positive precursor B-cell subsets were sorted from bone marrow after the first and second transplants for chimerism analysis. After the first SCT, all pre-B-I cells and most pre-B-II and immature B-cells were of host origin. The more mature precursor-B-cells constituted a reduced fraction of the precursor-B-cell compartment and only a small proportion of these cells were of donor origin (Figure 3). Chimerism analysis of the four CD19-positive precursor B-cell subsets after the second SCT showed that less than 10% of the pre-B-I cells remained of recipient origin and that the pre-B-II large, pre-B-II small, and immature B-cell fractions were completely donor derived (Figure 3). After the second SCT, peripheral reconstitution of functional mature B-cells was observed based on the absolute number of B-cells, the development of normal IgG and IgM serum levels, and the development of specific antibodies upon re-vaccination.

In summary, the absence of B-cell reconstitution after the first SCT (without conditioning) could be explained by the persistence of patient-derived precursor B cells in the bone marrow. Recovery of donor-derived T cells was normal, so the absence of B-cell reconstitution could not be explained by NK-cell-mediated rejection of donor stem cells. The second SCT, preceded by conditioning with a low dose of busulfan, resulted in a precursor B-cell compartment that was almost completely (>90%) of donor origin, giving rise to functional peripheral B-cell reconstitution. Reduced conditioning, which is far less toxic than myelo-ablative conditioning, was already sufficient to eradicate the recipient precursor B-cell compartment and to achieve normal outgrowth of the donor B-lineage cells.



**Figure 3.** Polymerase chain-reaction-based chimerism analysis of DNA isolated from the different precursor B-cell subpopulations in BM after the first and second SCT. After the initial SCT, virtually all precursor B-cells were still of patient origin except for a small proportion of the pre-B-II (small and large) and immature B cells, which were of donor origin. The second SCT resulted in a virtually complete donor-derived precursor B-cell compartment, except for a small fraction (<10%) of the pro-B-cells, which were still of recipient origin. The displayed PowerPlex16 STR marker is Penta E.

These observations demonstrate that B-cell repopulation in B-negative SCID patients requires removal of the patient's precursor-B-cells. Although there are many factors influencing engraftment in patients given SCT for SCID, this single case illustrates that eradication of the patient's precursor-B-cells is one of the potentially critical factors in B-negative SCID. We are currently performing a multi-center prospective study to further confirm our hypothesis.

*MvdB and CMRW cooperated in writing the paper. MvdB: performed research, analyzed data, contributed vital new analytical tools; CMRW: designed research, analyzed clinical data; PB: contributed vital clinical tools; FP: contributed vital new analytical tools; BHB: performed research, contributed vital new analytical tools; MJdT: contributed vital new analytical tools, and critically reviewed the paper; PH: designed research; JJMvD: developed hypothesis and designed research. This work was supported by a grant from the Dutch Cancer Society (KWF, grant EMCR2002-2734) and ZonMw (Veni Grant 916.56.107 from M.v.d.B.). The authors thank Mrs. M. Comans-Bitter for making the figures.*

*Manuscript received March 24, 2006. Accepted September 22, 2006.*

## References

- Buckley RH. The multiple causes of human SCID. *J Clin Invest* 2004;114:1409-11.
- Antoine C, Muller S, Cant A, Cavazzana-Calvo M, Veys P, Vossen J, et al. Long-term survival and transplantation of haemopoietic stem cells for immunodeficiencies: report of the European experience 1968-99. *Lancet* 2003;361:553-60.
- Buckley RH. Molecular defects in human severe combined immunodeficiency and approaches to immune reconstitution. *Annu Rev Immunol* 2004;22:625-55.
- Fischer A, Le Deist F, Hacein-Bey-Abina S, Andre-Schmutz I, Basile Gde S, de Villartay JP, et al. Severe combined immunodeficiency. A model disease for molecular immunology and therapy. *Immunol Rev* 2005;203:98-109.
- Fischer A. Have we seen the last variant of severe combined immunodeficiency? *N Engl J Med* 2003;349:1789-92.
- Schwarz K, Gauss GH, Ludwig L, Pannicke U, Li Z, Lindner D, et al. RAG mutations in human B cell-negative SCID. *Science* 1996;274:97-9.
- Schatz DG. V(D)J recombination. *Immunol Rev* 2004; 200: 5-11.
- Moshous D, Callebaut I, de Chasseval R, Corneo B, Cavazzana-Calvo M, Le Deist F, et al. Artemis, a novel DNA double-strand break repair/V(D)J recombination protein, is mutated in human severe combined immune deficiency. *Cell* 2001;105:177-86.
- Noordzij JG, Verkaik NS, Van der Burg M, Van Veelen LR, De Bruin-Versteeg S, Wiegant W, et al. Radiosensitive SCID patients with Artemis gene mutations show a complete B-cell differentiation arrest at the pre-B-cell receptor checkpoint in bone marrow. *Blood* 2003;101:1446-52.
- Li L, Moshous D, Zhou Y, Wang J, Xie G, Salido E, et al. A founder mutation in Artemis, an SNM1-like protein, causes SCID in Athabascan-speaking Native Americans. *J Immunol* 2002; 168:6323-9.
- Kobayashi N, Agematsu K, Sugita K, Sako M, Nonoyama S, Yachie A, et al. Novel Artemis gene mutations of radiosensitive severe combined immunodeficiency in Japanese families. *Hum Genet* 2003;112:348-52.
- O'Driscoll M, Gennery AR, Seidel J, Concannon P, Jeggo PA. An overview of three new disorders associated with genetic instability: LIG4 syndrome, RS-SCID and ATR-Seckel syndrome. *DNA Repair (Amst)* 2004;3:1227-35.
- Van der Burg M, van Veelen LR, Verkaik NS, Wiegant WW, Hartwig NG, Barendregt BH, et al. A new type of radiosensitive T-B-NK+ severe combined immunodeficiency caused by a LIG4 mutation. *J Clin Invest* 2006;116:137-45.
- Bertrand Y, Landais P, Friedrich W, Gerritsen B, Morgan G, Fasth A, et al. Influence of severe combined immunodeficiency phenotype on the outcome of HLA non-identical, T-cell-depleted bone marrow transplantation: a retrospective European survey from the European group for bone marrow transplantation and the European society for immunodeficiency. *J Pediatr* 1999;134:740-8.
- Haddad E, Landais P, Friedrich W, Gerritsen B, Cavazzana-Calvo M, Morgan G, et al. Long-term immune reconstitution and outcome after HLA-nonidentical T-cell-depleted bone marrow transplantation for severe combined immunodeficiency: a European retrospective study of 116 patients. *Blood* 1998;91:3646-53.
- O'Marcaigh AS, DeSantes K, Hu D, Pabst H, Horn B, Li L, et al. Bone marrow transplantation for T-B- severe combined immunodeficiency disease in Athabascan-speaking native Americans. *Bone Marrow Transplant* 2001; 27:703-9.
- Noordzij JG, De Bruin-Versteeg S, Verkaik NS, Vossen JMJJ, De Groot R, Bernatowska E, et al. The immunophenotypic and immunogenotypic B-cell differentiation arrest in bone marrow of RAG deficient SCID patients corresponds to residual recombination activities of mutated RAG proteins. *Blood* 2002;100:2145-52.
- Noordzij JG, De Bruin-Versteeg S, Comans-Bitter WM, Hartwig NG, Hendriks RW, De Groot R, et al. Composition of precursor B-cell compartment in bone marrow from patients with X-linked agammaglobulinemia compared with healthy children. *Pediatr Res* 2002;51:159-68.
- Nagasawa T. Microenvironmental niches in the bone marrow required for B-cell development. *Nat Rev Immunol* 2006;6:107-16.
- van Zelm MC, van der Burg M, de Ridder D, Barendregt BH, de Haas EF, Reinders MJ, et al. Ig gene rearrangement steps are initiated in early human precursor B cell subsets and correlate with specific transcription factor expression. *J Immunol* 2005;175:5912-22.