



Splenic marginal zone lymphoma-like features in *API2-MALT1* transgenic mice that are exposed to antigenic stimulation

Xavier Sagaert
Tom Theys
Christiane De Wolf-Peeters
Peter Marynen
Mathijs Baens

Recently, we described a transgenic mouse model to analyze the effect of the *API2-MALT1* fusion-protein *in vivo*. Our results showed that the expression of *API2-MALT1* is not sufficient to induce the development of lymphoma masses. Here, we demonstrate that immunization with Freund's complete adjuvant led to the loss of compartmentalization of the splenic white pulp in *API2-MALT1* transgenic mice, resulting in a splenic marginal zone lymphoma-like lymphoid hyperplasia of a peculiar B-cell subset that disappeared as soon as the antigenic stimulation faded away. These data indicate an effect of *API2-MALT1* expression on the normal immune response.

Key words: *API2-MALT1*, MALT lymphoma, immune response.

Haematologica 2006; 91:1693-1696

©2006 Ferrata Storti Foundation

From the Department of Morphology and Molecular Pathology (XS, TT, CWP); Center for Human Genetics, Molecular Genetics-Flanders Interuniversity Institute for Biotechnology (PM, BM), University of Leuven, Leuven, Belgium.

Correspondence:
Xavier Sagaert, MD, Aspirant FWO
Minderbroederstraat 12, B-3000
Leuven, Belgium.
E-mail: xavier.sagaert@uz.kuleuven.ac.be

Extranodal marginal zone lymphoma or mucosa-associated lymphoid tissue (MALT) lymphoma is listed as a separate disease entity in the World Health Organization (WHO) classification of lymphoid tumors, accounting for 7.6% of all non-Hodgkin's lymphomas.¹ Among the genetic defects reported in MALT lymphoma, the translocation t(11;18)(q21;q21) is the most common structural abnormality with a frequency ranging from 10% to 48% (mainly lymphomas with gastric or pulmonary localization) depending on the study.²⁻⁵ The t(11;18)(q21;q21) leads to the generation of a fusion protein comprising the three BIR (baculovirus inhibitor of apoptosis protein repeat) domains present in the N-terminus of the *API2* protein and a variable part of the *MALT1* protein, containing the caspase p20-like domain.⁶ The chimeric protein *API2-MALT1* effectively activates nuclear factor κ B (NF- κ B) *in vitro*, a transcription factor for a number of survival-related genes.⁷ The presence of t(11;18)(q21;q21) correlates with apparent lack of further genetic instability or chromosomal imbalances.⁸ In view of this specific association between t(11;18)(q21;q21) and MALT lymphoma, we developed a transgenic mouse model to analyze *in vivo* the effect of the fusion-protein *API2-MALT1* on the development of lymphoid tissue.⁹ Transgenic FVB animals were generated via pronuclear injection of an *API2-MALT1* fusion construct between exon 7 of *API2* and exon 8 of *MALT1* driven by the SR α promoter under the control of the immunoglobulin heavy-chain enhancer (E μ). It was shown that expression of *API2-MALT1* alone is not suf-

ficient to induce the development of lymphoma masses within 50 weeks. Nevertheless, it triggered the specific expansion of the splenic marginal zone (Figure 1), affected B-cell maturation in the bone marrow and increased polyubiquitination of the NF- κ B essential modulator (NEMO) or IKK γ and, thus, NF- κ B activation.⁹ Here, we describe the morphologic, immunophenotypic and molecular features of *API2-MALT1* transgenic mice after antigenic stimulation.

Design and Methods

The absence of spontaneous lymphoma development in *API2-MALT1* transgenic mice suggests that other pathogenic mechanisms, acting synergistically with the *API2-MALT1* fusion protein, are essential for the development and growth of a lymphoma. In this respect and considering the association of MALT lymphoma with (auto)antigenic stimulation, 40-week old transgenic mice (n=10), as well as their equally old wild-type littermates (n=10), were exposed to a strong antigenic stimulus, by means of intraperitoneal injection of a single bolus (200 μ L) of Freund's complete adjuvant (Sigma-Aldrich, St. Louis, USA).¹⁰ Antigen-exposed mice were sacrificed 3 weeks later, when the immune response to Freund's adjuvant is known to be fully developed, as well as 6, 9 and 12 weeks after exposure to antigenic stimulation. Macroscopic findings as well as microscopic features of the spleen, lymph nodes, bone marrow, thymus, gut, lung, liver and salivary glands were analyzed. Hematoxylin and eosin-stained sections (4

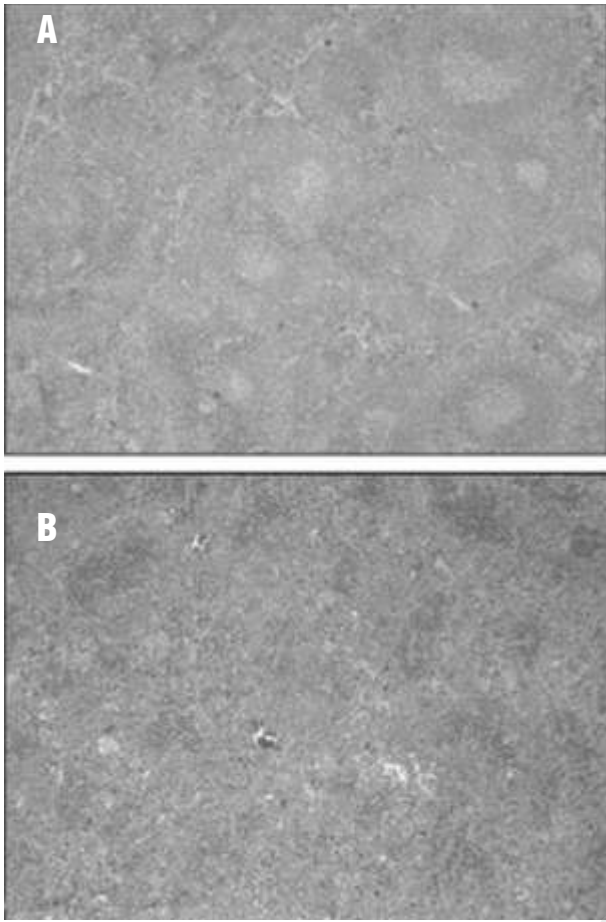


Figure 1. Spleen morphology of *API2-MALT1* transgenic mice and wild-type littermates at the age of 20 weeks. Transgenic mice show a reduction of red pulp with an increase of white pulp due to an expanded marginal zone (A) compared with their wild-type littermates (B).

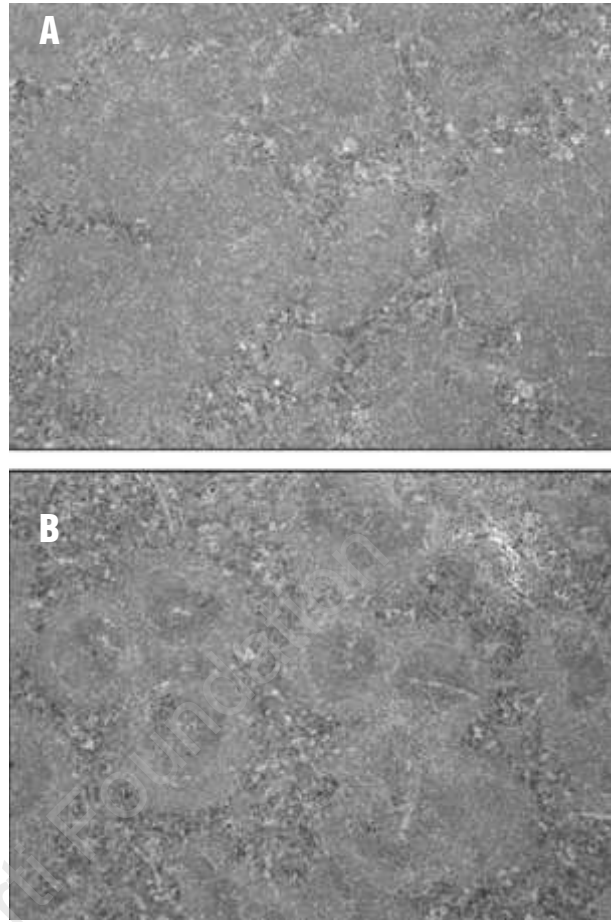


Figure 2. Three weeks after immunization with Freund's complete adjuvant, the compartmentalization of the follicle mantle had totally disappeared in *API2-MALT1* transgenic mice (A), while the mantle zone of the B-follicles in wild-type mice preserved its compartmentalisation into a marginal zone and a lymphocytic corona (B).

µm) of formalin- or B5-fixed, paraffin-embedded biopsies were examined carefully for the presence of histopathological lesions. Serial paraffin sections of the spleen were immunostained for the B-cell marker CD20 (goat polyclonal anti-mouse antibody [Santa Cruz Biotechnology, Santa Cruz, USA]) and the T-cell marker CD3 (rabbit polyclonal anti-mouse antibody [Sigma-Aldrich, St Louis, USA]), whereas frozen sections of the spleen were stained for IgM (rabbit polyclonal anti-mouse antibody [Serotec, Oxford, United Kingdom]), IgD (rabbit polyclonal anti-mouse antibody [Southernbiotech, Alabama, USA]) and CD5 (rabbit polyclonal anti-mouse antibody [Pharmingen, San Diego, USA]). According to a previously published protocol,^{11,12} polymerase chain reaction (PCR) analysis of the CDR3 region of the immunoglobulin heavy-chain gene was performed on selected specimens to analyze the clonal nature of any observed B-cell proliferation.

Results and Discussion

No macro- nor microscopic differences were noted in any of the organs examined after antigenic stimulation with Freund's adjuvant, except for the spleen. In this secondary lymphoid organ, a striking morphologic difference was found between the white pulp of transgenic and wild-type mice (Figures 2 and 3): wild-type mice preserved a normal distribution of red and white pulp with intact compartmentalization of the follicle mantle into a lymphocytic corona (composed of IgM⁺/IgD⁺B-cells) and a marginal zone (composed of IgM⁺/IgD⁺B cells). In contrast, the spleen of transgenic mice was characterized by a very prominent white pulp, composed of very large B-cell areas and poorly developed T-cell areas, and an almost absence of the red pulp. Moreover, compartmentalization of the follicle mantle into a marginal zone and lymphocytic corona complete-

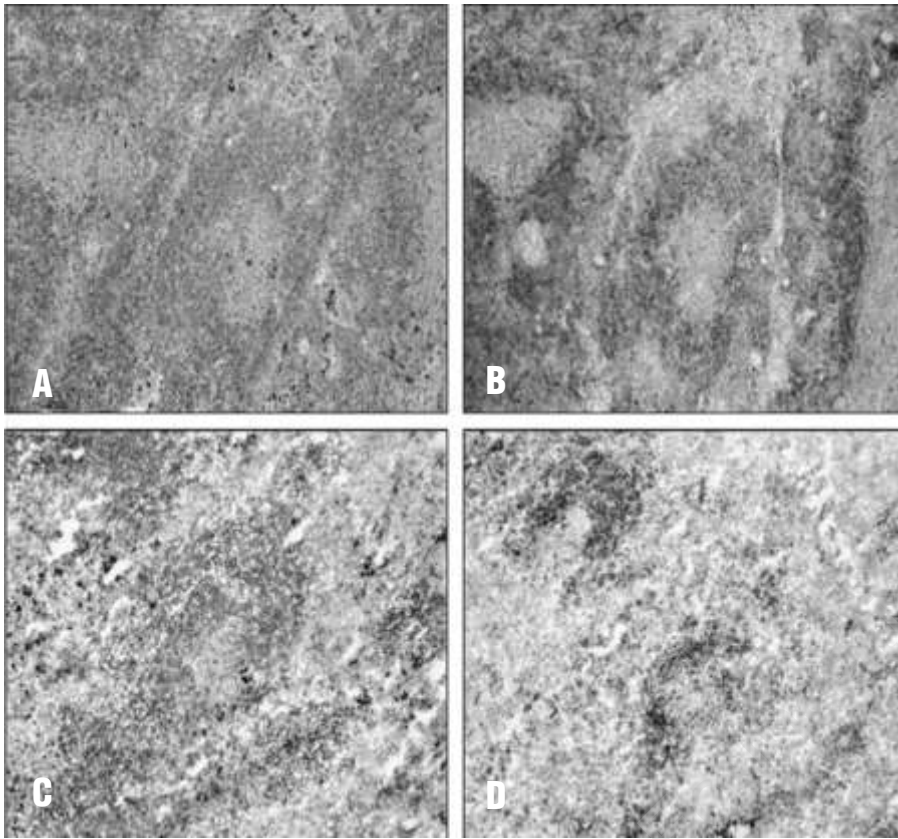


Figure 3. In antigen-exposed transgenic mice, the normal compartmentalization of the follicle mantle is replaced by a proliferation of small B cells, which strongly express both surface IgM (A) and IgD (B). In contrast, their wild-type littermates preserve intact compartmentalization of the follicle mantle: the lymphocytic corona and marginal zone both strongly express surface IgM (C), while strong IgD expression is only observed in the lymphocytic corona (D).

ly disappeared. The mantle zone was almost entirely populated by small B-lymphocytes and clusters of these cells could also be seen in the red pulp, sometimes invading the sinuses. Further immunophenotypic characterization showed that these small B-lymphocytes lacked CD5 expression, and were marked by strong surface IgM and IgD expression. These findings indicate that the presence of the *API2-MALT1* fusion protein, in combination with strong antigenic stimulation, favors the expansion of a peculiar B-cell population. More importantly, this combination of events results in a disrupted architecture of the splenic white pulp with morphologic and immunophenotypic features that strongly resemble a splenic marginal zone lymphoma as defined by the WHO classification for human lymphoid neoplasms¹ and by the Bethesda group for mice lymphoid neoplasms.¹³ In humans, this type of non-Hodgkin's lymphoma is a rare disorder, accounting for less than 1% of lymphoid tumors, and is considered by the WHO classification as a separate disease entity.^{1,14,15} Although distinct from MALT lymphomas, it is postulated that splenic marginal zone lymphomas also probably arise from a B-cell subset homing in the marginal zone. It is a B-cell neoplasm comprising small lymphocytes which surround (and sometimes replace) germinal centers, efface the follicle mantle and merge with a peripheral marginal zone-like area which includes some transformed blasts. The neoplastic B cells are typically CD5-negative but strongly express surface IgM and IgD, hav-

ing the identical immunophenotype to that of the expanded B-cell population in the *API2-MALT1* transgenic mice after administration of Freund's adjuvant. Despite significant differences in the architecture of the normal marginal zone between mice and humans,¹⁶ the morphology and immunophenotype of splenic marginal zone lymphoma in mice parallel those of human splenic marginal zone lymphoma remarkably; however, for a reason not yet known, the incidence of splenic marginal zone lymphomas is much higher in some strains of mice (e.g. NZB and NFS.V⁺ strains) than in humans.¹² In FVB mice, which were chosen as the background strain for our animal model, splenic marginal zone lymphomas and lymphoproliferative disorders in general are uncommon features,¹⁷ further emphasizing the importance of the observed lymphoid hyperplasia in the splenic white pulp of the antigen-exposed, *API2-MALT1* transgenic mice.

PCR analysis of the CDR3 region of the immunoglobulin heavy-chain gene was performed on splenic biopsies, to analyze the clonal nature of the observed B-cell proliferation. Despite clear-cut morphologic and immunophenotypic features indicative of a splenic marginal zone lymphoma, the splenic B-cell proliferation in the antigen-exposed, *API2-MALT1* transgenic mice was found to be oligoclonal (4 of 10 cases analyzed; 40%) or polyclonal (6 of 10 cases analyzed; 60%), thereby suggesting the presence of a (pre)malignant(?) lymphoid hyperplasia rather than a malignant lymphomatous

process. Due to this absence of monoclonality, it is more appropriate to describe the observed loss of the immunoarchitectural pattern in the spleen of the transgenic mice as marginal zone lymphoma-like features rather than define them as genuine splenic marginal zone lymphomas. However, it must be noted that in daily clinical practice, the diagnosis of lymphoma is still primarily based on morphologic and immunohistochemical analyses, and that PCR can only provide additional arguments in favor of a histologically diagnosed lymphoid malignancy if monoclonality can be demonstrated (the absence of monoclonality does not exclude a lymphoma).

At present, it is unclear why marginal zone lymphoma-like features appear in *API2-MALT1* transgenic mice after immunization, since human splenic marginal zone lymphoma is not related to t(11;18)(q21;q21). Differences between the mouse and human immune systems may be responsible for the unexpected appearance of API2-MALT1-induced lymphoma-like features in the splenic marginal zone rather than other locations. It is also of interest to note that the t(11;18)(q21;q21) has been demonstrated in a human marginal zone lymphoma located in the spleen, although it occurred in splenic dissemination of a gastric MALT lymphoma and not a primary splenic marginal zone lymphoma.⁶ However, in none of the analyzed antigen-exposed transgenic mice was there evidence for the presence of

extranodal location(s) of a marginal zone lymphoma. Moreover, as immunization with Freund's adjuvant did not induce extranodal loci of inflammation,¹⁰ the effect of the API2-MALT1 fusion-protein on B-cell aggregates outside the spleen and lymph nodes could not be investigated.

Interestingly, the morphologic changes in the *API2-MALT1* transgenic mice gradually faded away and disappeared by 12 weeks after administration of Freund's adjuvant. Therefore, we assume that the elimination of the antigenic trigger is sufficient to completely restore the normal splenic architecture with intact compartmentalization of the white pulp. At first sight, this phenomenon may appear very similar to the disappearance of gastric MALT lymphomas after therapy to eradicate *Helicobacter pylori*.¹⁸⁻²⁰ However, regression of gastric MALT lymphomas usually occurs in monoclonal MALT lymphomas that do not carry the t(11;18)(q21;q21). Nevertheless, the reversible, oligo- to polyclonal marginal zone hyperplasia in antigen-exposed, *API2-MALT1* transgenic mice indicates an effect of API2-MALT1 expression on the normal immune response.

XS, TT, CDW-P, PM, MB: involved in the conception and design of the study and in the acquisition, analysis and interpretation of data; CDW-P, PM: involved in the final approval of the version to be submitted; XS, MB: involved in drafting the article and revising it critically for important intellectual content.

Manuscript received May 9, 2006. Accepted August 7, 2006.

References

- Jaffe E, Harris N, Stein H, Vardiman J. World Health Organisation Classification of Tumours: Pathology and Genetics: Tumours of Haemopoietic and Lymphoid Tissues. Lyon, France: IAR Press. 2004.
- Baens M, Steyls A, Geboes K, Marynen P, Wolf-Peeters C. The product of the t(11;18), an API2-MLT fusion, marks nearly half of gastric MALT type lymphomas without large cell proliferation. *Am J Pathol* 2000;156:1433-9.
- Remstein ED, James CD, Kurtin PJ. Incidence and subtype specificity of AP12-MALT1 fusion translocations in extranodal, nodal, and splenic marginal zone lymphomas. *Am J Pathol* 2000; 156:1183-8.
- Sagaert X, Laurent M, Baens M, Wlodarska I, De Wolf-Peeters C. MALT1 and BCL10 aberrations in MALT lymphomas and their effect on the expression of BCL10 in the tumour cells. *Mod Pathol* 2006;19:225-32.
- Streubel B, Simonitsch-Klupp I, Mullaer L, Lamprecht A, Huber D, Siebert R, et al. Variable frequencies of MALT lymphoma-associated genetic aberrations in MALT lymphomas of different sites. *Leukemia* 2004;18:1722-6.
- Dierlamm J, Baens M, Wlodarska I, Stefanova-Ouzounova M, Hernandez JM, Hossfeld DK, et al. The apoptosis inhibitor gene API2 and a novel 18q gene, MLT, are recurrently rearranged in the t(11;18)(q21;q21) associated with mucosa-associated lymphoid tissue lymphomas. *Blood* 1999;93:3601-9.
- Uren AG, O'Rourke K, Aravind L, Pisabarro MT, Seshagiri S, Koonin EV et al. Identification of paracaspases and metacaspases: two ancient families of caspase-like proteins, one of which plays a key role in MALT lymphoma. *Mol Cell* 2000;6:961-7.
- Muller-Hermelink HK. Genetic and molecular genetic studies in the diagnosis of B-cell lymphomas: marginal zone lymphomas. *Hum Pathol* 2003;34:336-40.
- Baens M, Fevery S, Sagaert X, Noels H, Hagens S, Broeckx V, et al. Selective expansion of marginal zone B cells in E mu-API2-MALT1 mice is linked to enhanced I kappa B kinase γ polyubiquitination. *Cancer Res* 2006;66:5270-7.
- Billiau A, Matthys P. Modes of action of Freund's adjuvants in experimental models of autoimmune diseases. *J Leukoc Biol* 2001;70:849-60.
- Maes B, Achten R, Demunter A, Peeters B, Verhoef G, De Wolf-Peeters C. Evaluation of B cell lymphoid infiltrates in bone marrow biopsies by morphology, immunohistochemistry, and molecular analysis. *J Clin Pathol* 2000;53:835-40.
- Fredrickson TN, Lennert K, Chattopadhyay SK, Morse HC, Hartley JW. Splenic marginal zone lymphomas of mice. *Am J Pathol* 1999;154:805-12.
- Morse HC, Anver MR, Fredrickson TN, Haines DC, Harris AW, Harris NL, et al. Bethesda proposals for classification of lymphoid neoplasms in mice. *Blood* 2002;100:246-58.
- Franco V, Florena AM, Iannitto E. Splenic marginal zone lymphoma. *Blood* 2003;101:2464-72.
- Thieblemont C, Felman P, Callet-Bauchu E, Traverse-Glehen A, Salles G, Berger F et al. Splenic marginal-zone lymphoma: a distinct clinical and pathological entity. *Lancet Oncol* 2003;4:95-103.
- Morse HC, Kearney JF, Isaacson PG, Carroll M, Fredrickson TN, Jaffe ES. Cells of the marginal zone-origins, function and neoplasia. *Leukemia Res* 2001; 25:169-78.
- Mahler JF, Stokes W, Mann PC, Takaoka M, Maronpot RR. Spontaneous lesions in aging FVB/N mice. *Toxicol Pathol* 1996;24:710-6.
- Bayerdorffer E, Neubauer A, Rudolph B, Thiede C, Lehn N, Eidt S, et al. Regression of primary gastric lymphoma of mucosa-associated lymphoid-tissue type after cure of *Helicobacter-pylori* infection. *Lancet* 1995;345:1591-4.
- Steinbach G, Ford R, Gloor G, Sample D, Hagemester FB, Lynch PM, et al. Antibiotic treatment of gastric lymphoma of mucosa-associated lymphoid tissue - An uncontrolled trial. *Ann Intern Med* 1999;131:88-95.
- Isaacson PG, Diss TC, Wotherspoon AC, Barbazza R, de Boni M, Dogliani C. Long-term follow-up of gastric MALT lymphoma treated by eradication of *H-pylori* with antibodies. *Gastroenterology* 1999;117:750-1.