

Palifermin as treatment in dose-intense conventional polychemotherapy induced mucositis

Polychemotherapy or radiation frequently causes oral mucositis. Until now, only supportive options are available. Palifermin, a recombinant form of the human keratinocyte growth factor can avoid mucositis in patients treated with myeloablative polychemotherapy for allogeneic stem cell transplantation. Here, we present a patient treated with dose-intense conventional polychemotherapy suffering from severe mucositis leading to additional hospitalization. By using palifermin, the mucositis as well as further admissions were totally prevented. Furthermore, application in subsequent chemotherapy cycles demonstrated a safe and efficacious use. Hence, treatment with palifermin can prevent severe mucositis in a patient treated with dose-intense conventional polychemotherapy.

Haematologica 2006; 91:(7)e90-e91

Patients with haematological malignancies receiving high dose chemotherapy combined with radiation and autologous or allogeneic stem cell transplantation (SCT) frequently suffer from oral mucositis. Also patients with solid tumors of the neck or mediastinal tumors treated by local radiation are susceptible to mucositis. The severe effects of mucositis including oral pain, disability to swallow and an increased risk for infections often lead to additional hospitalization.¹

Palifermin (Kepivance™), a recombinant form of the human keratinocyte growth factor, serves as a protection agent for epithelial cells. In a multi-center doubled blind phase III study Spielberger et al. demonstrated a safe and effective use of palifermin in patients (majority of patients had non-Hodgkin's lymphoma or Hodgkin's disease) given before and after myeloablative chemotherapy, leading to the recent approval of palifermin in that setting.²

Certain non-myeloablative chemotherapy regimens containing antimetabolites, anthracyclines or taxanes frequently cause mucositis. Until now, no data are available about the efficacy of palifermin in the non-SCT setting.

A 47 year old female patient was admitted with

Table 1. Parameters of hospitalization.

Hospitalization	I (following block A1)	II (following block B1)	III (following block C1)
Stay in hospital (days)	5	6	5
Reason	Mucositis	Mucositis	Anal fissure
Duration of symptoms, use of narcotics (days)	3	5	4
WHO grade of mucositis	III	IV	-
Total parenteral nutrition (days)	0	5	3
Cumulative dosage of opioid analgesics (milligrams of morphine equivalents)	100	150	450

swelling of the face and vena cava superior syndrome. Work up revealed a mediastinal high grade B cell lymphoma with bulky disease. An aggressive polychemotherapy according to the GMALL B-ALL/ NHL 2002 protocol of the German leukaemia study group was initiated. The protocol consists of three sequential blocks A, B and C repeating after one full cycle. Block change is recommended three weeks after the previous block. Every block is designed in 6 days containing rituximab (375 mg/m² day 1), dexamethason (10 mg/m² day 2-6) and methotrexate (1500 mg/m² day 2). In particular, block A contains additional vincristin (2 mg day 2), ifosfamide (800 mg/m² day 2-6), cytarabine (2x150 mg/m² day 4-6) teniposide (100 mg/m² day 5-6), block B vincristin (2 mg day 2), cyclophosphamide (200 mg/m² day 2-6), adriamycin (25 mg/m² day 5-6) and block C vindesin (3 mg/m² day 2), cytarabine (2x2000 mg/m² day 6) and etoposide (250 mg/m² day 5-6).

All blocks of chemotherapy have been well tolerated. However, following block A1 and B1, respectively, the patient was readmitted few days after hospital discharge due to severe mucositis and fever. Clinical assessment and physical examination revealed an oral mucositis WHO grade III on first readmission and WHO grade IV on the second readmission. Parenteral nutrition, antibiot-

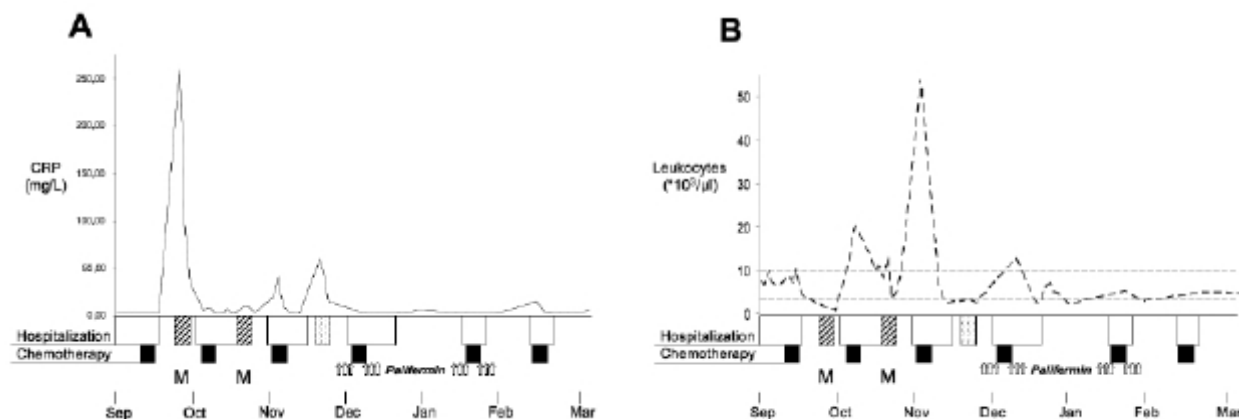


Figure 1. Hospitalization, chemotherapy and application of palifermin over the time. No additional hospitalization because of mucositis or other complications after administration of palifermin. A. Course of C-reactive protein. B. Course of leukocytes. Solid line: Course of C-reactive protein. Dashed line: Course of leukocytes. Dashed horizontal lines depict normal range of leukocytes. M: Mucositis. Open boxes: Hospital stay. Black boxes: Application of chemotherapy. Dashed boxes: Hospitalization due to mucositis. Dotted box: Hospitalization due to infection and anal fissure. Arrows: Application of palifermin over three days before and after chemotherapy.

ic therapy and opioid pain medication was initiated. Few days later the mucositis was controlled and the patient could be discharged again (Table 1).

After block C1 the patient was not admitted because of mucositis, but due to a painful anal fissure and infection. Again an antibiotic therapy and pain medication led to improvement. In summary, after each block of chemotherapy the patient was hospitalized because of severe damage to the mucosa; each time antibiotic and opioid therapy was necessary.

For the second cycle of Block A2 and B2 we chose to use palifermin. The lack of mucositis after block C1 prompted us to refrain from Palifermin in Block C2.

The dosing of palifermin was made according to the study by Spielberger et al.¹ Therefore, over three consecutive days a single intravenous dose of palifermin 60 µg/kg was applied three days before and after chemotherapy, respectively (A2 and B2) (Figure 1, arrows). A time difference of 24 hours between palifermin and chemotherapy application and also reapplication of palifermin 24 hours after end of chemotherapy was used. There was no dose reduction for the chemotherapy itself.

Interestingly, the patient did not suffer from any mucositis nor was hospitalization needed.

After completion of the chemotherapy regimen CT scans revealed complete remission. The patient was transferred to the Department of Radiation Oncology for mediastinal radiation.

In conclusion, we present the first time that the application of palifermin can abrogate clinical symptoms of mucositis and avoid additional hospitalizations in a patient with high grade lymphoma receiving non-myeloablative polychemotherapy. Furthermore, we demon-

strate the first case, where the use of palifermin was safely and efficaciously in subsequent chemotherapy cycles.

Thus, palifermin seems to be a promising therapy approach as treatment in dose-intense conventional polychemotherapy induced mucositis.

Hueber Axel J., Leipe Jan, Roesler Wolf, Kalden Joachim R., Kallert Stefan, Rech Juergen

*Department of Internal Medicine III,
University of Erlangen – Nuremberg*

Correspondence: Dr. A. Hueber

Department of Internal Medicine III

University of Erlangen - Nuremberg

Universitätsstr. 12; 91054 Erlangen, Germany

Tel: ++49-(0)9131-853-3430; Fax: ++49-(0)9131-8534750.

E-mail: axel.hueber@med3.imed.uni-erlangen.de

Key words: Palifermin, dose-intense chemotherapy, mucositis

References

1. Radtke ML, Kolesar JM. Palifermin (Kepivance) for the treatment of oral mucositis in patients with hematologic malignancies requiring hematopoietic stem cell support. *J Oncol Pharm Pract.* 2005 Sep;11(3):121-5.
2. Stiff PJ, Emmanouilides C, Bensinger WI, Gentile T, Blazar B, Shea TC, Lu J, Isitt J, Cesano A, Spielberger R. Palifermin Reduces Patient-Reported Mouth and Throat Soreness and Improves Patient Functioning in the Hematopoietic Stem-Cell Transplantation Setting. *J Clin Oncol.* 2006 Jan 3; [Epub ahead of print].