

Malignant Lymphomas

Primary cutaneous CD4⁺/CD56⁺ hematodermic neoplasm (blastic NK-cell lymphoma): a report of five cases

CD4⁺/CD56⁺ hematodermic neoplasm (WHO-EORTC) or blastic NK-cell lymphoma (WHO) is a rare aggressive CD4⁺CD56⁺lin⁻ skin-tropic lymphoma of putative early-plasmacytoid dendritic cell origin. We present five cases to highlight the need for greater awareness of this entity amongst pathologists such that aggressive treatment be considered given the generally poor prognosis.

Haematologica 2006; 91:143-144

(<http://www.haematologica.org/journal/2006/01/143.html>)

Recently classified as CD4⁺/CD56⁺ hematodermic neoplasm¹ (WHO-EORTC), the aggressive CD4⁺/CD56⁺ NK blastic lymphoma (WHO) included within the CD30 negative cutaneous lymphomas (EORTC) was believed to derive from natural killer (NK) cells. Evidence now suggests, however, an early plasmacytoid type 2 dendritic cell (DC2) origin.^{2,3} Cases characteristically demonstrate a CD4⁺CD56⁺ lineage-negative immunophenotype and unlike NK-nasal and nasal-type lymphoma, absence of detectable Epstein-Barr virus (EBV) genome.³

Primarily affecting elderly adults^{3,4} and often confined to the skin at presentation,⁵ progression to more generalized disease, despite initial responses to local and systemic therapy, is almost invariable. Cutaneous disease may be the

first detected manifestation of systemic disease in blood, bone marrow, lymph node and other organs⁵ including the central nervous system (CNS).¹

We describe our experience in managing five new cases of CD4⁺/CD56⁺ hematodermic neoplasm referred to our Institute between 1997 and 2003. Five males (median age 74 years, range 63-90) (Table 1) presented with solitary or multicentric cutaneous lesions on the scalp, trunk or extremities. These lesions were erythematous or hyperpigmented nodules. Comprehensive staging demonstrated skin-limited disease in all cases. All cases received an amended pathological diagnosis on review. Skin biopsies demonstrated a lymphoid infiltrate involving the dermis and subcutis but sparing the epidermis (Figures 1A and B). Cytologically, the malignant cells appeared as abnormal medium-sized lymphoid cells with an absence of cytoplasmic azurophilic granules (Figure 1B). Angiocentricity and necrosis were not noted. Immunohistochemical staining demonstrated a CD3 and CD20 negative but CD56 positive malignant cell population in all cases. CD4 staining was positive in four with the remaining case demonstrating CD4 positive cells on peripheral blood flow cytometric analysis at relapse. CD43 was positive in the four of five cases tested. Epstein-Barr virus *in situ* hybridization on skin biopsy specimens was negative in all cases. Molecular studies demonstrated polyclonal T-cell receptor gene rearrangement in all four cases tested (Table 1). Flow cytometric analysis of bone marrow aspirate and/or peripheral blood at relapse in two patients demonstrated a CD4, CD56 and CD43 positive population of malignant cells, which were CD3, B-cell antigen and myeloid antigen negative (Table 1). Three patients treated with front-line combination chemotherapy, two with CHOP and one with

Table 1. Summary of cases CD4⁺/CD56⁺ hematodermic neoplasm.

Case/Sex/ Age (y)	Skin lesions at presentation	Initial Diagnosis	Staging at diagnosis (immunohistochemical and molecular characteristics)	Initial treatment	Response	Relapse	Immunohistochemical and molecular features at relapse	Time to relapse (months)	Outcome and survival from diagnosis (months)
1/Male/ 90	Solitary red oval nodule left forearm	CD30 ⁺ CTL ¹	Skin only (CD3 ⁺ , CD30 ⁺ , CD20 ⁻ , CD4 ⁺ , CD56 ⁺ , CD45RA ⁺ , MPO ⁻ , TdT ⁻ , EBV ISH ⁻ , TCR ⁺ poly ⁴)	Topical steroid, radiotherapy	CCR ⁶	Skin, lymph node, peripheral blood, bone marrow	Blood ⁶ (MPO ⁻ , CD3 ⁻ , CD20 ⁻ , CD4 ⁺ , CD56 ⁺ , TCR poly)	15	Died, Progressive disease, 22
2/Male/ 63	Multicentric red nodules left scapula and satellite nodules	CD30 ⁺ CTL	Skin only (CD3 ⁺ , CD30 ⁺ , CD4 ⁺ , CD56 ⁺ , CD45RA ⁺ , MPO ⁻ , ALK ⁻ , EBV ISH ⁻)	CHOP ⁵	CCR	NA	NA	NA	Alive, 27 [*]
3/Male/ 74	Multicentric red nodules back, forehead, legs	Mycosis fungoides	Skin only (CD3 ⁺ , CD30 ⁺ , CD20 ⁻ , CD4 ⁺ , CD56 ⁺ , CD45RA ⁺ , MPO ⁻ , EBV ISH ⁻)	Chlorambucil, Radiotherapy	PR ⁷	Skin, lymph node, bone marrow Central nervous system	Bone marrow ⁶ (MPO ⁻ , TdT ⁻ , ALK ⁻ , CD3 ⁻ , CD10 ⁻ , CD4 ⁺ , CD56 ⁺)	1	Died, Post surgical complication, 12
4/Male/ 68	Multicentric nodules scalp, left leg. Plaque-like deposits abdomen	CD30 ⁺ CTL	Skin only (CD3 ⁺ , CD30 ⁺ , CD20 ⁻ , CD4 ⁺ , CD56 ⁺ , CD45RA ⁺ , MPO ⁻ , ALK ⁻ , TdT ⁻ , EBV ISH ⁻)	HyperCVAD ⁵	CCR	NA	NA	NA	Alive, 38 ⁺
5/Male/ 75	Multicentric red nodules right shoulder	Anaplastic large cell lymphoma	Skin only (CD3 ⁺ , CD30 ⁺ , CD20 ⁻ , CD4 ⁺ , CD56 ⁺ , CD43 ⁺ , CD45RA ⁺ , MPO ⁻ , ALK ⁻ , EBV ISH ⁻ , TCR poly)	CHOP ⁵	CCR	Skin right thigh, Skin right chest	Skin (CD3 ⁺ , CD30 ⁺ , CD20 ⁻ , CD4 ⁺ , CD56 ⁺ , CD43 ⁺ , MPO ⁻ , TdT ⁻ , EBV ISH ⁻ , TCR poly)	17	Alive, 29 ⁺

¹CD30 negative cutaneous T cell lymphoma; ²Epstein-Barr virus *in situ* hybridization; ³T-cell receptor gene rearrangement; ⁴polyclonal rearrangement; ⁵central nervous system prophylaxis with intrathecal methotrexate and intermediate dose systemic methotrexate was administered; ⁶clinical complete response defined as complete (100%) cutaneous remission; ⁷partial response defined as > 50% but < 100% improvement; ⁸additional antibodies: ^aCD 2- 7+ 19- ^bCD 2- 19- 13- 33+ 117-.

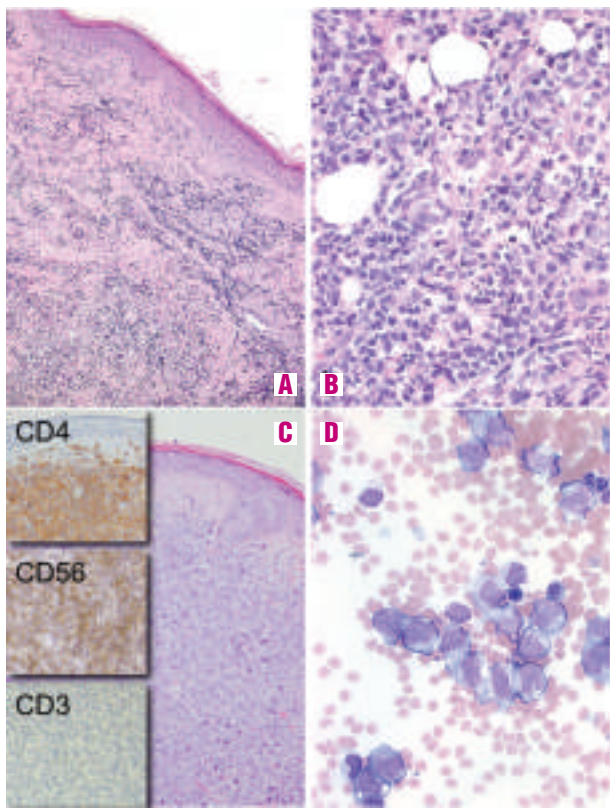


Figure 1. A. Skin biopsy (x100 magnification) Dense dermal infiltrate sparing the epidermis. B. Skin biopsy (x400 magnification) Dense dermal infiltrate of abnormal medium-sized lymphoid cells. C. Skin biopsy (x200 magnification) Immunohistochemical staining. D. Bone marrow aspirate (x400 magnification). Relapsed disease with frank leukemic bone marrow infiltration.

HyperCVAD,⁶ achieved a clinical complete response and remain alive. Due to the risk of CNS relapse,⁷ prophylaxis with intrathecal chemo-prophylaxis and intermediate-dose systemic methotrexate was administered. One patient received consolidative radiotherapy to skin lesions. One patient relapsed with multicentric skin disease after 17 months of remission (Table 1). Two patients treated principally with local radiotherapy because of anticipated intolerance to systemic chemotherapy relapsed, one after 15 months and the other after 1 month, with cutaneous lesions outside treated radiotherapy fields, lymphadenopathy, systemic symptoms and marrow involvement. Cerebrospinal fluid analysis showed that one patient had CNS involvement. Both patients died within 6 months of relapse, one from progressive disease and one from post-surgical complications following ommaya reservoir insertion.

CD4⁺/CD56⁺ hematodermic neoplasm accounts for 0.7% of cutaneous lymphomas.⁵ Survival is often short despite initial limited-stage disease and treatment with systemic chemotherapy.^{4,5} The newer EORTC-WHO classification differentiates CD4⁺/CD56⁺ hematodermic neoplasm from forms of extranodal lymphoma, leukemia cutis and acute leukemia. Characteristic but non-specific clinical, histological, immunophenotypic and molecular features are noted. Comprehensive clinical and pathological correlation may, potentially be assisted by newer immunological dendritic cell markers such as CD123,⁸ BDCA-2, BDCA-3 and BDCA-4⁹ on flow cytometric analysis and TCL-1 and CLA¹⁰ on immunohistochemical staining. We recommend CD4 and CD56 immunohistochemistry be performed for cases of cutaneous lymphoma in which malignant cells are CD3

negative. Atypical features should also not exclude the diagnosis, as demonstrated by one patient in our series who was CD4 negative on skin biopsy immunohistochemistry and CD4 positive on flow cytometry at relapse.

Leukemic variants should be suspected on flow cytometric analysis if gated blasts are negative for myeloperoxidase and TdT¹ and by a CD4⁺CD56⁺lin-phenotype. CD123 may be a useful affirmative marker. Cytogenetic aberrations are not diagnostic.⁵ Although optimal therapy remains unknown and delivery of aggressive therapy is often limited by advanced age and co-morbidities, our series suggests systemic chemotherapy should be considered in appropriate patients, since this strategy produced two remissions lasting over 2 years. One of these patients, a recipient of HyperCVAD, remains disease-free at 38 months. The role of allogeneic transplantation remains to be defined.

Accurate pathological diagnosis of CD4⁺/CD56⁺ hematodermic neoplasm is essential for prognosis and treatment. Previous EORTC and WHO classifications of cutaneous lymphomas fail to clearly differentiate this entity and it is therefore recommended that the recently published WHO-EORTC classification of cutaneous lymphoma is adopted.

Ashley P Ng,* Stephen Lade,* Timothy Rutherford,^o Christopher McCormack,^o H Miles Prince,* David A Westerman*
^{*}Division of Haematology & Medical Oncology, Peter MacCallum Cancer Centre and University of Melbourne, Melbourne, Victoria, Australia; ^oDepartment of Dermatology, St Vincent's Hospital, Melbourne, Victoria, Australia

Acknowledgments: Dr. John Scarlett for his assistance in ongoing patient care.

Key words: cutaneous lymphoma, hematodermic, NK blastic.

Correspondence: H Miles Prince, Chair, Haematology Service, Director, Blood and Marrow Transplant Program, Peter MacCallum Cancer Centre, Locked Bag 1, A'Beckett St, Melbourne 8006, Australia. Phone: international +61.3.96561700. Fax: international+61.3.96561408. E-mail: miles.prince@petermac.org

References

1. Willemze R, Jaffe ES, Burg G, Cerroni L, Berti E, Swerdlow SH, et al. WHO-EORTC classification for cutaneous lymphomas. *Blood* 2005;105:3768-85.
2. Chaperot L, Bendriss N, Manches O, Gressin R, Maynadie M, Trimoreau F, et al. Identification of a leukemic counterpart of the plasmacytoid dendritic cells. *Blood* 2001;97:3210-7.
3. Feuillard J, Jacob MC, Valensi F, Maynadie M, Gressin R, Chaperot L, et al. Clinical and biologic features of CD4⁺CD56⁺ malignancies. *Blood* 2002;99:1556-63.
4. Bekkenk MW, Jansen PM, Meijer CJ, Willemze R. CD56⁺ hematological neoplasms presenting in the skin: a retrospective analysis of 23 new cases and 130 cases from the literature. *Ann Oncol* 2004; 15:1097-108.
5. Petrella T, Bagot M, Willemze R, Beylot-Barry M, Vergier B, Delaunay M, et al. Blastic NK-cell lymphomas (agranular CD4⁺CD56⁺ hematodermic neoplasms). *Am J Clin Pathol* 2005; 123:662-75.
6. Kantarjian HM, O'Brien S, Smith TL, Cortes J, Giles FJ, Beran M, et al. Results of treatment with hyper-CVAD, a dose-intensive regimen, in adult acute lymphocytic leukemia. *J Clin Oncol* 2000;18:547-61.
7. Chua SL, Seymour JF, Prince HM. Deafness from eighth cranial nerve involvement in a patient with large-cell transformation of mycosis fungoides. *Eur J Haematol* 2000;64:340-3.
8. Trimoreau F, Donnard M, Turlure P, Gachard N, Bordessoule D, Feuillard J. The CD4⁺ CD56⁺ CD116⁺ CD123⁺ CD45RA⁺ CD45RO⁻ profile is specific of DC2 malignancies. *Haematologica* 2003; 88:ELT10.
9. Dzionek A, Fuchs A, Schmidt P, Cremer S, Zysk M, Miltenyi S, et al. BDCA-2, BDCA-3, and BDCA-4: three markers for distinct subsets of dendritic cells in human peripheral blood. *J Immunol* 2000;165:6037-46.
10. Petrella T, Meijer CJ, Dalac S, Willemze R, Maynadie M, Machet L, et al. TCL1 and CLA expression in agranular CD4⁺/CD56⁺ hematodermic neoplasms (blastic NK-cell lymphomas) and leukemia cutis. *Am J Clin Pathol* 2004;122:307-13.