

Bortezomib-induced Sweet's syndrome

Sweet's syndrome is an uncommon acute skin disease, associated with a variety of medical problems. The drug-induced variant is even rarer. We describe two cases of this syndrome associated with the administration of the proteasome inhibitor bortezomib. The diagnostic criteria for drug-induced Sweet's syndrome as proposed by Walker and Cohen were fulfilled. Vasculitis and neutrophilic eccrine hidradenitis were excluded.

Haematologica 2005; 90(12):e116-e117

Sweet's syndrome or acute febrile neutrophilic dermatosis is an infrequent skin disease characterized by sudden onset of fever, leucocytosis and erythematous plaques or nodules infiltrated by neutrophils.¹ There is an association with a variety of medical problems and drugs. Treatment with systemic corticosteroids usually brings prompt clinical improvement. We describe two patients who developed this syndrome after administration of the proteasome inhibitor bortezomib. As far as we know, this relationship has never been described.

Cases

The first patient is a 70-year-old male who was diagnosed with a multiple myeloma IgG lambda earlier this year. He was included in an international study (VISTA) involving the use of bortezomib (1.3 mg/m²) in first line. The study involves the use of cycles of eight administrations. During one cycle bortezomib is given twice a week for two weeks followed by the same regimen after a resting period of ten days. There is again a resting period of ten days between the cycles. In summary this means that bortezomib is administered on day 1, 4, 8, 11, 22, 25, 29 and 32, the last day of the cycle. On day one of each cycle, oral melphalan (9 mg/m²/d) and prednisolone (60 mg/m²/d) are concomitantly given for four days. The first cycle was generally well tolerated until the patient developed a papulo-nodular eruption on the chest and the back twelve hours after the seventh administration of bortezomib in the first cycle (Figure 1). The eruption was neither tender nor painful, but was described as intermittently itchy. There was an initial period of fever (>38°C), but temperature was not checked regularly afterwards. There was an abrupt rise in erythrocyte sedimentation rate (61), but no leucocytosis. Histopathological examination of the lesions showed a dermal neutrophilic interstitial and perivascular infiltrate, accompanied by the formation of nuclear dust (karyorrhexis) (Figure 2). There was no evidence of fibronoid necrosis of the vascular wall and the infiltrate was perivascular rather than intravascular. On the morphological basis the criteria for the diagnosis of vasculitis were not fulfilled. The diagnosis of Sweet's syndrome was made. The lesions were treated with topical clobetasol propionate 0,05% cream. Considering the importance of the treatment, the therapy was continued and the last bortezomib infusion of the first cycle was given on schedule. When we saw the patient back ten days later at the start of the second cycle the lesions were completely resolved. The day after the sixth administration of the second cycle he developed identical, but more extensive lesions on the chest and the back. This time fever was not present, but again a rise in inflammatory parameters was noted. At this time we decided to administer each bortezomib infusion under a protective dose of 80 mg methylprednisolone intra-

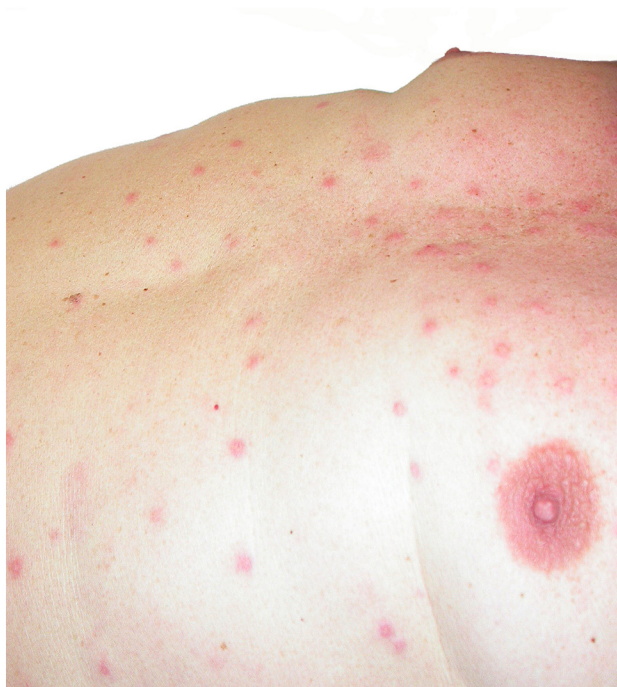

Figure 1.

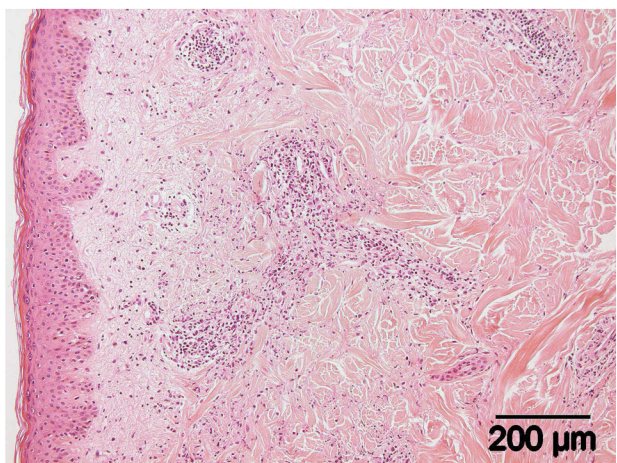


Figure 2.

venously. The lesions were not seen again. At the time of writing, the patient is near the end of the third cycle with good response on his paraprotein. The dose of bortezomib had to be diminished due to polyneuropathy. Other adverse events were a painful left testicle, diarrhea, fatigue, insomnia and erectile problems.

The second patient is a 58-year-old male with multiple myeloma IgG lambda since 2004. After an unsuccessful treatment with VAD (vincristine-adriamycine-dexamethasone), cyclofosamide-etoposide and thalidomide, bortezomib was initiated in a regimen as outlined in our first patient, but without the concomitant use of melphalan-prednisolone during the first four days. A few hours after the third dose of bortezomib in the first cycle, the patient developed 38°C fever and a tender papulo-nodular eruption on the chest and the back. On the forehead painless nodular lesions were noted. The biopsy showed a moderately dense perivascular infiltrate of lymphocytes and neutrophils with karyorrhexis. There was no infiltra-

tion of the eccrine sweat glands. Vasculitis could be histopathologically excluded. High dose methylprednisolone caused quick improvement. 80 mg methylprednisolone IV was associated with the following bortezomib administrations in this cycle and the eruption did not reappear. The second, third and fourth dose of bortezomib of the second cycle were not given with concomitant steroids, early after this fourth dose the eruption reappeared extensively. The painless nodules on the forehead seemed not to respond to steroids. A biopsy of these lesions was not performed. Also this patient also complained of testicular pain associated with bortezomib. Paraprotein improved under the therapy.

Discussion

We describe two cases of drug-induced Sweet's syndrome associated with the administration of bortezomib. Bortezomib (Velcade®) is the first of the new class of medication called proteasome inhibitors. It appears to act directly on important intracellular processes, such as the nuclear factor kappa B (NFκ-B) pathway, to cause cell death. Indirectly it inhibits growth and survival by acting on the bone environment.² Very promising results are reported with the use of bortezomib in refractory multiple myeloma³ and studies on the use of the drug in second and even first line are on their way. Undesirable effects on skin and subcutaneous tissue reported with bortezomib are plenty. Rash is very commonly reported (>1/10), while pruritus, erythema, periorbital edema, urticaria, pruritic rash, increased sweating, dry skin, eczema are commonly (>1/100, <1/10) described. Night sweats, erythematous rash, alopecia, contusion, generalised pruritus, macular rash, papular rash, skin nodules, generalised rash, dermatitis, eyelid oedema, nail disorders, photosensitivity reaction, skin discolouration, atopic dermatitis, hair texture abnormalities, heat rash, psoriasis, vasculitic rash, face oedema, pressure sore and ichthyosis are uncommon (>1/1000, <1/100) under the treatment.

Sweet's syndrome is also termed acute febrile neutrophilic dermatosis, due to its presentation with acute onset of fever, leucocytosis and erythematous plaques infiltrated by neutrophils. The lesions tend to occur on the trunk, extremities, face and neck.¹ It is a reactive process and is found in association with a variety of medical problems which may include malignancies, infection, systemic disorders and inflammatory bowel disease and in many haematological diseases.⁴ It generally responds dramatically to oral corticosteroids.

An uncommon form is the drug-induced Sweet's syndrome, attributed to medication, including all-trans retinoic acid and granulocyte colony-stimulating factor.⁵ Walker et al proposed separate criteria for drug-induced Sweet's syndrome.⁶ These are: -1- acute onset of painful erythematous plaques or nodules; -2- dermal neutrophilic infiltrate without evidence of vasculitis on histopathological examination; -3- pyrexia > 38°C; -4- temporal relationship between drug ingestion and clinical presentation or temporally-related recurrence after rechallenge; -5- temporally related resolution of lesions after drug withdrawal or treatment with systemic corticosteroids. All

these criteria were fulfilled in both patients, except that the first patient did not describe the lesions as painful. The reason why recurrence of the lesions in the first case was late in the second cycle is probably due to the concomitant use of high dose steroids during the first days of each cycle. Histopathologically, a neutrophilic eccrine hidradenitis could be excluded from the differential diagnosis since the eccrine glands were not involved in the inflammatory process. There was no evidence of a leucocytoclastic vasculitis, since there was no evidence of fibronoid necrosis of the vascular wall and the infiltrate was perivascular rather than intravascular, although it cannot be excluded that the concurrent corticoid therapy has influenced both the clinical and pathological manifestation of this drug mediated skin disease. The fact that we see this complication rather late after development of the drug and after completion of many large studies may be due to the use of bortezomib in earlier stages of the disease, like the VISTA-study. It is perfectly possible that the clinical picture of this drug-mediated skin disease was modified by the use of concomitant or earlier immunomodulating therapies.

Both of our patients reported testicular pain, which is a known, but uncommon (1/100 – 1/1000) side effect of bortezomib of which the mechanism is not clear. Since treatment with bortezomib is very commonly associated with peripheral neuropathy, we presume it is an atypical expression hereof. It is probably a coincidence that both these patients suffered from this problem.

Conclusion

To our knowledge, this one of the first reports of drug-induced Sweet's syndrome associated with the new class of proteasome inhibitors. Since prompt treatment with corticosteroids proved to be highly effective and allows the continuation of bortezomib, early recognition of the clinical picture is extremely important.

Van Regenmortel N,¹ Van de Voorde K,² De Raeve H,³ Rombouts S,² Van de Velde A,¹ Lambert J,³ Schroyens W¹

¹Division of Haematology, Antwerp University Hospital

²Division of Dermatology, Antwerp University Hospital

³Department of Pathology, Antwerp University Hospital

Key Words: Sweet's syndrome, bortezomib, drug-induced, papulonodular eruption, multiple myeloma

References

1. Sweet RD. An acute febrile neutrophilic dermatosis. *Br J Dermatol.* 1964; 76:349-56
2. Kyle RA, Rajkumar SV. Multiple myeloma - Drug therapy. *N Engl J Med.* 2004; 351:1860-73
3. Richardson PG, Barlogie B, Berenson J, Singhal S, Jagannath S,
4. Cohen P, Kurzrock R. Sweet's syndrome revisited: a review of disease concepts. *Int J Dermatol.* 2003; 42:761-78
5. Saez M, Garcia-Bustinduy M, Noda A, Dorta S, Escoda M, Fagundo E, et al. Drug-induced Sweet's syndrome. *J Eur Acad Dermatol Venereol.* 2003; 18:233
6. Walker D, Cohen P. Trimethoprim-sulfamethoxazole-associated acute febrile neutrophilic dermatosis: Case report and review of drug-induced Sweet's syndrome. *J Am Acad Dermatol.* 1996; 34:918-23