



[haematologica]
2004;89:957-964

Leukocyte-specific phosphoprotein-1 and PU.1: two useful markers for distinguishing T-cell-rich B-cell lymphoma from lymphocyte-predominant Hodgkin's disease

TERESA MARAFIOTI
CRISTINA MANCINI
STEFANO ASCANI
ELENA SABATTINI
PIER LUIGI ZINZANI
MICHELA POZZOBON
KAREN PULFORD
BRUNANGELO FALINI
ELAINE S. JAFFE
HANS-KONRAD MÜLLER-HERMELINK
DAVID Y. MASON
STEFANO A. PILERI

Correspondence: Professor Stefano Aldo Pileri, Chair of Pathology and Unit of Hematopathology, Institute of Haematology "L. & A. Seràgnoli", University of Bologna, via Massarenti 9, I-40138 Bologna, Italy. E-mail: pileri@med.unibo.it

From the Nuffield Department of Clinical Laboratory Sciences, John Radcliffe Hospital, University of Oxford, Oxford, United Kingdom (TM, KP, DYM); Chair of Pathology and Unit of Haematopathology, Institute of Haematology and Clinical Oncology "L & A Seràgnoli", Bologna University, Bologna, Italy (CM, SA, ES, SAP); Institute of Haematology and Clinical Oncology "L & A Seràgnoli", Bologna University, Bologna, Italy (PLZ); Leukaemia Research Fund Immunodiagnosics Unit, Nuffield Department of Clinical Laboratory Sciences, John Radcliffe Hospital, Oxford, United Kingdom (MP); Haematopathology, Department of Haematology, Monteluce Hospital, Perugia University, Perugia, Italy (BF); Laboratory of Pathology, National Cancer Institute, Bethesda (ESJ); Institute of Pathology, University of Würzburg, Würzburg, Germany (HKMH).

@2004, Ferrata Storti Foundation

A B S T R A C T

Background and Objectives. T-cell-rich B-cell lymphoma is a rare variant of diffuse large B-cell lymphoma. It shows morphologic, phenotypic and molecular similarities to lymphocyte predominant Hodgkin's disease, and in consequence the two diseases may sometimes be difficult to distinguish. In this paper, we have evaluated the usefulness of the pan-leukocyte marker LSP1 and the transcription factor PU.1 for resolving such diagnostic problems.

Design and Methods. Immunohistochemical techniques were used to investigate the expression of LSP1 and PU.1 in 34 tumors, comprising typical examples of T-cell-rich B-cell lymphoma (15 cases), lymphocyte-predominant Hodgkin's disease (13 cases), and lymphocyte-rich classical Hodgkin's disease (6 cases).

Results. The neoplastic cells of T-cell-rich B-cell lymphoma were LSP1-positive and PU.1-negative, whereas the lymphocytic and/or histiocytic (L&H) cells of lymphocyte-predominant Hodgkin's disease were mostly LSP1-negative, with variable PU.1 expression. The two markers did not discriminate between T-cell-rich B-cell lymphoma and lymphocyte-rich classical Hodgkin's disease, whilst they concurred to the distinction between lymphocyte-predominant and lymphocyte-rich classical Hodgkin's disease by integrating the already available tools.

Interpretation and Conclusions. Antibodies to LSP1 and PU.1 may represent useful reagents for the differential diagnosis between T-cell-rich B-cell lymphoma and lymphocyte-predominant Hodgkin's disease.

Key words: T-cell-rich B-cell lymphoma, lymphocyte-predominant Hodgkin's disease, lymphocyte-rich classical Hodgkin's disease, LSP1, PU.1, phenotype, diagnosis.

T-cell-rich B-cell lymphoma represents a rare variant of diffuse large B-cell lymphoma, characterized by the presence of only a few neoplastic cells within a background of reactive T cells and/or histiocytes.¹⁻⁹ The tumor cells may, on occasion, morphologically resemble the lymphocytic and/or histiocytic (L&H) cells of lymphocyte-predominant Hodgkin's disease, making the distinction between the two diseases difficult.^{3,9-13} This morphologic similarity is not surprising, given the evidence from single-cell polymerase chain reaction (PCR) studies that the neoplastic cells in both tumors share a common derivation from germinal center cells, as shown by highly mutated clonal immunoglobulin genes, intraclonal diversity and functional in-frame immunoglobulin rearrangements.¹⁴⁻¹⁶ The distinction between the two diseases is, however, clinically important, since they run completely

different courses (aggressive vs. indolent) and require different therapies.^{10,17-19} A number of morphologic, phenotypic and cytogenetic features that can assist in the differential diagnosis have been proposed,^{3,9-13,20,21} but none of them seems to be entirely specific.²² Recently, however, it has been reported in a small series of cases that the transcription factor PU.1 is down-regulated in T-cell-rich B-cell lymphoma compared with in lymphocyte-predominant Hodgkin's disease.^{23,24} PU.1 regulates the transcription of genes relevant to the development of B cells, macrophages and myeloid cells.^{25,26} Furthermore, it has been reported that the leukocyte-specific phosphoprotein (LSP1) is present in the neoplastic cells of most diffuse large B-cell lymphomas, but usually absent in lymphocyte-predominant Hodgkin's disease.²⁷

In this study, we evaluated the expres-

Table 1. Summary of the clinical data in the 30 patients for whom complete information was available.

	<i>T-cell-rich B-cell lymphoma</i> (12/15)	<i>Lymphocyte-predominant Hodgkin's disease</i> (12/13)	<i>Lymphocyte-rich classical Hodgkin's disease</i> (6/6)
Male/Female	9/3	9/3	4/2
Mean age (yrs)	43.4	37.2	25.8
Stage I-II	6/12	12/12	5/6
Stage III-IV	6/12	0	1/6
B symptoms	5/12	1/12	2/6
Bulky disease	5/12	2/12	2/6
Spleen involvement	3/12	1/12	1/6
BM positivity	4/12	0	2/6
First line therapy	12/12	12/12	6/6
Salvage therapy	5/12	1/12	1/6
Complete remission	6/12	12/12	6/6
Died of disease	6/12	0	0
Follow-up period (median)	24 months	48 months	36 months

Table 2. Main phenotypic features of the cases of T-cell-rich B-cell lymphoma, lymphocyte-predominant Hodgkin's disease and lymphocyte-rich classical Hodgkin's disease.

<i>Marker</i>	<i>T-cell-rich B-cell lymphoma</i>	<i>Lymphocyte-predominant Hodgkin's disease</i>	<i>Lymphocyte-rich classical Hodgkin's disease</i>
CD30	3/15	2*/13	6/6
CD15	0/15	0/13	3/6
CD20	15/15	13/13	1*/6
BCL-6	9/15	13/13	0/6
PAX-5/BSAP	11/15	13/13	6/6
BOB.1	14/15	13/13	0/6
OCT-2	12/15	13/13	0/6
MUM-1/IRF4	6/15	10/13	6/6

*Only a few neoplastic cells positive.

sion of these two markers in a series of cases that were regarded as typical examples of T-cell-rich B-cell lymphoma and lymphocyte-predominant Hodgkin's disease, with the aim of establishing the value of the markers for differential diagnosis. In addition, the results were compared with those observed in six cases of lymphocyte-rich classical Hodgkin's disease, which may also cause diagnostic confusion.

Design and Methods

Tissues and clinical data

Thirty-four cases previously diagnosed as typical T-cell-rich B-cell lymphoma (15 cases), lymphocyte-predominant Hodgkin's disease (13 cases), and lymphocyte-rich classical Hodgkin's disease (6 cases) according to the criteria of the REAL and WHO Classifications were retrieved from the files of the Hematopathology Unit of Bologna University.^{5,6,28} In particular, the lym-

phocyte-predominant Hodgkin's disease cases were characterized by the presence of L&H cells, paucity of Hodgkin and Reed-Sternberg cells, CD15 and CD30 negativity, and CD20 expression by neoplastic elements. The tumor growth pattern, evaluated according to Fan *et al.*,²⁹ was recorded in each case, along with the amount of follicular dendritic cells, small B lymphocytes, and T cells (CD57⁺ and -).

The main clinical and phenotypic features of the 34 cases are shown in Tables 1 and 2. The tissue samples had been fixed in 10% buffered formalin, processed according to routine procedures and embedded in paraffin.³⁰

Immunohistochemistry

Five-micron thick sections were cut from paraffin blocks, coated on electrically charged slides, de-waxed and re-hydrated, and then submitted to antigen retrieval by micro-waving in 1mM EDTA (pH 8.0) for 5 minutes at 900 W. This was performed two or three

Table 3. LSP1 and PU.1 expression in T-cell-rich B-cell lymphoma, lymphocyte-predominant Hodgkin's disease and lymphocyte-rich classical Hodgkin's disease.

	LSP1				PU.1			
	+	+/-	-/+	-	+	+/-	-/+	-
T-cell-rich B-cell lymphoma (15)	11	2	2	0	0	0	0	15
Lymphocyte-predominant Hodgkin's disease (13)	2	0	1	10	5	3	2	3
Lymphocyte-rich classical Hodgkin's disease (6)	6	0	0	0	0	0	0	6

+: >95% of tumor cells positive; +/-: 50-75% of tumor cells positive; -/+ : <50% of tumor cells positive; -: all tumor cells negative.

times, depending on the location (cytoplasmic or nuclear) of the antigen.³¹ Slides were then incubated for 30 minutes at room temperature with antibody to LSP1²⁷ and/or PU.1 (clone G148-74, BD PharMingen, USA), at a dilution of 1:10 or 1:50, respectively. Antibody binding was detected either by the alkaline phosphatase anti-alkaline phosphatase (APAAP) technique or the peroxidase-based EnVision+ method.^{32,33} Sections were then counter-stained with hematoxylin. Most immunohistochemical tests were carried out on a TechMate 500 immunostainer.³¹

Double immunoenzymatic and immunofluorescent labeling

Paraffin sections of lymphocyte-predominant Hodgkin's disease cases were de-waxed, re-hydrated and micro-waved as described above. Endogenous peroxidase was blocked using the Peroxidase Blocking Reagent (DakoCytomation, Denmark) for 20 minutes. Sections were then incubated with anti-PU.1 antibody at a dilution of 1:50. After washing in TBS, the slides were incubated with the anti-mouse EnVision™ HRP reagent (DakoCytomation, Denmark). The reaction was then developed using the DAB substrate of the EnVision™ system kit (DakoCytomation, Denmark). After prolonged washing in TBS, anti-CD20 antibody (L26) was applied at a dilution of 1:100, and its binding was detected by the APAAP technique using the New Fuchsin substrate kit (DakoCytomation, Denmark).³² Sections were then washed in tap water and mounted in Aquamount (Merck). All primary and secondary antibody incubations lasted 30 minutes at room temperature. Double immunofluorescence was evaluated in representative cases (two T-cell-rich B-cell lymphomas and two cases of lymphocyte-predominant Hodgkin's disease) using fluorochrome-conjugated anti-Ig reagents (species and/or subclass-specific) obtained from Molecular Probes (Eugene, OR, USA) as previously described.³⁴

Results

The expression patterns of LSP1 and PU.1 in cases of T-cell-rich B-cell lymphomas, lymphocyte-predominant Hodgkin's disease and lymphocyte-rich classical Hodgkin's disease are summarized in Table 3.

LSP1 expression

Strong cytoplasmic LSP1 positivity was seen in all tumor cells in 11 out of 15 T-cell-rich B-cell lymphomas (Figure 1A). In the remaining four cases, LSP1 labeling was found in only a proportion (25 – 75%) of neoplastic cells (Figure 1B).

An opposite pattern was seen in lymphocyte-predominant Hodgkin's disease: in 10/13 cases the tumor cells (i.e. L&H cells) were LSP1-negative (Figure 1C). Of the remaining three cases – all corresponding to the classical variant described by Fan *et al.*²⁹ – one showed LSP1 positivity in a minority of the neoplastic cells (less than 25%), while the other two showed LSP1 expression in most L&H cells (Figure 1D). PU.1 staining was negative in the first of these three cases and positive in the others.

Double immunofluorescent staining in selected cases confirmed that the neoplastic cells were indeed LSP1-positive in T-cell-rich B-cell lymphomas and LSP1-negative in cases of lymphocyte-predominant Hodgkin's disease (Figures 1E and 1F).

Based on the results of a previous study showing strong LSP1 expression in nodular sclerosis,²⁷ mixed cellularity and lymphocyte-depleted classical Hodgkin's disease, we extended the investigation of LSP1 expression to six examples of lymphocyte-rich classical Hodgkin's disease. The CD30-positive Hodgkin and Reed-Sternberg cells (Figure 1G) displayed strong LSP1 positivity at both the cytoplasmic and membrane level (Figure 1H) in all cases.

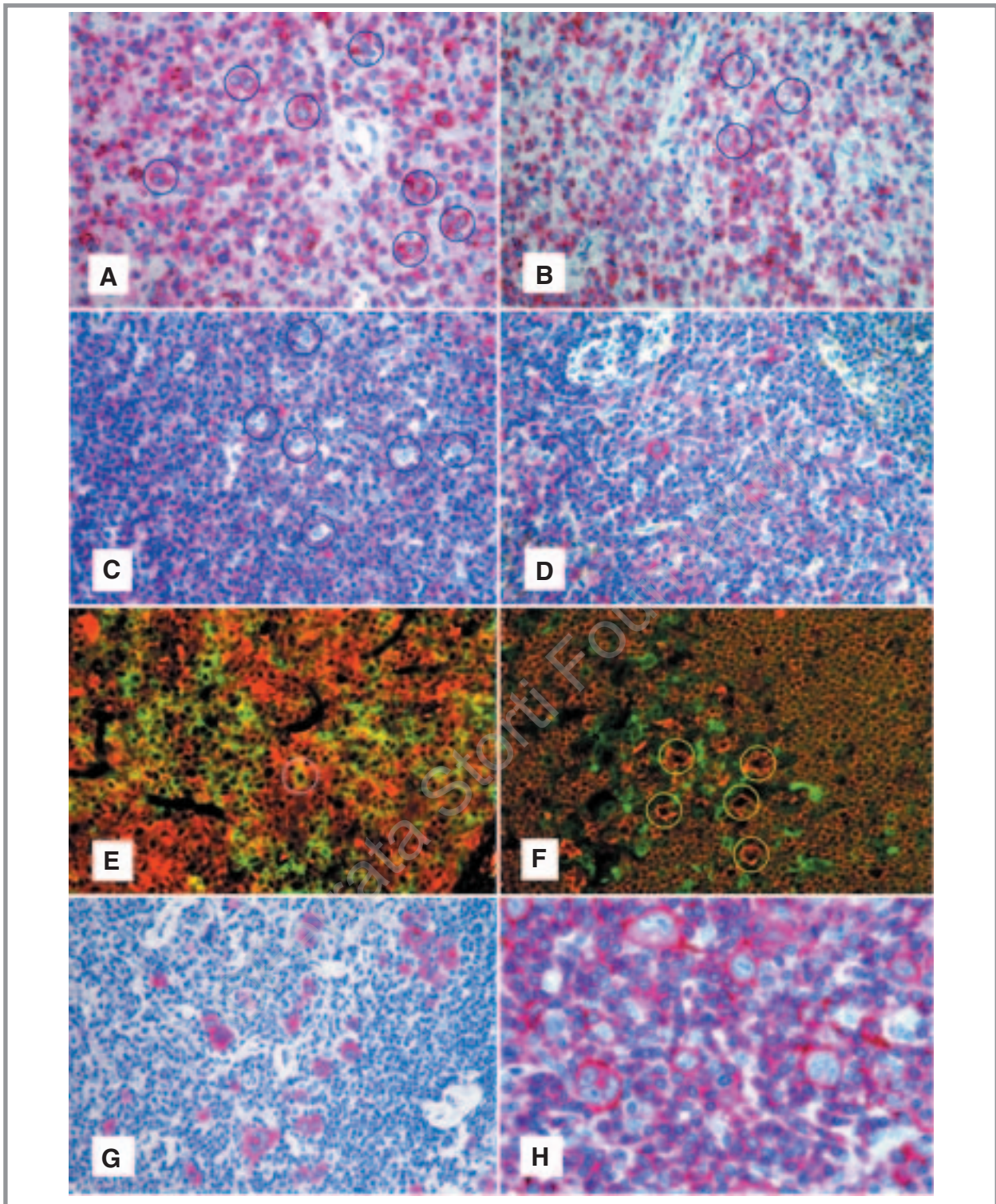


Figure 1. LSP1 expression in T-cell-rich B-cell lymphoma, lymphocyte-predominant Hodgkin's disease and lymphocyte-rich classical Hodgkin's disease. The tumor cells (blue circles) in the majority of the cases of T-cell-rich B-cell lymphoma displayed cytoplasmic and membrane-bound LSP1-positivity (A) with the exception of a few cases in which LSP1 was detected in a minority of the neoplastic elements (blue circles) (B) (APAAP technique, Gill's hematoxylin counterstaining, $\times 250$). L&H cells (blue circles) in most cases of lymphocyte-predominant Hodgkin's disease were LSP1-negative (C), although in single cases they showed strong cytoplasmic LSP1-labeling (D) (APAAP technique, Gill's hematoxylin counterstaining, $\times 250$). Double immunofluorescence for CD20 (red) and LSP1 (green) confirmed that in T-cell-rich B-cell lymphoma the tumor cells co-expressed the two markers (example of double-stained cell encircled) (E), whereas in lymphocyte-predominant Hodgkin's disease L&H cells (yellow circles) were CD20-positive/LSP1-negative (F) ($\times 250$). In lymphocyte-rich classical Hodgkin's disease, the CD30-positive Hodgkin and Reed-Sternberg cells (G) revealed constantly strong cytoplasmic and membrane-associated LSP1-labeling (H) (APAAP technique, Gill's hematoxylin counterstaining, $\times 400$ and $\times 600$).

PU.1 expression

Tumor cells in T-cell-rich B-cell lymphoma and lymphocyte-rich classical Hodgkin's disease were PU.1-negative in all instances (Figures 2A and 2B). In contrast, heterogeneous PU.1 expression was found in 10/13 cases of lymphocyte-predominant Hodgkin's disease. In five cases more than 95% of the L&H cells expressed PU.1 (Figure 2C), while PU.1 was expressed in a proportion of these cells (ranging from 20% to 70%) (Figure 2D) in another 5 cases. The neoplastic cells in the remaining three cases were all PU.1-negative (Figure 2E). These findings were confirmed by double labeling for CD20 and PU.1 (Figure 2F) to avoid problems caused by PU.1-positive histiocytes in the cellular background. Interestingly, the staining for PU.1 was frequently weaker in L&H cells than in reactive lymphocytes and histiocytes (Figure 2D).

Growth patterns of nodular lymphocyte-predominant Hodgkin's lymphoma

According to Fan *et al.*,²⁹ seven cases were classified as *classical nodular*, two *serpiginous/interconnected*, one *with inter-nodular L&H cells*, one *with T-cell-rich nodules*, and two *diffuse*. The first two variants were characterized by nodules with abundant small B lymphocytes, CD57-positive T-cell rosettes around CD20-positive neoplastic elements, and a prominent follicular dendritic cell meshwork. In the remaining variants, the content of B lymphocytes, CD57-positive elements and follicular dendritic cells progressively decreased, while the amount of reactive T lymphocytes progressively increased.

Clinical and follow-up data

Comprehensive clinical and follow-up data were obtained for 30 out of the 34 cases (Table 1) and confirmed significant differences between patients with T-cell-rich B-cell lymphoma, lymphocyte-predominant Hodgkin's disease and lymphocyte-rich classical Hodgkin's disease. Half of the T-cell-rich B-cell lymphoma patients had stage III or IV disease, presented with systemic symptoms and bulky tumor, and died of their disease despite aggressive therapy (namely, MACOP-B or a MACOP-B-like regimen as the first line therapy, and a supra-maximal approach followed by peripheral blood stem cell infusion as salvage therapy). In contrast, the lymphocyte-predominant Hodgkin's disease patients were all staged I-II, rarely presented with bulky disease or B symptoms, and were all in complete remission after a prolonged follow-up period (median 48 months). For these patients, the first line therapy consisted of three cycles of ABVD followed by involved field irradiation (30 cGy). In the only case with relapsing disease, an autologous bone-marrow transplantation was performed. Similar find-

ings were recorded in the patients with lymphocyte-rich classical Hodgkin's disease group who did, however, undergo four ABVD cycles with or without local radiotherapy.

Discussion

The differential diagnosis between T-cell-rich B-cell lymphoma and lymphocyte-predominant Hodgkin's disease has important therapeutic implications, and several studies have therefore been carried out in an attempt to find informative immunohistochemical markers.^{1,3,4,9-12,21,22,24,32} For example, Rüdiger *et al.* reported that the two diseases can be distinguished on the basis of a combination of phenotypic features, including the pattern of follicular dendritic cells and the TIA-1/CD57 T-cell ratio.^{9,13} However, none of the studies reported to date have fully achieved their goal of finding reliable immunohistological markers.²² Even the evaluation of reactive elements does not represent an entirely reliable tool, as their proportion can vary among cases of lymphocyte-predominant Hodgkin's disease depending on the tumor growth pattern, as shown by Fan *et al.*²⁹ and confirmed by this study.

In 2001, Torlakovic *et al.* reported that the PU.1 transcription factor is constantly present in L&H cells in lymphocyte-predominant Hodgkin's disease, but not in Reed Sternberg cells in classical Hodgkin's disease.²⁴ This finding was subsequently confirmed by Jundt *et al.*³⁵ In addition, Torlakovic and co-workers reported that PU.1 was absent in a few examples of T-cell-rich B-cell lymphoma.²⁴ Similar results were published by Boudová *et al.*, who found significantly weaker expression of PU.1 in T-cell-rich B-cell lymphoma than in lymphocyte-predominant Hodgkin's disease.²³ In contrast, Loddenkemper *et al.* recently reported stronger PU.1 positivity in T-cell-rich B cell lymphoma than in nodular lymphocyte-predominant Hodgkin's disease.³⁶

Based on these findings, we decided to investigate PU.1 expression in typical examples of T cell-rich B-cell lymphoma, lymphocyte-predominant Hodgkin's disease and lymphocyte-rich classical Hodgkin's disease to assess whether this marker might contribute to the differentiation between these tumors. We also studied the leukocyte-associated phosphoprotein, LSP1. This molecule has not previously been evaluated in T-cell-rich B cell lymphoma, but its expression has been reported to differ between cases of large B-cell lymphoma and lymphocyte-predominant Hodgkin's disease.²⁷

Several interesting findings were made. Most importantly, LSP1 and PU.1 differed in their expression between cases of T-cell-rich B-cell lymphoma and lymphocyte-predominant Hodgkin's disease (Table 3). These results suggest that these molecules may be more valu-

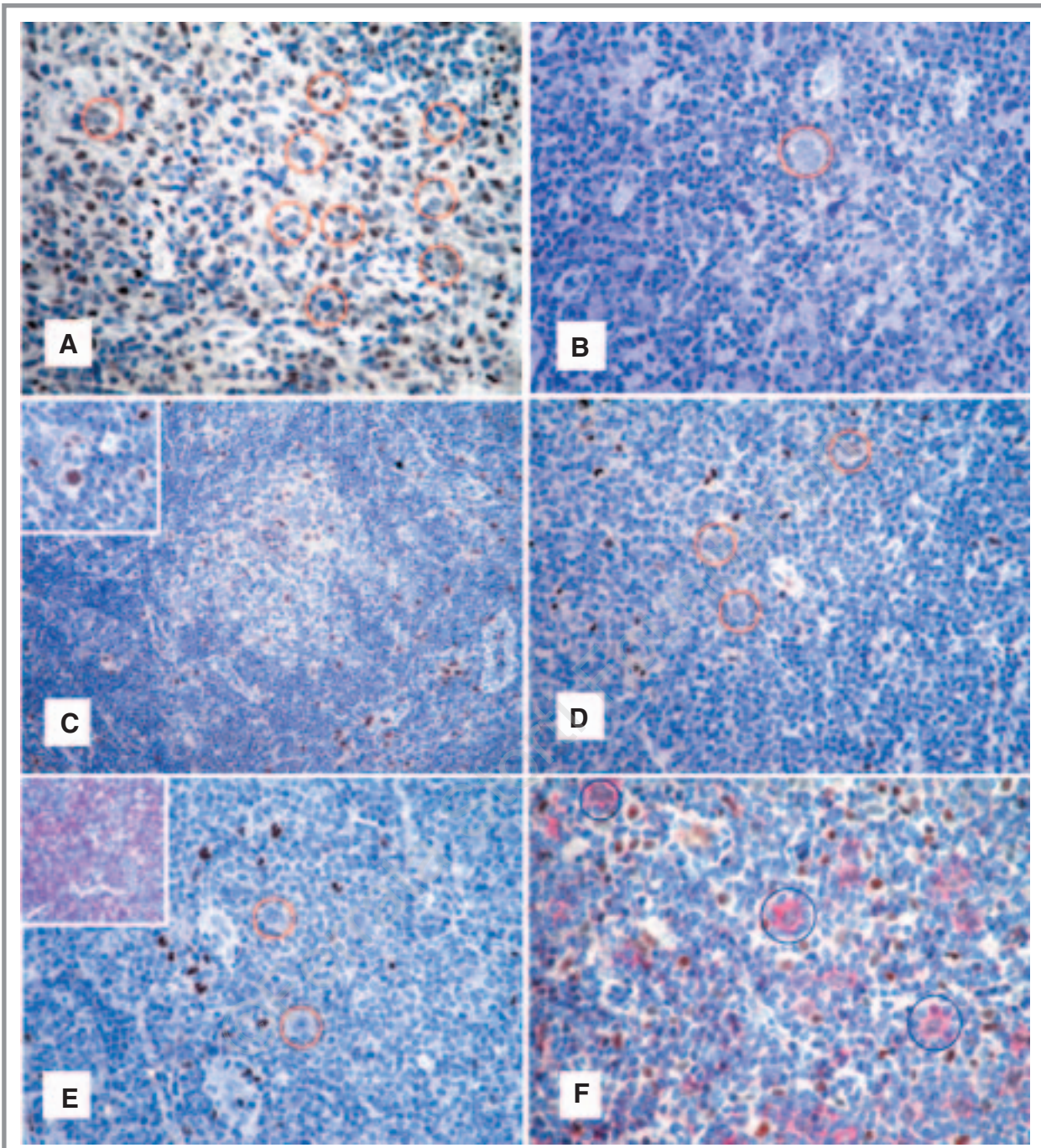


Figure 2. PU.1 expression in T-cell-rich B-cell lymphoma, lymphocyte-predominant Hodgkin's disease and lymphocyte-rich classical Hodgkin's disease. The neoplastic cells (red circles) in T-cell-rich B-cell lymphoma (A) and lymphocyte-rich classical Hodgkin's disease (B) cases were PU.1 negative (EnVision+ method, Gill's hematoxylin counterstaining, $\times 250$ and $\times 400$). PU.1 was heterogeneously expressed in lymphocyte-predominant Hodgkin's disease cases: (C) illustrates an example of a PU.1 positive case (EnVision+ method, Gill's hematoxylin counterstaining, $\times 100$). The inset highlights a single L&H cell showing nuclear PU.1-positivity (EnVision+ method, Gill's hematoxylin counterstaining, $\times 250$). In some cases of lymphocyte predominant Hodgkin's disease, only some L&H cells (red circles) carried PU.1, which in addition was weakly expressed (D) (EnVision+ method, Gill's hematoxylin counterstaining, $\times 250$). An example of PU.1 negative L&H cells (red circles) in lymphocyte-predominant Hodgkin's disease is shown (E) (EnVision+ method, Gill's haematoxylin counterstaining, $\times 250$). The inset highlights the presence of CD3-positive reactive T lymphocytes around L&H cells (APAAP technique, Gill's hematoxylin counterstaining, $\times 100$). Double immunoenzymatic staining for CD20 (red) and PU.1 (brown) revealed that L&H cells (blue circles) co-expressed both molecules (F) (APAAP technique and EnVision+ method, Gill's hematoxylin counterstaining, $\times 350$).

able in the differential diagnosis between T-cell-rich B-cell lymphoma and lymphocyte-predominant Hodgkin's disease than previously recognized markers⁹ (e.g. CD30, CD15, BCL-6, BSAP/PAX-5, BOB.1, OCT-2, and IRF4/MUM1) (see also Table 2).

Our study showed additional results of interest. The intensity of expression of PU.1 in L&H cells was variable, a fact that questions the speculative and diagnostic relevance of this marker in the field of Hodgkin's disease. In addition, PU.1 positivity in these cells was often weaker than in normal B-lymphocytes, peripheral B-cell lymphomas, and reactive macrophages.²⁴ Within this context, it should be noted that PU.1-positive histiocytes can be quite numerous in lymphocyte-predominant Hodgkin's disease, and they may be confused morphologically with L&H cells, resulting in an over-estimation of the positivity of the latter. The use of double immunostaining for CD20 and PU.1 (see Figure 2F) circumvented this problem, since it clearly revealed the number of PU.1-positive L&H cells and the expression variability of the transcription factor within the neoplastic compartment. The results represent another example of the value of using this overlooked approach to study antigen co-expression in routine biopsy samples.³⁴

It may be noted that the LSP1 phosphoprotein is involved in the regulation of cell motility, as shown by studies in mice and cell lines³⁷⁻⁴¹ It is conceivable that

the different clinical behaviors of lymphocyte-predominant Hodgkin's disease and T-cell-rich B-cell lymphoma, as confirmed in the present series, relate to the fact that the neoplastic cells in the former disease (frequently LSP1-negative) usually present in stage I or II, while the latter (regularly LSP1-positive) commonly manifests in a high stage and with spread to distant organs.

In conclusion, the present report highlights the value of using two markers, LSP1 and PU.1, for discriminating between T-cell-rich B-cell lymphoma and lymphocyte-predominant Hodgkin's disease. This points to the need for multi-center studies to evaluate these markers in previously reported series of *gray-zone* lymphomas.^{9,13}

TM, SAP: designed the study; CM, SA and ES interpreted the histological and immunohistochemical preparations; KP: carried out the double immunoenzymatic and immunofluorescent analyses; MP: performed the immunohistochemical analyses; PLZ: collected and analyzed the clinical data; ESJ, H-KH; critically revised the manuscript; BF, DYM: approved the final version of the manuscript.

This work was supported by grants from AIRC (Associazione Italiana per la Ricerca sul Cancro, Milan, Italy), MIUR (Ministero dell'Istruzione, dell'Università e della Ricerca, Rome, Italy), the Leukemia Research Fund (United Kingdom), and Fondazione del Monte di Bologna e Ravenna (Italy).

The author thank Dr. Milena Piccioli, Mr. Luigi Chillì, Mrs. Federica Sandri and Mrs. Valentina Dalbuoni for their technical support, and Dr. Claudio Agostinelli, Mrs. Imma Barese and Mrs. Bridget Watson for assistance with the preparation of this manuscript.

Manuscript received May 7, 2004. Accepted June 5, 2004.

References

- Achten R, Verhoef G, Vanuytsel L, De Wolf-Peeters C. Histiocyte-rich, T-cell-rich B-cell lymphoma: a distinct diffuse large B-cell lymphoma subtype showing characteristic morphologic and immunophenotypic features. *Histopathology* 2002;40:31-45.
- Chittal SM, Brousset P, Voigt JJ, Delsol G. Large B-cell lymphoma rich in T-cells and simulating Hodgkin's disease. *Histopathology* 1991;19:211-20.
- Delabie J, Vandenberghe E, Kennes C, Verhoef G, Foschini MP, Stul M, et al. Histiocyte-rich B-cell lymphoma. A distinct clinicopathologic entity possibly related to lymphocyte predominant Hodgkin's disease, paragranuloma subtype. *Am J Surg Pathol* 1992;16:37-48.
- Fraga M, Sanchez-Verde L, Forteza J, Garcia-Rivero A, Piris MA. T-cell/histiocyte-rich large B-cell lymphoma is a disseminated aggressive neoplasm: differential diagnosis from Hodgkin's lymphoma. *Histopathology* 2002;41:216-29.
- Gatter K, Warnke RA. Diffuse large B-cell lymphoma. In: Jaffe ES, Harris NL, Stein H, Vardiman JW, eds. *Pathology and genetics of tumours of the haematopoietic and lymphoid system*. Lyon: IARC Press, 2001. p. 171-4.
- Harris NL, Jaffe ES, Stein H, Banks PM, Chan JK, Cleary ML, et al. A revised European-American classification of lymphoid neoplasms: a proposal from the International Lymphoma Study Group. *Blood* 1994;84:1361-92.
- Macon WR, Williams ME, Greer JP, Stein RS, Collins RD, Cousar JB. T-cell-rich B-cell lymphomas. A clinicopathologic study of 19 cases. *Am J Surg Pathol* 1992;16:351-63.
- Ramsay AD, Smith WJ, Isaacson PG. T-cell-rich B-cell lymphoma. *Am J Surg Pathol* 1988;12:433-43.
- Rüdiger T, Jaffe ES, Delsol G, de Wolf-Peeters C, Gascoyne RD, Georgii A, et al. Workshop report on Hodgkin's disease and related diseases ('grey zone' lymphoma). *Ann Oncol* 1998;9 Suppl 5:S31-8.
- Anagnostopoulos I, Hansmann ML, Franssila K, Harris M, Harris NL, Jaffe ES, et al. European Task Force on Lymphoma project on lymphocyte predominance Hodgkin disease: histologic and immunohistologic analysis of submitted cases reveals 2 types of Hodgkin disease with a nodular growth pattern and abundant lymphocytes. *Blood* 2000;96:1889-99.
- Ashton-Key M, Isaacson PG. CD45 immunostaining in T-cell-rich B-cell lymphoma and lymphocyte predominance Hodgkin's disease. *J Pathol* 1997;181:462-3.
- De Jong D, Van Gorp J, Sie-Go D, Van Heerde P. T-cell rich B-cell non-Hodgkin's lymphoma: a progressed form of follicle centre cell lymphoma and lymphocyte predominance Hodgkin's disease. *Histopathology* 1996;28:15-24.
- Rüdiger T, Gascoyne RD, Jaffe ES, de Jong D, Delabie J, De Wolf-Peeters C, et al. Workshop on the relationship between nodular lymphocyte predominant Hodgkin's lymphoma and T cell/histiocyte-rich B cell lymphoma. *Ann Oncol* 2002;13 Suppl 1:44-51.
- Bräuninger A, Küppers R, Spiekert T, Spiekert T, Siebert R, Strikler JG, et al. Molecular analysis of single B cells from T-cell-rich B-cell lymphoma shows the derivation of the tumour cells from mutating germinal center B cells and exemplifies means by which immunoglobulin genes are modified in germinal center B cells. *Blood* 1999;93:2679-87.
- Marafioti T, Hummel M, Anagnostopoulos I, Foss HD, Falini B, Delsol G, et al. Origin of nodular lymphocyte-predominant Hodgkin's disease from a clonal expansion of highly mutated germinal-center B cells. *N Engl J Med* 1997;337:453-58.
- Ohno T, Stribley JA, Wu G, Hinrichs SH, Weisenburger DD, Chan WC. Clonality in nodular lymphocyte-predominant Hodgkin's disease. *N Engl J Med* 1997;337:459-65.
- Achten R, Verhoef G, Vanuytsel L, De Wolf-Peeters C. T-cell/histiocyte-rich large B-cell lymphoma: a distinct clinicopathologic entity. *J Clin Oncol* 2002;20:1269-77.
- Maes B, Anastasopoulou A, Kluijn-Nelemans JC, Teodorovic I, Achten R, Carbon A, et al. EORTC Lymphoma Group. Among diffuse large B-cell lymphomas, T-cell-rich/histiocyte-rich BCL and CD30+ anaplastic B-cell subtypes exhibit distinct clinical features. *Ann Oncol* 2001;12:

- 853-8.
19. Ripp JA, Looue DC, Chan W, Nawaz H, Portlock CS. T-cell rich B-cell lymphoma: clinical distinctiveness and response to treatment in 45 patients. *Leuk Lymphoma* 2002;43:1573-80.
 20. Franke S, Wlodarska I, Maes B, Vandenberghe P, Achten R, Hagemeijer A, et al. Comparative genomic hybridization pattern distinguishes T-cell/histiocyte-rich B-cell lymphoma from nodular lymphocyte predominance Hodgkin's lymphoma. *Am J Pathol* 2002;161:1861-7.
 21. Peh SC, Kim LH, Poppema S. TARC, a CC chemokine, is frequently expressed in classic Hodgkin's lymphoma but not in NLP Hodgkin's lymphoma, T-cell-rich B-cell lymphoma, and most cases of anaplastic large cell lymphoma. *Am J Surg Pathol* 2001;25:925-9.
 22. Lim MS, Beaty M, Sorbara L, Cheng RZ, Pittaluga S, Raffeld M, et al. T-cell/histiocyte-rich large B-cell lymphoma: a heterogeneous entity with derivation from germinal center B cells. *Am J Surg Pathol* 2002;26:1458-66.
 23. Boudová L, Torlakovic E, Delabie J, Reimer P, Pfistner B, Wiedenman S, et al. Nodular lymphocyte predominant Hodgkin lymphoma with nodules resembling T-cell/histiocyte rich B-cell lymphoma. *Blood* 2003;102:3753-8.
 24. Torlakovic E, Tierens A, Dang HD, Delabie J. The transcription factor PU.1, necessary for B-cell development is expressed in lymphocyte predominance, but not classical Hodgkin's disease. *Am J Pathol* 2001;159:1807-14.
 25. Henderson A, Calame K. Transcriptional regulation during B cell development. *Annu Rev Immunol* 1998;16:163-200.
 26. Lloberas J, Soler C, Celada A. The key role of PU.1/SPI-1 in B cells, myeloid cells and macrophages. *Immunol Today* 1999;20:184-9.
 27. Marafioti T, Jabri L, Pulford K, Brousset P, Mason DY, Delsol G. Leucocyte-specific protein (LSP1) in malignant lymphoma and Hodgkin's disease. *Br J Haematol* 2003;120:671-8.
 28. Stein H, Delsol G, Pileri S, Said J, Mann R, Poppema S, et al. Classical Hodgkin Lymphoma. In: *Pathology and Genetics of Tumours of the Haematopoietic and Lymphoid System*, Jaffe ES, Harris NL, Stein H, Vardiman JW eds. IARC Press: Lyon, 2001. p. 244-53.
 29. Fan Z, Naktuman Y, Bair E, Tibshirami R, Warnke RA. Characterization of variants patterns of nodular lymphocyte predominant Hodgkin lymphoma with immunohistologic and clinical correlation. *Am J Surg Pathol* 2003;27:1346-56.
 30. Falini B, Pileri S, Martelli MF. Histological and immunohistological analysis of human lymphomas. *Crit Rev Oncol Hematol* 1989;9:351-419.
 31. Pileri SA, Roncador G, Ceccarelli C, Piccioli M, Sabattini E, Briskomatis, et al. Antigen retrieval techniques in immunohistochemistry: comparison of different methods. *J Pathol* 1997;183:116-23.
 32. Cordell JL, Falini B, Erber WN, Ghosh AK, Abdouzziz Z, MacDonald S, et al. Immunoenzymatic labeling of monoclonal antibodies using immune complexes of alkaline phosphatase and monoclonal anti-alkaline phosphatase (APAAP complexes). *J Histochem Cytochem* 1984; 32: 219-29.
 33. Sabattini E, Bisgaard K, Ascani S, Poggi S, Piccioli M, Ceccarelli C, et al. The EnVision++ system: a new immunohistochemical method for diagnostics and research. Critical comparison with the APAAP, ChemMate, CSA, LABC, and SABC techniques. *J Clin Pathol* 1998;51:506-11.
 34. Mason DY, Micklem K, Jones M. Double immunofluorescence labelling of routinely processed paraffin sections. *J Pathol* 2000;191:452-61.
 35. Jundt F, Kley K, Anagnostopoulos I, Schulze Probsting K, Greiner A, Mathas S, et al. Loss of PU.1 expression is associated with defective immunoglobulin transcription in Hodgkin and Reed-Sternberg cells of classical Hodgkin disease. *Blood* 2002;99:3060-2.
 36. Loddenkemper C, Anagnostopoulos I, Hummel M, Jöhrens-Leder K, Foss H-D, Jundt F, et al. Differential Emu enhancer activity and expression of BOB.1/OBF.1, Oct.2, PU.1 and immunoglobulin in reactive B-cell populations, B-cell non-Hodgkin's lymphomas, and Hodgkin's lymphomas. *J Pathol* 2004;202:60-9.
 37. Jongstra-Bilen J, Misener VL, Wang C, Ginrborg H, Auerbach A, Joyner AL, et al. LSP1 modulates leukocyte populations in resting and inflamed peritoneum. *Blood* 2000;96:1827-35.
 38. Li Y, Zhang Q, Aaron R, Hilliard L, Howard TH. LSP1 modulates the locomotion of monocyte-differentiated U937 cells. *Blood* 2000;96:1100-5.
 39. Miyoshi EK, Stewart PL, Kincade PW, Lee MB, Thompson AA, Wall R. Aberrant expression and localization of the cytoskeleton-binding pp52 (LSP1) protein in hairy cell leukemia. *Leuk Res* 2001;25: 57-67.
 40. Wang C, Hayashi H, Harrison R, Chan JR, Ostergaard HL. Modulation of Mac-1 (CD11 β /CD18)-mediated adhesion by the leukocyte-specific protein 1 is key to its role in neutrophil polarization and chemotaxis. *J Immunol* 2002;169:415-23.
 41. Zhang Q, Li Y, Howard TH. Hair-forming activity of human lymphocyte specific protein 1 requires cooperation between its caldesmon-like domains and the villin headpiece-like domains. *Cell Motil Cytoskeleton* 2001;49:179-88.