

## Bull's neck in Hodgkin's disease: a CT imaging appraisal

Haematologica 2004; 89:(6):e83

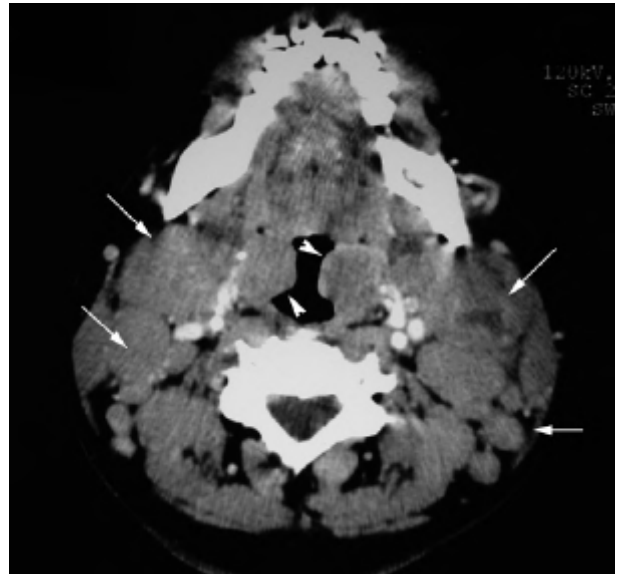
### Case report

A 41-year-old man presented with fever and progressive bilateral neck swelling for three weeks. Physical examination showed bull's neck appearance due to cervical and submandibular lymphadenopathy. Ear, nose and throat examination showed bilateral enlarged tonsils. Computed tomography (CT) scan showed multiple cervical and submandibular lymphadenopathies (Figure). Complete staging with CT scan of the thorax and abdomen, and bilateral trephine biopsies did not reveal disease elsewhere, and thus confirmed stage IIB Hodgkin's lymphoma. Serum lactate dehydrogenase level measured 813 u/L (normal: < 400u/L). Tonsil and cervical lymph node biopsy showed findings consistent with Hodgkin's lymphoma, mixed cellularity type. He achieved complete remission with ABVD combination chemotherapy (Ariamycin, bleomycin, vinblastine and dacarbazine).

Chim CS, Leung AYH, Ooi GC\*

\*University Departments of Medicine and Radiology, Queen Mary Hospital, University of Hong Kong, Hong Kong.

Correspondence: Dr CS Chim,  
Department of Medicine, Queen Mary Hospital,  
Pokfulam Road, Hong Kong.  
Fax: (852)29741165 Tel: (852)28555389  
E-mail: jcschim@hkeucc.hku.hk



**Figure.** CT scan of the neck showed bilateral cervical lymphadenopathy and bilateral enlarged salivary glands (arrowheads) with marked narrowing the oropharynx.