

## Acquired factor XIII deficiency due to an inhibitor: a case report and review of the literature

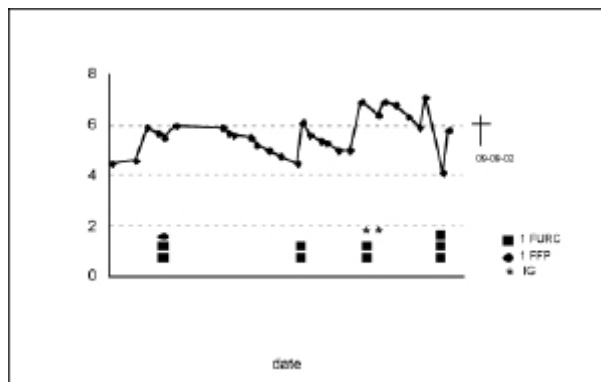
*Haematologica* 2004; 89(4):e46-e48

When a bleeding disorder is suspected, performing routine coagulation tests is not sufficient, as a normal Activated Partial Thromboplastin Time (APTT) and Protrombin Time (PT) do not exclude clinically relevant deficiencies of various coagulation factors and anti-fibrinolytic factors. In this report we describe a patient who presented with spontaneous bleeding and a normal APTT and PT. Analysis showed the presence of an acquired inhibitor to factor XIII. The pathogenesis, clinical features and treatment modalities will be discussed.

A 75 year old woman was referred to our hospital because of multiple subcutaneous haematomas and a painful swollen upper left thigh a few days after a fall. Her medical history revealed recurrent depressions, for which she had been admitted to a psychiatric clinic and for which a selective serotonin uptake inhibitor (fluvoxamine) was prescribed. A cholecystectomy was performed 30 years earlier without bleeding complications. Physical examination showed a healthy but pale looking woman. Examination of heart, lungs and abdomen was unremarkable. There were indeed multiple haematomas on her entire body. A swollen and tense left thigh was found (diameter 61 cm compared to 56 cm on the right). Laboratory studies showed a normocytic anemia (haemoglobin 4.6 mmol/L). Platelet count, APTT and PT were normal. An ultrasound of the left upper thigh showed an intramuscular haematoma.

As multiple units of red blood cells were necessary to maintain a stable hemoglobin level (Figure 1) a coagulation disorder was suspected. However, additional tests were found to be within normal limits: bleeding time, von Willebrand factor activity (ristocetin cofactor activity >100%) and antigen (>125%), platelet aggregation tests (using ADP, collagen, arachidonic acid and ristocetin as stimulators) and fibrinogen (6 g/L). A clotting disorder was reconsidered when an intramuscular bleeding in the left arm occurred, probably caused by vein punctures. The consulted haematologist ordered factor XIII and alpha-2-antiplasmin tests (108%). Photometric determination of factor XIII activity revealed a severe deficiency (Berichrom F XIII®, Dade Behring, Marburg, Germany: 6%, ref 70-140% of normal plasma). As the patient never experienced bleeding before, the factor XIII deficiency was most likely to be acquired, which could be confirmed by determination of an inhibitor in mixing studies (inhibitor titer of >20 U/mL). The factor XIII activity in a 1:1 mixture of patient and normal plasma remained extremely low (2%).

Underlying malignant, lympho-proliferative or auto-immune diseases were found to be unlikely as computer tomographic scanning of thorax and abdomen showed no abnormalities, protein analysis excluded the presence of a M-protein and no anti-nuclear factor or anti rheuma factor antibodies were present. Therapy was started with prednisone (1 mg/kg). In order to quickly raise factor XIII levels, human immunoglobulins (1 g/kg, for 2 days) were administered. This resulted in an increase of factor XIII from 2% to 16% six days later. Because it was possible to maintain adequate Hb-levels with transfusion of <3 units of red cells/week, it was decided not to administer fXIII-concentrate. The patient redeveloped a severe depression. At that time, at persistent low fXIII levels of about 10%, a painful haematoma developed in the right flank.



**Figure 1.** Haemoglobin level and timing of transfusion of filtered units of red cells and fresh frozen plasma.

The patient was admitted to the hospital at July the 11<sup>th</sup> with an intramuscular haematoma. On the 12<sup>th</sup> of Augusts she developed a haematoma in the left arm due to vein punctures. The diagnosis of acquired factor XIII deficiency was made at August the 22<sup>th</sup> after a haematologist was consulted. The patient was treated thereafter with immunoglobulins (IG: 1g/kg for 2 days). In the beginning of September a painful haematoma developed in the right flank. Further therapy was refused by the patient.

The patient refused any therapy because of her wish to die. A psychiatric consultant judged her to be competent and her chronic depression to be therapy resistant. A few days later she died due to rectal bleeding and accompanying hypovolemic shock. An autopsy, including section of the brain, was performed. Besides large haematomas in the left upper thigh and the right intercostal muscles autopsy revealed no abnormalities.

This case report emphasizes that in a patient with persistent bleeding a normal APTT and PT does not exclude a clinically relevant deficiency of a coagulation factor is not excluded. Although levels of nearly all coagulation factors can be subnormal despite normal APTT and PT, those levels are generally not accompanied with spontaneous serious bleeding. In case of bleeding, especially disturbances in platelet aggregation/adhesion or a deficiency of factor XIII or alpha-2-antiplasmin have to be considered. In our patient an acquired inhibitor to factor XIII was diagnosed. Factor XIII is a specific transamidase that cross links fibrin molecules by forming  $\alpha$ -( $\gamma$ -glutamyl)lysine bridges that stabilize the clot. Moreover, it incorporates fibronectin, collagen and alfa-2-antiplasmin into the clot, thereby making the clot more suitable for the ingrowth of fibroblasts and more resistant to fibrinolysis. That patients with factor XIII deficiency generally start bleeding some time after trauma is probably accounted for by the fact that fibrinolysis of clots occurs more rapidly because of less alfa-2-antiplasmin incorporated into the clot.<sup>1</sup> Furthermore, non cross-linked fibrin has a higher affinity for plasminogen.<sup>2</sup> Hereditary factor XIII deficiency is a rare severe bleeding disorder (incidence 1:3.000.000). The inheritance is autosomal recessive. In 80% the first and almost pathognomonic sign is bleeding from the umbilical cord a few days after birth. There is a tendency to bleed in the skin, muscles and subcutaneous tissues. Patients bleed several days after minor trauma or surgery. In up to 30% of cases intracranial bleeding occurs.<sup>1</sup> In addition to hereditary factor XIII deficiency, acquired factor XIII deficiency has been described.<sup>3</sup> Acquired partial deficiencies, usually in the range of 50-75% of normal have been reported in association with various diseases (see Table 1). Whether these mild deficiencies are of clinical importance has been differently reported on 1,4. Severe deficiencies, leading to sponta-

**Table 1.** Causes of acquired factor XIII deficiency.

Impaired synthesis
Liver disease
Increased turn-over and consumption
Acute and chronic leukemia
Myeloproliferative and myelodysplastic syndrome
Disseminated intravascular coagulation
Septic infections
Unknown or combined etiology
Major surgery
Inflammatory gastrointestinal diseases (Henoch Schönlein, ulcerative colitis, hemorrhagic gastritis)
Acquired inhibitors
Idiopathic
Drug-induced (isoniazid, penicillin, diphantoin)
Systemic Lupus Erythematosis
Lymphoproliferative diseases

neous bleeding are most often caused by acquired inhibitors to factor XIII. The first patient was described in 1967.<sup>5</sup> We could identify 21 cases of inhibitor induced acquired factor XIII deficiency in the literature.<sup>6-25</sup> Six of these patients used isoniazide, which is presumed to play a causative role. Autoimmune diseases were present in 5 patients. In only two cases a Monoclonal Gammopathy of Undetermined Significance (MGUS) was found, one patient also using isoniazide. In most<sup>8</sup> of described cases no underlying disease could be determined, although it has to be emphasised that no generally no extensive investigations were performed. Concerning our patient; no association between fluvoxamine and acquired FXIII deficiency has been reported. To our knowledge, this would be the first report. However, as it is not unusual that an underlying disease is absent, it might well be coincidence. Factor XIII deficiency can be diagnosed with functional assays showing increased clot solubility in 1% monochloroacetic acid or in 5M urea can be used.<sup>5</sup> However, these tests do not differentiate heterozygotes or patients with acquired partial deficiency. Quantization of factor XIII activity levels can be easily determined by a photometric assay such as we used. The presence of an inhibitor against fXIII can be investigated in mixing studies with normal plasma, in which the remaining FXIII level is lowered by the presence of the inhibitor, leading to persistent low fXIII levels. Furthermore, the inhibitor can be quantified by use of the Bethesda assay, in which control and patient plasma in different dilutions are incubated with normal human plasma for 2 hours at 37°C. Subsequently, the remaining level of factor XIII is determined. The Bethesda inhibitor titer is defined as the reciprocal of the plasma dilution that yields a residual factor XIII of 50%.

The treatment of patients with an acquired factor XIII inhibitor aims at controlling bleeding by an acute increase in factor XIII and by elimination of the inhibitor. Acute increases in factor XIII can be obtained by administration of factor XIII, either as fresh frozen plasma or as pasteurised factor XIII concentrate derived from human placenta (Fibrogammin-P®). Because of a long *in vivo* half life (11-14 days), in hereditary factor XIII deficiency 1000 U of Fibrogammin-P® can be given very 6 weeks. This dose normally raises the plasma level to above 30% of normal, providing levels of 3-5% at week 6, which, in hereditary deficiency, is sufficient to prevent bleeding. However, in inhibitor patients, the half life is considerably shorter. Therefore, higher and more frequent dosages are necessary. Control of hemorrhagic symptoms has been obtained with factor XIII doses from 50-150 U/kg.<sup>17,22</sup>

Administration of factor XIII can be combined with plasmapheresis to remove antibodies. However, as most of the antibodies are IgG antibodies rapid repletion from extravascular sites occurs. An increase in antibody depletion can be achieved with the use of staphylococcus A columns, which selectively binds to the Fc portion of the human IgG.<sup>19</sup> Although the value of gammaglobulins in patients with a factor XIII inhibitor is unknown, in view of the described effect in patients with acquired hemophilia A and von Willebrand disease, we treated our patient with intravenous gammaglobulins.<sup>26,27</sup> The proposed mechanisms of action are direct complex formation of the gammaglobulins with the neutralizing antibody (idiotype anti-idiotypic interaction) and blockade of the Fc receptors of the reticuloendothelial system thereby reducing the plasma clearance of antigen-antibody complexes. Effect is generally observed after several days, which indeed appeared to be the case in our patient, showing a rise in fXIII activity of 14%. Furthermore, although no clinical data are available it would be reasonable to treat patients with anti-fibrinolytic therapy (e.g. tranexaminic acid), as clots are more vulnerable to fibrinolysis.<sup>1,2</sup>

Similar to treatment of acquired inhibitors to factor VIII, inhibition of the formation of antibodies can be tried by administration of high doses of corticosteroids, cyclofosfamide, ciclosporin or combinations.<sup>3,28</sup> The success rate is unknown because of the rarity of this disease and the fact that spontaneous remissions have been reported. In the 21 described cases the fatality rate was high: 50% of patients of whom the outcome was reported died. However, the current possibility to treat patients with high dose factor XIII concentrate might lead to a lower mortality, which is supported by recent reports.<sup>15,17,18,22</sup>

In conclusion, although substitution therapy is easy in hereditary factor XIII deficiency because of the long half life of factor XIII concentrate, treatment of patients with inhibitors is more complicated. High and frequent dosing of factor XIII concentrates (Fibrogammin-P®) is necessary. As the pharmacokinetics of transfused factor XIII concentrate is unpredictable, monitoring of factor XIII levels is a prerequisite. There might be a role for human immunoglobulines to decrease the clearance of factor XIII-antibody complexes, thereby minimizing the necessary dosages of factor XIII administration.

A.V.M. Nijenhuis,<sup>1</sup> L. van Bergeijk,<sup>1</sup> P.C. Huijgens,<sup>2</sup> S. Zweegman<sup>2</sup>

<sup>1</sup>Department of Internal Medicine, Hospital Twenteborg, Almelo and

<sup>2</sup>Department of Haematology, VU University Medical Center, Amsterdam, the Netherlands

## References

1. Board PG, Losowsky MS, Miloszewski KJ. Factor XIII: inherited and acquired deficiency. *Blood Rev.* 1993;7:229-242.
2. Sakata Y, Mimuro J, Aoki N. Differential binding of plasminogen to crosslinked and noncrosslinked fibrins: its significance in hemostatic defect in factor XIII deficiency. *Blood.* 1984;63:1393-1401.
3. Tosetto A, Castaman G, Rodeghiero F. Acquired plasma factor XIII deficiencies. *Haematologica.* 1993;78:5-10.
4. Gerlach R, Tolle F, Raabe A et al. Increased risk for postoperative hemorrhage after intracranial surgery in patients with decreased factor XIII activity: implications of a prospective study. *Stroke.* 2002;33:1618-1623.
5. Lewis JH, Szeto IL, Ellis LD, Bayer WL. An acquired inhibitor to coagulation factor 13. *Johns Hopkins Med J.* 1967;120:401-407.
6. Lorand L, Jacobsen A, Bruner-Lorand J. A pathological inhibitor of fibrin cross-linking. *J Clin Invest.* 1968;47:268-273.
7. Godal HC. An inhibitor to fibrin stabilizing factor (FSF, factor XIII). *Scand J Haematol.* 1970;7:43-48.
8. Lorand L, Maldonado N, Fradera J et al. Haemorrhagic syn-

- drome of autoimmune origin with a specific inhibitor against fibrin stabilizing factor (factor XIII). *Br J Haematol.* 1972;23:17-27.
9. McDevitt NB, McDonagh J, Taylor HL, Roberts HR. An acquired inhibitor to factor XIII. *Arch Intern Med.* 1972;130:772-777.
  10. Otis PT, Feinstein DI, Rapaport SI, Patch MJ. An acquired inhibitor of fibrin stabilization associated with isoniazid therapy: clinical and biochemical observations. *Blood.* 1974;44:771-781.
  11. Rosenberg RD, Colman RW, Lorand L. A new haemorrhagic disorder with defective fibrin stabilization and cryofibrinogenaemia. *Br J Haematol.* 1974;26:269-284.
  12. Milner GR, Holt PJ, Bottomley J, Maciver JE. Practolol therapy associated with a systemic lupus erythematosus-like syndrome and an inhibitor to factor XIII. *J Clin Pathol.* 1977;30:770-773.
  13. Shires L, Gomperts ED, Bradlow BA. An acquired inhibitor to factor XIII A case report. *S Afr Med J.* 1979;56:70-72.
  14. Fear JD, Miloszewski KJ, Losowsky MS. An acquired inhibitor of factor XIII with a qualitative abnormality of fibrin cross-linking. *Acta Haematol.* 1984;71:304-309.
  15. Nakamura S, Kato A, Sakata Y, Aoki N. Bleeding tendency caused by IgG inhibitor to factor XIII, treated successfully by cyclophosphamide. *Br J Haematol.* 1988;68:313-319.
  16. Lorand L, Velasco PT, Rinne JR et al. Autoimmune antibody (IgG Kansas) against the fibrin stabilizing factor factor XIII. system. *Proc Natl Acad Sci U S A.* 1988;85:232-236.
  17. Daly HM, Carson PJ, Smith JK. Intracerebral haemorrhage due to acquired factor XIII inhibitor--successful response to factor XIII concentrate. *Blood Coagul Fibrinolysis.* 1991;2:507-514.
  18. Krumdieck R, Shaw DR, Huang ST, Poon MC, Rustagi PK. Hemorrhagic disorder due to an isoniazid-associated acquired factor XIII inhibitor in a patient with Waldenstrom's macroglobulinemia. *Am J Med.* 1991;90:639-645.
  19. Gailani D. An IgG inhibitor against coagulation factor XIII: resolution of bleeding after plasma immunoadsorption with staphylococcal protein A. *Am J Med.* 1992;92:110-112.
  20. Fukue H, Anderson K, McPhedran P, Clyne L, McDonagh J. A unique factor XIII inhibitor to a fibrin-binding site on factor XIIIa. *Blood.* 1992;79:65-74.
  21. Donnet A, Trefouret S, Alessi MC et al. [Intradural hematoma of the foramen magnum associated with factor XIII deficiency]. *Rev Neurol (Paris).* 1994;150:164-166.
  22. Tosetto A, Rodeghiero F, Gatto E, Manotti C, Poli T. An acquired hemorrhagic disorder of fibrin crosslinking due to IgG antibodies to FXIII, successfully treated with FXIII replacement and cyclophosphamide. *Am J Hematol.* 1995;48:34-39.
  23. Ahmad F, Solymoss S, Poon MC, Berube C, Sullivan AK. Characterization of an acquired IgG inhibitor of coagulation factor XIII in a patient with systemic lupus erythematosus. *Br J Haematol.* 1996;93:700-703.
  24. Lorand L, Velasco PT, Murthy SN, Lefebvre P, Green D. Autoimmune antibody in a hemorrhagic patient interacts with thrombin-activated factor XIII in a unique manner. *Blood.* 1999;93:909-917.
  25. Lorand L, Velasco PT, Hill JM, Hoffmeister KJ, Kaye FJ. Intracranial hemorrhage in systemic lupus erythematosus associated with an autoantibody against factor XIII. *Thromb Haemost.* 2002;88:919-923.
  26. Crenier L, Ducobu J, des Grottes JM et al. Low response to high-dose intravenous immunoglobulin in the treatment of acquired factor VIII inhibitor. *Br J Haematol.* 1996;95:750-753.
  27. Schwartz RS, Gabriel DA, Aledort LM, Green D, Kessler CM. A prospective study of treatment of acquired (autoimmune) factor VIII inhibitors with high-dose intravenous gammaglobulin. *Blood.* 1995;86:797-804.
  28. Delgado J, Jimenez-Yuste V, Hernandez-Navarro F, Villar A. Acquired haemophilia: review and meta-analysis focused on therapy and prognostic factors. *Br J Haematol.* 2003;121:21-35.