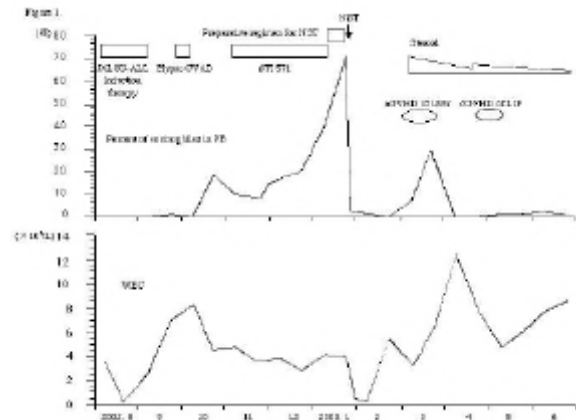


## Successful treatment of hypereosinophilic syndrome (HES) after remission of acute lymphoblastic leukemia in a patient who underwent non-myeloablative stem cell transplantation (NST)

Haematologica 2004; 89(2):e21-e22

### TO THE EDITOR

We report a case of HES which developed after complete remission of Philadelphia chromosome positive (Ph1) acute lymphoblastic leukemia (ALL). HES was successfully treated by allogeneic NST. A 47 year-old woman complained of general fatigue and hemorrhaging gums and was diagnosed with ALL on August 17 of 2002. More than ninety percent of CD19 and CD20 positive blast cells were present in peripheral blood (PB) and bone marrow (BM). Major bcr-abl chimeric DNA was detected by polymerase chain reaction (PCR) in the BM mononuclear cells (MNC) of this patient. The clinical course of this case is shown in Figure 1. The chemotherapeutic agents were administered according to a daunorubicin combined induction regimen. The blast cells in PB and BM were eradicated but cerebrospinal fluid invasion developed. Intrathecal cytarabine, methotrexate, and prednisolone were administered. After treatment for CNS leukemia, the patient was administered hyper-CVAD from September 27. As indicated by the negative result of Ph<sup>1</sup> for BM-MNC, cytogenetic complete remission (CR) was confirmed on October 22. The eosinophil count in PB had increased since October 26. Drug-induced HES was suspected so some drugs were discontinued, but HES persisted. Eosinophil invasion in BM and skin was indicated, and night sweat and atrial fibrillation developed with rapid elevation of the eosinophil count in PB. Imatinib is reported to be effective against Ph1 ALL as well as HES.<sup>2, 3</sup> Therefore, we administered Imatinib to this patient, but this did not control the eosinophilia. The patient underwent NST on January 28, 2003, because she had developed renal failure after hyper-CVAD. A preparative regimen of fludarabine at 30 mg/body/day for 6 days and 6 Gy of total body irradiation (TBI) in three fractions over 2 days was initiated. The eosinophil count declined after NST. Neutrophil engraftment was observed on February 9. One month after NST, eosinophil levels became elevated again because of acute graft-versus-host disease (GVHD) of the liver. After administration of prednisolone, the GVHD of the liver improved and the eosinophil count also decreased. Eosinophilia has not returned some 8 months after NST. Eosinophilia is sometimes associated with ALL or acute GVHD.<sup>4, 5</sup> However, cytogenetic CR was confirmed during the first occurrence of eosinophilia in this case. This eosinophilia might be associated with IL5 production via a B-cell dependent pathway. When IL5 is produced by a T-cell dependent pathway, soluble IL2 receptor levels are sometimes elevated.<sup>6</sup> The soluble IL2 receptor levels in this case were in a normal range during the first occurrence of eosinophilia. Thus, the T-cell pathway was not directly related to this eosinophilia, and some B-cell abnormalities were noted during cytogenetic CR. Imatinib is one of the effective treatments for HES.<sup>3</sup> Although STI-571 was administered, the first occurrence of eosinophilia in this case was not controlled. Serum IL3 and GM-CSF was undetectable but serum IL5 levels elevated to 56.6 pg/mL (a normal range is below 10 pg/mL) during the initial eosinophilia when imatinib was administered. High lev-



**Figure 1.** The clinical course of the case. Eosinophil count in PB was elevated after complete remission of ALL. Eosinophils in PB decreased soon after NST.

els of serum IL5 might be associated with the inefficacy of Imatinib to hypereosinophilia. Ph1 ALL is one of the most difficult to treat hematological malignancies and is reported to frequently relapse after conventional stem cell transplantation (CST). NST treatment for Ph1 ALL has not been confirmed to have as good an outcome as that for CST. The patient had renal dysfunction. Major bcr-abl chimeric DNA and immunoglobulin heavy chain clonal rearrangement were not detected in BM and PB MNC by PCR. Therefore, NST was undertaken on the patient. Controllable acute and chronic GVHD was observed in this case. The survival rates of some patients with HES were long following administration of immunosuppressive drugs.<sup>7</sup> Patients with uncontrollable HES have undergone stem cell transplantation. Recently, NST has been performed on HES patients.<sup>8, 9</sup> Patients with HES sometimes have complications such as cardiac failure, pulmonary invasion, or splenomegaly. Therefore, NST can be one good method for treating patients with HES who do not respond to immunosuppressive drugs because of its low toxicity as a preparative regimen.

Y Tsutsumi,<sup>1</sup> J Tanaka,<sup>2</sup> H Kanamori,<sup>1</sup> T Miura,<sup>1</sup> T Kawamura,<sup>1</sup>  
S Obara,<sup>1</sup> M Asaka,<sup>3</sup> M Imamura,<sup>2</sup> N Masauzi<sup>1</sup>

<sup>1</sup>The Department of Internal Medicine, Hakodate Municipal Hospital, Hakodate, Japan; <sup>2</sup>Hematology and Oncology, and

<sup>3</sup>Gastroenterology, Hokkaido University Graduate School of Medicine Sapporo, Japan

### References

- Koller CA, Kantarjian HM, Thomas D, O'Brien S, Rios MB, Komblau S, et al. The hyper-CVAD regimen improves outcome in relapsed acute lymphoblastic leukemia. *Leukemia* 1997; 11: 2039-2044.
- Ottmann OG, Druker BJ, Sawyers CL, Goldman JM, Reiffers J, Silver RT, et al. A phase 2 study of imatinib in patients with relapsed or refractory Philadelphia chromosome-positive acute lymphoid leukemias. *Blood* 2002; 100: 1965-1971.
- Pardanani A, Reeder T, Porrata LF, Li CY, Tazelaar HD, Baxter EJ, et al. Imatinib therapy for hypereosinophilic syndrome and other eosinophilic disorders. *Blood* 2003; 101: 3391-3397.
- Nunez CA, Zipf TF, Roberts WM, Medeiros LJ, Hayes K, Buseo-Ramos CE. Molecular monitoring of cerebrospinal fluid can predict clinical relapse in acute lymphoblastic leukemia with eosinophilia. *Arch Pathol Lab Med* 2003; 127: 601-605.

4. Mcneel D, Rubio MT, Damaj G, Emile JF, Belanger C, Varet B, et al. Hypereosinophilia as a presenting sign of acute graft-versus-host disease after allogeneic bone marrow transplantation. *Transplantation* 2002; 74: 1797-1800.
5. Roufosse F, Schandene L, Sibille C, Kennes B, Efira A, Cogan E, et al. T-cell receptor-independent activation of clonal Th2 cells associated with chronic hypereosinophilia. *Blood* 1999; 94: 994-1002.
6. Weller PF, Bubley GJ. The idiopathic hypereosinophilic syndrome. *Blood* 1994; 83: 2759-2779.
7. Ueno NT, Anagnostopoulos A, Rondon G, Champlin R, Mikhailova N, Pankratova OS, et al. Successful non-myeloablative allogeneic transplantation for treatment of idiopathic hypereosinophilic syndrome. *Br J Haematol* 2002; 119: 131-134.
9. Juvonen E, Volin L, Koponen A, Ruutu T. Allogeneic blood stem cell transplantation following non-myeloablative conditioning for hypereosinophilic syndrome. *Bone Marrow Transplant* 2002; 29: 457-458.