

Isolated sphenoid plasmacytoma presenting as painful ophthalmoplegia

Haematologica 2007; 88(8):e115-e116

A 45-year old woman presented with painful left ophthalmoplegia that had been present for one week. There was complete immobilization of the left globe with 3mm proptosis, but normal visual field and acuity. An urgent magnetic resonance scan showed a 4 cm lesion straddling the greater ala of the sphenoid from the cranial fossa to the orbit, abutting on the superior rectus (Figure 1A and B). Complete blood picture, biochemistry and chest X ray were normal and there were no other medical complaints or history of malignancy. An en-bloc resection was performed as a combined neurosurgical and oculoplastic procedure, with complete visual recovery. The histology showed sheets of plasma cells with κ light chain restriction, compatible with an osseous plasmacytoma (Figure 1C). A bone marrow biopsy showed only 3% plasma cells with a suggestion of light chain restriction, while skeletal survey, plasma immunoglobulin levels and electrophoresis were normal. A 24-hour urine examination however showed gross proteinuria

(1.5g / 24 hours) with 87% κ light chain M-protein. The patient was treated with VAD chemotherapy for four cycles. One year later, she suffered from multiple osseous relapses in the spine and sternum, but her serum globulin and marrow assessment remained grossly normal. There was no recurrence of disease in the original orbital area. Orbital space occupying lesions (SOL) presenting with painful ophthalmoplegia are mostly due to malignancies. The abnormal growth may originate from inside or outside the globe and may or may not be accompanied by systemic deposits. Urgent surgical resection and decompression is usually indicated for diagnosis and treatment. Although imaging allows the rapid localization of orbital lesions, the finding of a systemic disease may allow targeted medical, surgical or radiation treatment to minimize morbidity. In the setting of isolated osseous erosions, the screening for systemic plasma cell dyscrasia should include full urinalysis with electrophoresis, irrespective of serum findings. Interestingly, the greater ala of the sphenoid is a common site for plasmacytoma. Osseous plasmacytomas with monoclonal protein almost always herald systemic disease, either in the form of myeloma or disseminated

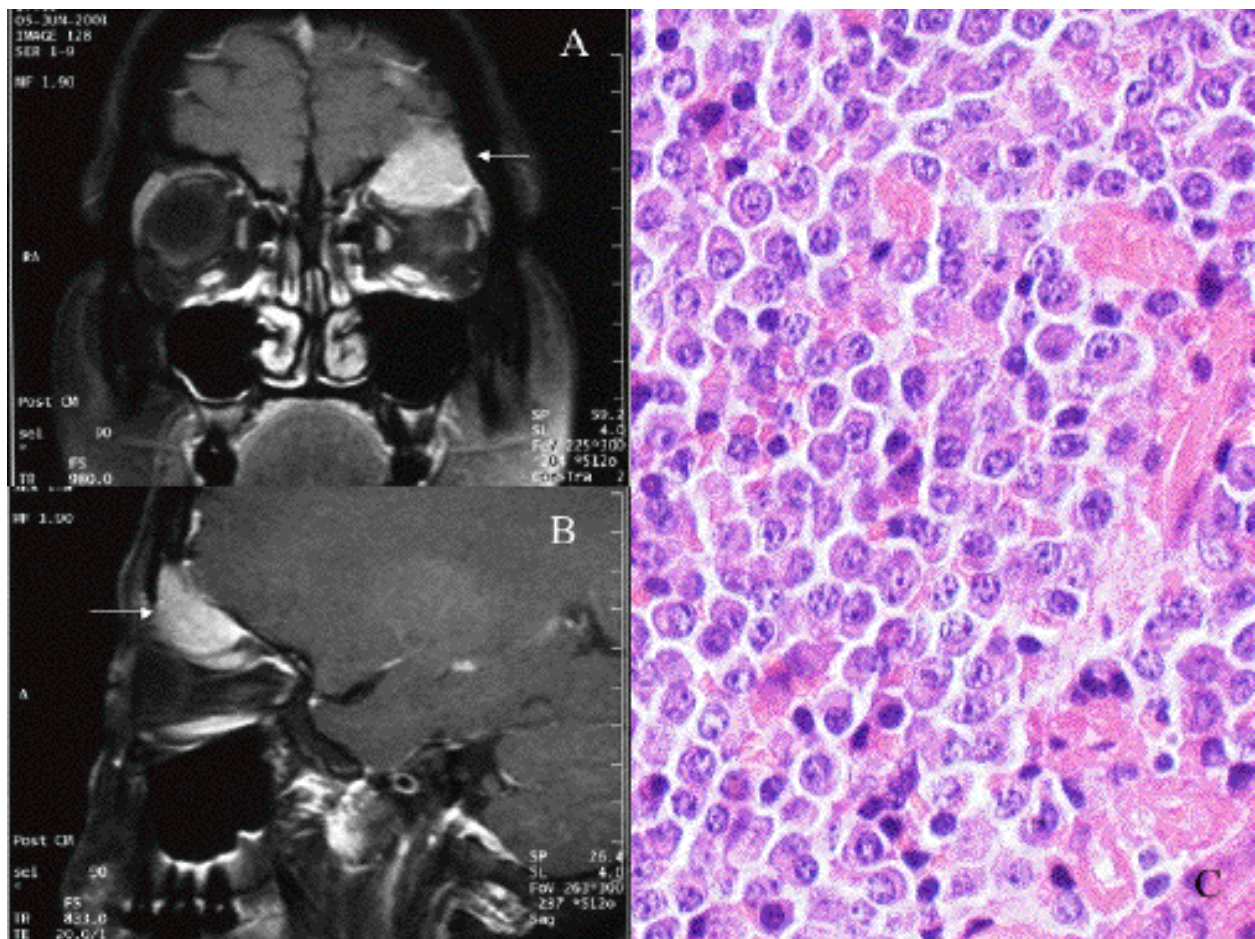


Figure 1A, B, C.

plasmacytomas. Systemic chemotherapy plus local irradiation would be the treatment of choice. In our case, the risks associated with major neural and ophthalmic surgery may have been averted. However, the risk of nerve and vascular compression at the cone of orbit probably warrant rapid intervention should early systemic screening be unavailable or unrewarding.

H Charmaine,¹ W.Y. Au,² T.W. Shek³

Department of ¹Ophthalmology, ²Medicine, ³Pathology, Queen Mary Hospital, Hong Kong.

Correspondence: Dr. W. Y. Au

University Department of Medicine, 4/F, Professorial Block, Queen Mary Hospital, Hong Kong

Tel: 852- 28554792 Fax: 852-29741165