



Lymphoid blastic crisis in Philadelphia chromosome-positive chronic granulocytic leukemia following high-grade non-Hodgkin's lymphoma. A case report and review of literature

LUCA MELE, LIVIO PAGANO, FRANCESCO EQUITANI, PATRIZIA CHIUSOLO, ELENA ROSSI, GINA ZINI, LUCIANA TEOFILI, GIUSEPPE LEONE

Istituto di Semeiotica Medica, Università Cattolica del Sacro Cuore, Rome, Italy

ABSTRACT

In this paper we describe a case of a 65-year old man with a lymphoid blastic crisis of a chronic granulocytic leukemia occurring seven years after a palatine tonsillar non-Hodgkin's lymphoma treated with chemotherapy and radiation therapy. Bone marrow cytogenetic study demonstrated the presence of the typical t(9;22)(q34;q11) and the molecular biology study showed the p210 rearrangement (b2a2). The patient died within a few months, unresponsive to any treatment. This is the first case, described in literature, of a secondary chronic granulocytic leukemia onset with a lymphoid blastic crisis. The authors report the case and a literature review.

©2000, Ferrata Storti Foundation

Key words: lymphoma; chronic granulocytic leukemia; lymphoid blastic crisis

Myelodysplastic syndromes (MDS) and secondary acute myeloid leukemia (sAML) are well recognized complications of chemotherapy and in particular of alkylating agents and epipodophyllotoxins which are considered the most leukemogenic drugs.¹⁻³ Rare cases of chronic granulocytic leukemia (CGL) following other malignancies have been reported.⁴⁻²⁴ In this paper we describe the case of a lymphoid blastic crisis in CGL occurring seven years after treatment for a non-Hodgkin's lymphoma (NHL). Furthermore we review the literature on associations between CGL and prior malignancies.

Case report

In June 1991 a 58-year old Caucasian male developed a palatine tonsillar diffuse centroblastic-centrocytic NHL (follicle center lymphoma grade III according to the REAL classification). The patient underwent a right tonsillectomy and investigations to stage the disease. A total body CT scan showed involvement of the right latero-cervical lymph nodes. Bone marrow biopsy and smear were negative for

NHL involvement. The stage was defined as IIEA. The patient received 3 cycles of the COPP regimen chemotherapy given every four weeks from July until October 1991. The COPP regimen is cyclophosphamide 600 mg/m² days 1 and 8, vincristine 1.5 mg/m² days 1 and 8, procarbazine 100 mg/m² day 1 to 15, and methylprednisolone 40 mg/m² day 1 to 15. Chemotherapy was followed by radiotherapy to the right tonsillar fossa, latero-cervical and supra-clavicular regions (total dose of 11 Gy) from November 1991 until December 1991. The patient achieved a complete remission and from May 1992 was off therapy. Over the following years, the patient did not have any clinical or radiographic signs compatible with NHL relapse, and hematologic and chemical examinations were normal.

In May 1998 he suffered sudden, severe asthenia. Physical examination demonstrated mild enlargement of the spleen, without hepatomegaly or lymphadenopathy. Abdominal ultrasound confirmed the presence of splenomegaly (bipolar diameter 14 cm).

Hematologic and chemical examinations

Analysis of peripheral blood revealed anemia (Hb 0.84 g/L), thrombocytopenia (Plt 57×10⁹/L), and leukocytosis (WBC count 98.8×10⁹/L, with 35% neutrophils, 20% lymphocytes, 5% monocytes, 4% eosinophils, 11% immature granulocytes, blasts 25%, and 2 orthochromatic erythroblasts every 100 leukocytes). A high serum level of LDH (1,001 IU/dL) was present. All the other chemical parameters were within normal ranges.

Bone marrow morphology

A bone marrow smear was hypercellular with 39% blasts, 19% cells of granulopoietic lineage, 15% erythroblasts, 27% lymphocytes and very rare megakaryocytes. Granulocytic and erythropoietic precursor showed dysplastic features with megaloblastic appearance. The great majority of the blast cell population in blood and bone marrow was composed of small-to-medium size peroxidase negative immature morphologically undifferentiated cells, with a high nuclear-cytoplasmic ratio, scanty cytoplasm without granules and one or two nucleoli (Figure 1).

Immunophenotypic, cytogenetic and molecular biology studies

Immunophenotypic analysis of the bone marrow blasts showed: CD10 48%, CD19 62%, CD22 54%,

Correspondence: Luca Mele, M.D., Istituto di Semeiotica Medica, Università Cattolica del Sacro Cuore, largo Francesco Vito 1, 00168 Rome, Italy. Phone: international +39-06-30154180 - Fax international +39-06-3051343 - E-mail: liviop@osa.net

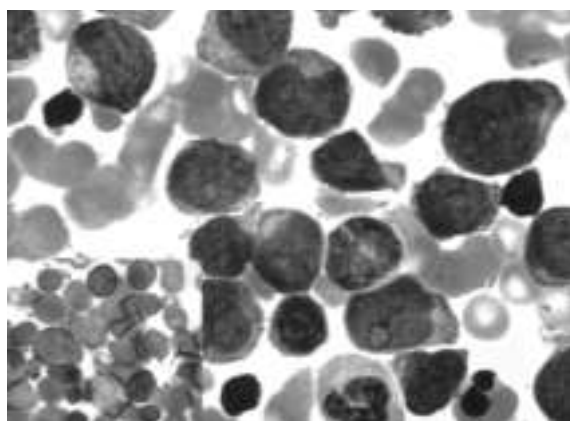


Figure 1. Two different types of blasts in the bone marrow. Small-to-medium size blasts are morphologically undifferentiated, with a high nuclear-cytoplasmic ratio, scanty cytoplasm without granules and one or two nucleoli; these cells are myeloperoxidase negative (see insert). A smaller proportion of blasts have cytoplasmic granules and are myeloperoxidase-positive.

CD45 94%, CD33 83%, CD34 79%, MPO 2%, TdT 60%.

Chromosome analysis was performed according to standard techniques with R and G banding, according to the International System for Cytogenetic Nomenclature.²⁵ Six cells were evaluable and characterized by the presence of t(9;22)(q34;q11) in all analyzed mitoses; no other abnormalities were found.

The molecular biology study, performed by the reverse-transcriptase chain reaction (RT-PCR) technique, as elsewhere described,²⁶ demonstrated the p210 rearrangement (b2a2).

Treatment and outcome

These data allowed us to make the diagnosis of lymphoid blastic crisis in Ph1 chromosome-positive CGL. The patient was, therefore, started on induction treatment according to the GIMEMA ALL 0288 trial²⁷ (vincristine 2 mg/m² i.v., days 1, 8, 15, and 22; daunorubicin 40 mg/m² i.v. days 1, 8, and 15; asparaginase 6,000 U/m² d15 to 21; methylprednisolone 60 mg/m² days 1 to 14; methylprednisolone 40 mg/m² days 15 to 31) but did not respond. Another chemotherapy course including cytarabine (2,000 mg/m² i.v. days 1 to 5), idarubicin (20 mg/m² i.v. day 3), G-CSF (300 µg s.c. days 7 to 20) was given but the patient was again resistant. The patient died in February, 1999 of progressive disease.

Discussion

Treatment-related leukemias are a well recognized event, in mostly cases being AML or MDS.¹⁻³ Rarely, secondary acute lymphoblastic leukemia (sALL) has been reported.²⁸ From 1983 to date only a few cases of CGL following a previous malignancy (PM) have been reported (Table 1).⁴⁻²⁴ Epidemiologic multicenter studies, performed on large series of patients with neoplasia, demonstrated the possibility of CGL after Hodgkin's disease, ovarian cancer, breast cancer, uterine cancer and other malignancies.²⁹⁻³⁵ However, these reports lacked clinical or laboratory data that

could be useful for clear definition of the real features of secondary CGL (sCGL).

In the last 15 years, including our case, 32 adult patients (M/F 18/14, median age 46 years, range 19-77) with sCGL have been reported in literature. Hematologic malignancies are the most prevalent PMs reported (22/32, 69%) (10 Hodgkin's disease, 5 NHL, 4 CLL, and 3 ALL). In all cases chemotherapy and/or radiotherapy was employed. Eight patients were treated with chemotherapy alone, 9 with only radiotherapy and the remaining 15 patients received combined chemo-radiotherapy. The median latency between the two malignancies was 60 months (range 18-192) (in one case the latency was not reported) and in all patients, except in our case, sCGL was diagnosed in a chronic phase. A meta-analysis of survival, performed on 21 evaluable cases, showed a median survival of 18 months (range 3-216). The prognosis of these patients appears poor, and it seems that the outcome of sCGL is worse than *de novo* CGL. This consideration is strengthened by comparison of these data with those from patients with *de novo* CGL enrolled in the *Italian Co-operative Study Group on Chronic Myeloid Leukemia*, who had a longer median survival (69 months for the interferon- α arm and 46 months for the chemotherapy arm).³⁶

In a recent review, Pedersen-Bjergaard *et al.*²⁴ reported 26 cases of Ph1 chromosome positive AML, ALL, and CGL following chemotherapy for Ph1 chromosome negative leukemia or other malignancies. These patients received different antineoplastic combinations for primary malignancy, with or without radiotherapy. Even though alkylating agents were administered to half of the patients, the authors hypothesized that the various types of chemotherapies, including anthracyclines and epipodophyllotoxins, had a common mechanism of provoking balanced chromosome aberrations, and could be considered the most relevant leukemogenic agents.

On the other hand, ionizing radiation can be involved in leukemic transformation, as well reported in literature.^{10,37,38} In particular, in 1996 Melo *et al.* reported a BCR/ABL fusion gene which may be induced in cultured cells exposed *in vitro* to high-dose ionizing radiation.³⁹

Here we report the case of a Ph1 chromosome positive CGL following chemotherapy, diagnosed during the lymphoid blastic crisis phase. Peripheral blood and bone marrow morphologic features with circulating immature granulocytes, immunophenotype and molecular biology studies strongly supported a diagnosis of sCGL, although the possibility of a Ph1 chromosome positive ALL could not be completely excluded. However, the latency between NHL and sCGL (7 years) and the treatments received for the PM, alkylating agents and radiotherapy, suggest that these could have been responsible for the sCGL. Nevertheless, in a large series of patients with acute leukemia, many cases of secondary leukemia developed after a PM not treated with chemo and/or radiotherapy.⁴⁰ This observation suggests the possibility of a familial predisposition. We cannot exclude that sCGL might simply represent randomly occurring cases of *de novo* CGL in the many thousands of patients being followed-up after previous chemo-

Table 1. Literature review and present case.

Authors	Year	Sex/Age	PM	Treatment				Latency (months)	CML characteristics at the diagnosis			Survival (months)
				Surgery	Chemotherapy	Radiotherapy (Gy)			CML Phase	Karyotype	Molecular Biology	
Ritch et al. ⁽⁴⁾	1983	m/37	HD	N	/	nr	46	Chronic	Ph ¹	nd	216+	
William et al. ⁽⁵⁾	1984	m/20	HD	N	nr	nr	44	Chronic	Ph ¹	nd	57	
Schreiber et al. ⁽⁶⁾	1984	m/55	CLL	N	Chl	/	92	Chronic	Ph ¹ +chr(?)	nd	18+	
Teichmann et al. ⁽⁷⁾	1985	f/53	CLL	N	Chl+COP	/	70	Chronic	Ph ¹	nd	15+	
Auerbach et al. ⁽⁸⁾	1987	m/66	NHL	N	Cyt+ADR+VCR+ Intrathecal MTX	22	57	Chronic	Ph ¹ -chr 7	Bcr/abl	3	
Punt et al. ⁽⁹⁾	1987	m/23	HD	N	MOPP	nr	60	Chronic	Ph ¹	nd	132+	
Philip et al. ⁽¹⁰⁾	1988	f/64	Uterus	Y	/	40	81	Chronic	Ph ¹ +t(6;8)	nd	nr	
		f/51	Uterus	Y	/	40	27	Chronic	Ph ¹	nd	nr	
		m/37	Uterus	Y	/	35	36	Chronic	Ph ¹	nd	nr	
Dastugue et al. ⁽¹¹⁾	1988	f/57	NHL	N	/	24	84	Chronic	Complex + Ph ¹	nd	12	
Whang-Peng et al. ^{*(12)}	1988	m/74	CLL	N	nr	/	24	Chronic	Ph ¹ -Y	nd	24+	
		f/77	NHL	N	COP	/	nr	Chronic	Ph ¹	nd	7	
		f/36	ALL	N	ASP+VCR+ Intrathecal MTX	/	18	Chronic	Complex + Ph ¹	nd	34	
		f/26	ALL	N	MTX+VCR+6 MP	/	120	Chronic	Complex, no Ph ¹	nd	5+	
		m/58	CLL	N	/	nr	36	Chronic	Ph ¹	nd	19	
		f/52	Breast	Y	/	nr	108	Chronic	Ph ¹	nd	nr	
		f/32	HD	N	MOPP	nr	84	Chronic	Complex, no Ph ¹	nd	24	
		m/24	HD	N	MOPP	nr	46	Chronic	Ph ¹	nd	12	
		f/44	Breast	Y	CTX+MTX+5FU	nr	96	Chronic	Complex + Ph ¹	nd	31	
Leone et al. ⁽¹³⁾	1988	f/59	ALL-L2	N	VCR+DNB+ASP+ Intrathecal MTX	18	42	Chronic	Ph ¹	nd	24+	
Jurlo et al. ⁽¹⁴⁾	1989	m/47	Seminoma	Y	/	30	48	Chronic	Ph ¹	nd	24+	
Verhoef et al. ⁽¹⁵⁾	1990	m/57	HD	N	MOPP	/	96	Chronic	Ph ¹	Bcr/abl	10+	
Cazzola et al. ⁽¹⁶⁾	1990	f/59	NHL	N	COP	78	84	Chronic	Ph ¹	Bcr/abl	17+	
Walgraave et al. ⁽¹⁷⁾	1991	m/42	Thyroid	Y	/	¹³¹ I 30 mCi	60	Chronic	Ph ¹	Bcr/abl	nr	
Bouabdallah et al. ⁽¹⁸⁾	1991	m/54	HD	N	VNB	40	192	Chronic	Ph ¹ +chr 8	Bcr/abl	22	
Berman et al. ⁽¹⁹⁾	1991	m/35	HD	N	CAV+MOPP+ABV	40	38	Chronic	Ph ¹	Bcr/abl	14+	
Jackson et al. ⁽²⁰⁾	1994	f/19	HD	N	VCR+ETP+PrG+Chl+ ADR+VNB+Bleo	30	22	Chronic	Ph ¹	nd	12+	
Aguiar et al. ⁽²¹⁾	1994	m/42	Thymoma	Y	Chl	12	48	Chronic	Ph ¹	Bcr/abl	12	
Chap et al. ⁽²²⁾	1994	f/35	Histiocytosis X	N	VNB	46 (+ ¹²⁵ I)	156	Chronic	Ph ¹	nd	24+	
Salvagno et al. ⁽²³⁾	1994	m/37	HD	N	Mechl+ADR+VCR+VNB	36	43	Chronic	Ph ¹	nd	205	
Pedersen-Bjerggaard et al. ⁽²⁴⁾	1997	m/46	Seminoma	Y	ETP+CPL+Bleo	/	60	Chronic	Ph ¹ +chr 8	Bcr/abl	8+	
Present case	1998	m/64	NHL	N	CTX+VCR+Pro	11	84	LBC	Ph ¹	Bcr/abl	9	

PM: primary malignancy; CLL: chronic lymphocytic leukemia; LBC: lymphoid blastic crisis; ADR: adriamycin; ASP: asparaginase; bleo: bleomycin; Chl: chlorambucil; CPL: cisplatin; Cyt: cytoxane; CTX: cyclophosphamide; DNB: daunoblastine; ETP: etoposide; ABV: ADR+Bleo+VNB; MOPP: mechlorethamine (Mechl)+VCR+prednisone+Pro; MTX: methotrexate; Pro: procarbazine; VCR: vincristine; VNB: vinblastine; ALL: acute lymphoblastic leukemia; HD: Hodgkin's disease; NHL: non-Hodgkin's lymphoma; nd: not done; nr: not reported by the authors. ? : extra chromosome was not identified.

*This paper reports the cases observed between 1967-1987 at the National Cancer Institute, Bethesda and the Veteran's Administration Medical Center, Washington, USA.

and/or radiotherapy.

Further epidemiologic studies on large series of CGL patients, conducted retrospectively and prospectively, could be helpful to know the influence of a PM on the development of sCGL.

Contributions and Acknowledgments

LM and LP designed the study and were responsible for writing the paper. PC, GZ and ER performed biological studies. LM, LP, FE and LT followed the patient clinically. GL reviewed the manuscript and approved its final form. The criterion for the order in which the authors appear is based on the importance of their contribution to the paper.

Funding

This work was supported in part by a grant from MURST 60% (Università Cattolica S. Cuore, Rome, Italy).

Disclosures

Conflict of interest: none.

Redundant publications: no substantial overlapping with previous paper.

Manuscript processing

Manuscript received July 5, 1999; accepted January 17, 2000.

References

- Smith MA, McCaffrey RP, Karp JE. The secondary leukemias: challenges and research directions. *J Natl Cancer I* 1996; 88:407-18.
- Estey E, Thall P, Beran M, Kantarjian H, Pierce S, Keating M. Effect of diagnosis (refractory anemia with excess blasts, refractory anemia with excess blasts in transformation, or acute myeloid leukemia [AML]) on outcome of AML-type chemotherapy. *Blood* 1997; 90:2969-77.
- Kantarjian HM, Keating MJ, Walters RS, et al. Therapy-related leukemia and myelodysplastic syndrome: clinical, cytogenetic, and prognostic features. *J Clin Oncol* 1986; 4:1748-57.
- Ritch PS, Anderson T, Hanson GA, Pisciotto AV. Chronic granulocytic leukemia following radiation therapy for Hodgkin's disease. *Cancer* 1983; 52: 462-4.
- Tester WJ, Kinsella TJ, Waller B, et al. Second malignant neoplasms complicating Hodgkin's disease: the National Cancer Institute experience. *J Clin Oncol* 1984; 2:762-9.
- Schreiber ZA, Axelrod MR, Abebe LS. Coexistence of chronic myelogenous leukemia and chronic lymphocytic leukemia. *Cancer* 1984; 54:697-701.

7. Teichmann JV, Sieber G, Ludwig WD, Karow J, Ruehl H. Chronic myelocytic leukemia as a second neoplasia in the course of chronic lymphocytic leukemia. Case report and review of the literature. *Leuk Res* 1986; 10:361-8.
8. Auerbach HE, Stelmach T, LaGuette JG, Glick JH, Kant JA, Nowell PC. Secondary Ph-positive CML with a minority monosomy 7 clone. *Cancer Genet Cytogen* 1987; 28:173-8.
9. Punt CJ, Rozenberg-Arska M, Verdonck LF. Successful treatment with chemotherapy and subsequent allogeneic bone marrow transplantation for myeloid blastic crisis of chronic myelogenous leukemia following advanced Hodgkin's disease. *Cancer* 1987; 60:934-5.
10. Philip P, Pedersen-Bjergaard J. Cytogenetic, clinical, and cytologic characteristics of radiotherapy-related leukemias. *Cancer Genet Cytogen* 1988; 31:227-36.
11. Dastugue N, Demur C, Pris F, et al. Association of the Philadelphia chromosome and 5q- in secondary blood disorder. *Cancer Genet Cytogen* 1988; 30:253-9.
12. Whang-Peng J, Young RC, Lee EC, Longo DL, Schechter GP, DeVita VT Jr. Cytogenetic studies in patients with secondary leukemia/dysmyelopoietic syndrome after different treatment modalities. *Blood* 1988; 71:403-14.
13. Leone G, Marra R, Pagano L, et al. Ph1-chromosome-positive chronic myelogenous leukemia following a 1-year "off-therapy" acute lymphoblastic leukemia. *Oncology* 1988; 45:389-91.
14. Iurlo A, Foa P, Maiolo AT, Polli EE. Chronic myelogenous leukemia following radiation therapy for testicular seminoma. *Blut* 1989; 59:503-4.
15. Verhoef GE, Demuyneck H, Stul MS, et al. Philadelphia chromosome-positive chronic myelogenous leukemia in treated Hodgkin's disease. *Cancer Genet Cytogen* 1990; 49:171-6.
16. Cazzola M, Bergamaschi G, Melazzini M, Ponchio L, Rosti V, Molinari E. Chronic myelogenous leukemia following radiotherapy and chemotherapy for non-Hodgkin lymphoma. *Haematologica* 1990; 75:477-9.
17. Walgraave D, Verhoef G, Stul M, et al. Chronic myelogenous leukemia after treatment with 131I for thyroid carcinoma. Report of a case and review of the literature. *Cancer Genet Cytogen* 1991; 55:217-24.
18. Bouabdallah K, Marit G, Reiffers J, et al. Hodgkin's disease and secondary Philadelphia chromosome positive chronic myelogenous leukemia. *Cancer Genet Cytogen* 1991; 55:277-8.
19. Berman E, Strife A, Wisniewski D, et al. Duration of the preclinical phase of chronic myelogenous leukemia: a case report. *Blood* 1991; 78:2969-72.
20. Jackson GH, Latham JA, Lennard AL, Taylor PR, Proctor SJ. Rapid onset of chronic granulocytic leukaemia after treatment for Hodgkin's disease. *Br J Haematol* 1994; 87:193-5.
21. Aguiar RC, Beitler B, Dorlhiac-Llacer PE, Chamone DA. Secondary chronic myelogenous leukemia: a diverse pathogenesis? *Acta Haematol* 1994; 92:101-3.
22. Chap L, Nimer SD. Chronic myelogenous leukemia following repeated radiation therapy for histiocytosis X. *Leuk Lymphoma* 1994; 12:315-6.
23. Salvagno L, Sorarù M, Leszl A, Koussis H, De Franchis G, Fiorentino MV. Prolonged survival (17 years) in a patient with chronic myelogenous leukemia after therapy for Hodgkin's disease. *Leuk Lymphoma* 1994; 16:177-81.
24. Pedersen-Bjergaard J, Brøndum-Nielsen K, Karle H, Johansson B. Chemotherapy-related, late occurring, Philadelphia chromosome in AML, ALL, and CML. Similar events related to treatment with DNA topoisomerase II inhibitors? *Leukemia* 1997; 11:1571-4.
25. An international system for human cytogenetic nomenclature, ISCN (1978). Report of the Standing Committee on Human Cytogenetic Nomenclature. *Cytogenet Cell Genet* 1978; 21:309-409.
26. Chomczynski P, Sacchi N. Single-step method of RNA isolation by acid guanidium thiocyanate-phenol-chloroform extraction. *Ann Biochem* 1987; 162:156-9.
27. Mandelli F, Annino L, Vegna ML, et al. GIMEMA ALL 0288: a multicentric study on adult acute lymphoblastic leukemia. Preliminary results. *Leukemia* 1992; 6(suppl. 2):182-5.
28. Pagano L, Pulsoni A, Tosti ME, et al. Adult acute lymphoblastic leukaemia occurring as second malignancy: report of the GIMEMA archive of adult acute leukaemia. Gruppo Italiano Malattie Ematologiche Maligne dell'Adulto. *Br J Haematol* 1999; 106:1037-40.
29. Kaldor JM, Day NE, Pettersson F, et al. Leukemia following chemotherapy for ovarian cancer. *N Engl J Med* 1990; 322:1-6.
30. Kaldor JM, Day NE, Clarke EA, et al. Leukemia following Hodgkin's disease. *N Engl J Med* 1990; 322:7-13.
31. Travis LB, Curtis RE, Boice JD Jr, Platz CE, Hankey BF, Fraumeni JF Jr. Second malignant neoplasm among long-term survivors of ovarian cancer. *Cancer Res* 1996; 56:1564-70.
32. Nandakumar A, Davis S, Moolgavkar RP, Witherpoon RP, Schwartz SM. Myeloid leukaemia following therapy for a first primary cancer. *Br J Cancer* 1991; 63:782-8.
33. Hass JF, Kittelmann B, Mehnert WH, et al. Risk of leukaemia in ovarian tumour and breast cancer patients following treatment by cyclophosphamide. *Br J Cancer* 1987; 55:213-8.
34. Curtis RE, Boice JD Jr, Stovall M, et al. Relationship of leukemia risk to radiation dose following cancer of the uterine corpus. *J Natl Cancer I* 1994; 86:1315-24.
35. Curtis RE, Boice JD Jr, Stovall M, Flannery JT, Moloney WC. Leukemia risk following radiotherapy for breast cancer. *J Clin Oncol* 1989; 7:21-9.
36. The Italian Cooperative Study Group on Chronic Myeloid Leukemia. Long-term follow-up of the Italian trial of interferon-alpha versus conventional chemotherapy in chronic myeloid leukemia. *Blood* 1998; 92:1541-8.
37. Vaughan WP, Karp JE, Burke PJ. Effective chemotherapy of acute myelocytic leukemia occurring after alkylating agent or radiation therapy for prior malignancy. *J Clin Oncol* 1983; 1:204-7.
38. Levine EG, Bloomfield CD. Leukemias and myelodysplastic syndromes secondary to drug, radiation, and environmental exposure. *Semin Oncol* 1992; 19:47-84.
39. Melo JV, Deininger M, Yan XH, Bose S, Goldman JM. Transcriptionally functional BCR-ABL fusion genes can be induced in vitro by high-dose ionizing radiation. *Blood* 1996; 88(Suppl 1):633a.
40. Pagano L, Pulsoni A, Invernizzi R, et al. Secondary acute leukemia. Report of GIMEMA Archive of Adult Acute Leukemia. *Br J Haematol* 1998; 102(Suppl 1):144.