# Acute heparin-induced thrombocytopenia following aortic dissection repair with platelet count recovery and anti-platelet factor 4/heparin antibody seroreversion despite ongoing device-related heparin exposure

A 39-year-old man with Loeys-Dietz syndrome (congenital connective tissue disorder characterized by widespread arterial aneurysms and risk for aortic dissection[1]), a history of right pontine stroke 3 years earlier (suspected to be related to an embolism from basilar artery stenosis, without documented heparin exposure) and a known aortic root aneurysm, presented with chest pain, fever, and dyspnea. Imaging confirmed a type A aortic dissection, and he underwent an emergent Bentall procedure with On-X mechanical aortic valve replacement. He received systemic unfractionated heparin during cardiopulmonary bypass. Postoperatively, he was started on dalteparin prophylaxis, warfarin, and aspirin (Figure 1).

By postoperative day (POD) 6, corresponding to day 6 following his initial intraoperative heparin exposure, his international normalized ratio (INR) was within the target therapeutic range (2.0-3.0). All subsequent reference to POD numbers refers to days after the initial surgery (Bentall procedure). A postoperative computed tomography (CT) scan demonstrated residual dissection with false lumen extension into the innominate and left common carotid arteries. On POD10, he was transitioned to an intravenous heparin infusion at therapeutic dose (target activated partial thromboplastin time [APTT], 49 to 65 seconds) in preparation for additional surgeries. On POD11, he underwent left common carotid to subclavian bypass. The following day (POD12, but 1 day following carotid to subclavian artery vascular surgery), planned Frozen Elephant Trunk and Endovascular Aneurysm Repair (EVAR) procedures were aborted due to acute thrombosis of the bypass graft, requiring thrombectomy. His platelet count dropped to $110\times10^9$/L from a peak of $347\times10^9$/L on POD10, and CT imaging revealed new left segmental pulmonary emboli.

Review of the precise sequence of platelet count decline showed that there had been a drop in the platelet count upon starting therapeutic-dose heparin that preceded the second surgical event; the platelet count fell by 34.6% (from $347\times10^9$/L to $227\times10^9$/L) after initiation of therapeutic-dose heparin and fell further to $110\times10^9$/L after surgery (performed with heparin anticoagulation). Given a 4Ts score of 6 points (>50% platelet count fall [2 points]; onset day 11 [1 point]; documented thromboses including pulmonary embolism [2 points]; and coinciding surgery possibly contributing to platelet count fall [1 point]), a heparin-induced thrombocytopenia (HIT) assay was performed, heparin was discontinued, and bivalirudin was initiated.

Platelet nadir ($109\times10^9$/L) occurred on POD13, with subsequent recovery. The initial (screening) anti-platelet factor 4 (PF4)/polyanion immunoassay (latex immunoturbidimetric assay [LIA])[2] was positive at 2.4 U/mL (reference range <1.0 U/mL). The patient's blood sample was referred to the national reference HIT laboratory, at McMaster University. An IgG-specific enzyme-linked immunosorbent assay (ELISA) also yielded a positive result (1.42 optical density [OD] units [reference range, <0.40 OD units]). The serotonin-release assay (SRA),[3] which indicates presence of pathological platelet-activating antibodies, was positive, demonstrating 71% and 81% reactivity at 0.1 U/mL and 0.3 U/mL of heparin, respectively. There was no reactivity at 0 U/mL and 100 U/mL, consistent with a diagnosis of classic (i.e., predominantly heparin-dependent) heparin-induced thrombocytopenia (HIT).[3,4]

Additional vascular repair was required and 2 weeks later (POD28) the patient underwent thoracic endovascular aortic repair (TEVAR), under anticoagulation coverage with bivalirudin. The left common carotid artery also required stenting and a Gore VBX stent was placed. Given that this stent is covalently heparin-bonded, and given evidence that high-dose intravenous immunoglobulin (IVIG) can reduce heparin-dependent platelet activation through competitive inhibition of HIT antibody-mediated platelet activation via platelet FcγIIa receptors,[5] a single, 90 g dose of IVIG was given after stent placement. A repeat HIT assay was performed using a blood sample obtained immediately prior to IVIG administration. The LIA remained positive (1.1 U/mL), and the SRA again demonstrated heparin-dependent platelet activation, albeit with a lower degree of serum-induced platelet activation (41% and 54% serotonin-release at 0.1 and 0.3 U/mL of heparin, respectively). No additional IVIG was given, and no immunosuppressive medications (e.g., corticosteroids, azathioprine, cyclophosphamide) were given at any time.

On POD32, a repeat immunoassay (LIA) was negative, suggesting early seroreversion. Bivalirudin was continued for the remainder of his admission. Warfarin was restarted following platelet recovery, and the patient was discharged

once therapeutic levels of warfarin anticoagulation were achieved. Repeat immunoassay (LIA) following discharge was negative when repeated on POD58, POD66 and POD159; repeat SRA results were also negative (0% release at 0.1 and 0.3 U/mL of heparin) on POD58 and on POD159. Further corroborating data supporting antibody seroreversion included declining reactivities (POD58 *vs*. POD28) in two different ELISA and in a PF4/polyanion chemiluminescence immunoassay (CLIA),[6] although the POD159 sample was no longer available for repeat testing in these three immunoassays (Figure 1). The patient provided informed consent for this report; the local Research Ethics Board approved the application to submit this report.

Classic HIT is a prothrombotic immune complication of heparin therapy-mediated by platelet-activating antibodies directed against PF4/heparin complexes. Management typically involves cessation of heparin, avoidance of further heparin exposure, and initiation of non-heparin anticoagulation.[7] However, in patients requiring vascular interventions, complete avoidance of heparin may be difficult, particularly when heparin-bonded grafts or stents are the only suitable options for management.

Heparin coating enhances blood compatibility of vascular devices by reducing surface thrombogenicity. Bonding methods fall into two categories: covalent (non-heparin-eluting) and ionic (heparin-eluting) coatings.[8] Covalently-bound heparin systems, such as the Carmeda BioActive Surface (CBAS) technology used in the Gore VBX graft inserted into our patient, generally employ end-point linkage that preserves heparin's antithrombin-binding site while preventing leaching into the circulation. By contrast, ionically bonded systems use electrostatic attachment or lipophilic compounds, resulting in gradual heparin release over several days. The total heparin load within a CBAS-coated device is minimal, typically less than 400 units per graft and does not elute into the plasma.[8] Even theoretical full release would yield circulating concentrations below 0.1 U/mL, far below the threshold necessary to

| | | | | | | |
|---|---|---|---|---|---|---|
| **LIA (<1.0 U/mL)** | 2.4 | 1.1 | 0.8 | 0.7 | 0.5 | 0.3 |
| **SRA, peak % release (<20%)** | 81 | 54 | -- | 0 | | 0 |
| **ELISA-IgG (<0.45 OD units)** | 1.42 | 1.42 | -- | 0.94 | | -- |
| **ELISA-IgG/A/M (<0.40 OD units)** | -- | 1.56 | -- | 1.12 | | -- |
| **CLIA (<1.0 U/mL)** | -- | 10.85 | -- | 3.69 | | -- |

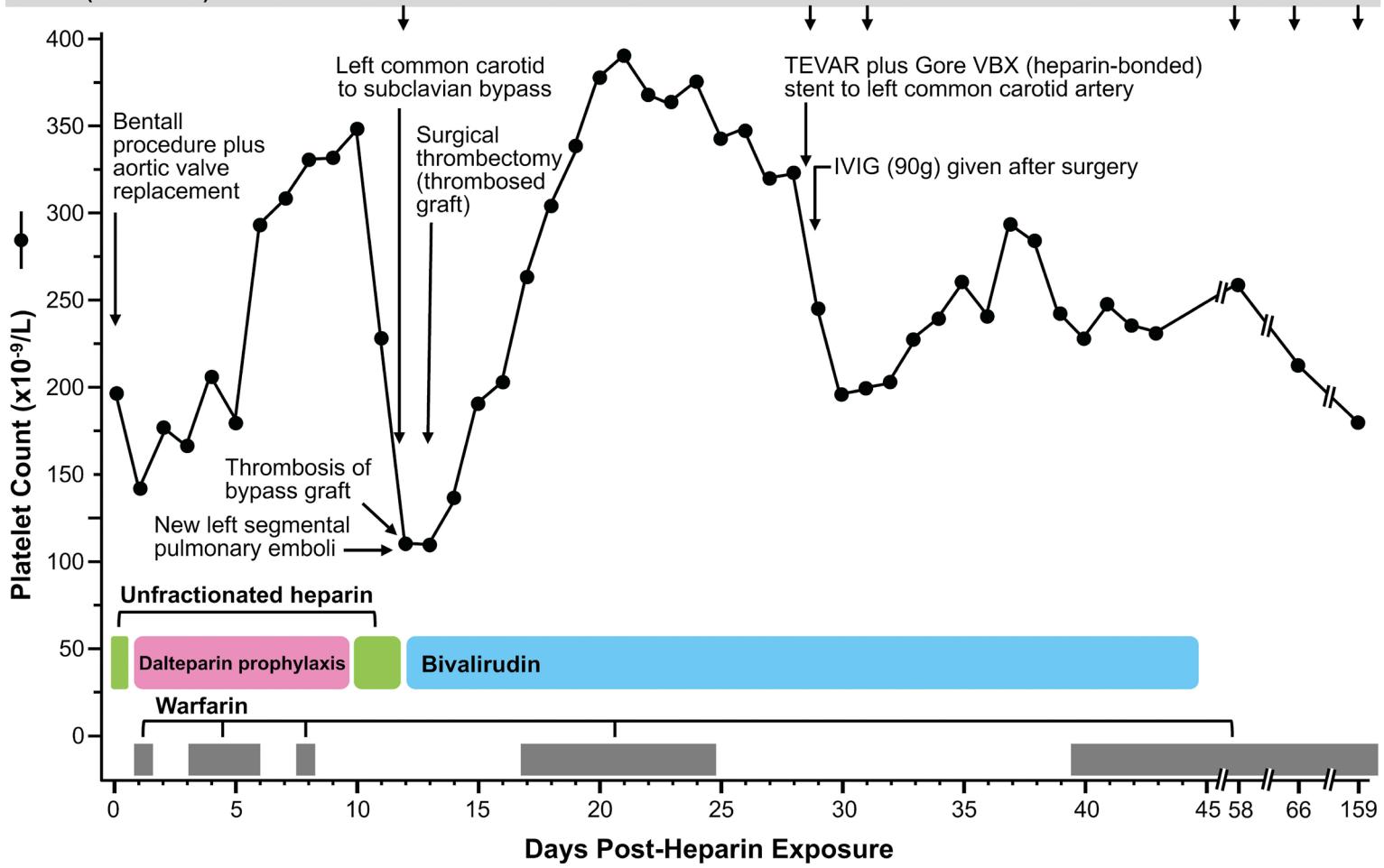


**Figure 1. Clinical course, serial platelet counts, and heparin-induced thrombocytopenia (HIT) assay results in relationship to clinical HIT complicating surgery for aortic dissection followed by placement of a heparin-bonded stent.** Platelet count values over 159 days following initial systemic heparin exposure for cardiac surgery (Bentall procedure plus aortic valve replacement), with subsequent development of HIT on day 11, with positive testing for HIT antibodies by several HIT immunoassays and serotonin-release assay (SRA). Subsequently, despite thoracic endovascular aortic repair (TEVAR) with insertion of heparin-bonded stent, platelet count levels remained normal, and HIT antibody seroreversion (waning or loss of reactivity) was documented. CLIA: chemiluminescence immunoassay; ELISA: enzyme-linked immunosorbent assay; IVIG: intravenous immunoglobulin; LIA: latex immunoturbidimetric assay.

form PF4/heparin complexes at stoichiometric conditions permitting binding by HIT antibodies.

Clinical series and case reports support the safety of covalently bonded heparin-coated devices in the setting of HIT. Conversely, reports of HIT attributed to heparin-coated rafts often involved delayed-onset (or autoimmune) HIT, a variant characterized by platelet activation independent of heparin.[8] A review of suspected cases of HIT following implant of heparin-bonded vascular grafts demonstrated that patients' platelet counts typically recovered despite leaving the grafts *in situ*,[8] indicating that the heparin-bonded material itself was not driving the immune response. It was also suspected that in those cases the HIT presentation was likely related to the systemic heparin associated with the initial surgery, as opposed to the graft itself. Of relevance to this discussion, observational studies of patients with acute HIT who received ongoing exposure to heparin (but without heparin-bonded grafts) have documented platelet count recovery and seroreversion despite continuing exposure to substantial doses of unfractionated heparin.[9-11]

Our patient demonstrated anti-PF4/heparin antibody seroreversion, despite undergoing placement of a heparin-bonded stent, characterized by loss or waning levels of detectable anti-PF4/heparin antibodies by several immunoassays and parallel loss of heparin-dependent platelet-activating properties of the patient's serum by SRA. A distinctive feature of HIT is the transient nature of the antibodies, with assay reactivity typically becoming negative within 50 to 80 days (median) following heparin cessation, depending on the type of assay performed (platelet activation and immunoassay, respectively).[12] This differs from other drug-dependent antibodies, which often persist for months to years.[9] Notably, seroreversion can occur even in patients who remain exposed to device- or graft-surface-bound heparin on a continuous basis,[8] as occurred in this case. Therefore, urgent explantation of heparin-coated stents or grafts is usually unwarranted once HIT is recognized and systemic heparin discontinued.[8] Rather, anticoagulation with non-heparin anticoagulation, possibly with administration of high-dose IVIG, together with ongoing surveillance with serial antibody testing (to document anticipated seroreversion) is typically sufficient.

This case underscores the complex interplay between ongoing surgical needs and HIT management. The successful use of a heparin-bonded stent despite the presence of HIT antibodies supports prior observations that immobilized heparin carries limited antigenic exposure. Previous cases have reported patients with HIT tolerated exposure to heparin-bonded circuits, grafts, or catheters without worsening of thrombocytopenia or thrombosis.[8] Our case extends this experience to carotid stenting following complex aortic repair. Further, a novel aspect of our case is that the heparin-bonded stent was placed at a time when heparin-dependent antibodies (detectable by SRA) were still present, although this only became evident in retrospect once the SRA performed on serum obtained at the time of the procedure became available. Nevertheless, the outcome was favorable, without any discernable adverse effects.

## Authors

Anna R. Blankstein,[1,2] Kaitlin P. Quinlan,[1,2] Roopesh Kansara,[1,2] Lin Yang,[1,2] Donald M. Arnold,[3,4] Ishac Nazy[3,4,5] and Theodore E. Warkentin[6]

[1]Department of Internal Medicine, University of Manitoba, Winnipeg, Manitoba; [2]Department of Medical Oncology and Hematology, CancerCare Manitoba, Winnipeg, Manitoba; [3]Michael G. DeGroote Center for Transfusion Research, McMaster University, Hamilton, Ontario; [4]Department of Medicine, McMaster University, Hamilton, Ontario; [5]Department of Biochemistry & Biomedical Sciences, McMaster University, Hamilton, Ontario and [6]Department of Pathology and Molecular Medicine, McMaster University, Hamilton, Ontario, Canada

Correspondence:
T. E. WARKENTIN - twarken@mcmaster.ca

https://doi.org/10.3324/haematol.2026.301162

Received: April 28, 2026.
Accepted: July 22, 2026.
Early view: July 30, 2026.

Published under a CC BY license

**Disclosures**

TEW has provided consulting services to Werfen, Paradigm Biopharmaceuticals, Siemens Healthineers, and Veralox Therapeutics; has received research funding from Werfen; and has provided expert testimony relating to HIT and non-HIT thrombocytopenic and coagulopathic disorders. The other authors have no conflicts of interest to disclose.

**Contributions**

ARB prepared the first manuscript draft and developed the figure. KPQ, RK, and LY oversaw patient care and made the initial diagnosis of HIT. DMA and IN oversaw laboratory testing at the McMaster Platelet Immunology Laboratory (reference laboratory). TEW reviewed laboratory test results and provided historical context of HIT antibody seroreversion literature. All authors reviewed and approved the final version of the manuscript.

**Acknowledgments**

The authors thank Jo-Ann I. Sheppard for assistance in manuscript submission.

**Funding**
The study was funded by the Canadian Institutes of Health Research (to IN).

**Data-sharing statement**
The data that support the findings of this study are available from the corresponding author upon reasonable request.

# References

1. MacCarrick G, Black JH, Bowdin S, et al. Loeys-Dietz syndrome: a primer for diagnosis and management. Genet Med. 2014;16(8):576-587.
2. Warkentin TE, Sheppard JI, Linkins LA, Arnold DM, Nazy I. Performance characteristics of an automated latex immunoturbidimetric assay [HemosIL® HIT-Ab(PF4-H)] for the diagnosis of immune heparin-induced thrombocytopenia." Thromb Res. 2017;153:108-117.
3. Warkentin TE, Arnold DM, Nazi I, Kelton JG. The platelet serotonin-release assay. Am J Hematol. 2015;90(6):564-572.
4. Warkentin TE, Greinacher A. Laboratory testing for heparin-induced thrombocytopenia and vaccine-induced immune thrombotic thrombocytopenia antibodies: a narrative review. Semin Thromb Hemost. 2023;49(6):621-633.
5. Warkentin TE, Climans TH, Morin PA. Intravenous immune globulin to prevent heparin-induced thrombocytopenia. N Engl J Med. 2018;378(19):1845-1848.
6. Warkentin TE, Sheppard JI, Linkins LA, Arnold DM, Nazy I. High sensitivity and specificity of an automated IgG-specific chemiluminescence immunoassay for diagnosis of HIT. Blood. 2018;132(12):1345-1349.
7. May J, Westbrook B, Cuker A. Heparin-induced thrombocytopenia: an illustrated review. Res Pract Thromb Haemost. 2023;7(5):100283.
8. Warkentin TE. Heparin-coated intravascular devices and heparin-induced thrombocytopenia. In: Warkentin TE, Greinacher A, editors. Heparin-Induced Thrombocytopenia. 5th ed. Boca Raton (FL); CRC Press; 2013. p. 573-590.
9. Greinacher A, Kohlmann T, Strobel U, Sheppard JI, Warkentin TE. The temporal profile of the anti-PF4/heparin immune response. Blood. 2009;113(20):4970-4976.
10. Warkentin TE, Sheppard JI, Heels-Ansdell D, et al. Heparin-induced thrombocytopenia in medical surgical critical illness." Chest. 2013;144(3):848-858.
11. Shih AW, Sheppard JI, Warkentin TE. Platelet count recovery and seroreversion in immune HIT despite continuation of heparin: further observations and literature review. Thromb Haemost. 2017;117(10):1868-1874.
12. Warkentin TE, Kelton JG. Temporal aspects of heparin-induced thrombocytopenia. N Engl J Med. 2001;344(17):1286-1292.