

**Table 1. Acenocoumarol requirements before, during and after 6-MP.**

	Pre-leukemia	X/95-VI/96	VIII/96-XI/97	After XI/97
INR	3.3	1.9	3.4	3.4
mg/week	21	70	71	21

In this paper, we report an increased acenocoumarol requirement in a patient receiving 6-MP. The patient was a 53-year old woman with an aortic prosthetic valve and aorto-coronary by-pass. She was on long-term OAT with acenocoumarol (mean dose 21 mg/week and mean INR=3.3) since January 1992 until August 1995. Her treatment included captopril, isosorbide trinitrate and furosemide. The level of hypocoagulability was measured every four weeks using bovine thromboplastin ISI=0.98 (Thrombotest from Nycomed, IMMUNO, Barcelona, Spain) with a mechanical coagulometer AMAX CS-90 (from Grifols-Movaco, Barcelona, Spain) assisted by a computer program (Sintromac from Grifols, Barcelona, Spain). Her dose of acenocoumarol was adjusted according to the results which were expressed as the INR as recommended by the *Subcommittee of Standardization of the International Society on Thrombosis and Hemostasis*. She had a mean INR = 3.37. In August 1995 she was diagnosed as having acute promyelocytic leukemia. Induction of specific treatment was excluded because of her age and cardiac disease. OAT was stopped and heparinization and all-transretinoic acid (ATRA) were started and continued until the end of September. From October 1995 she received 6-MP 100 mg daily *p.o.*, methotrexate every two weeks *i.v.* and ATRA fifteen days every three months, for two years. During this time, liver damage was minimal (AST=60; ALT=70; total bilirubin = 1.2 mg/dL) and platelet count not less than  $150 \times 10^9/L$ . The level of hypocoagulability was, at that time, measured every two weeks. The dose of acenocoumarol was increased progressively from 21 mg/week when she started cytotoxic treatment to 70 mg/week in June 1996, with a mean INR=1.9. From June 1996 to November 1997, the patient maintained a mean INR=3.4 with a mean dose of 71 mg/week (see Table 1). When 6-MP was stopped, the patient continued receiving 70 mg/week for a week. At the end of this week, her INR had increased from 3 to 12. The acenocoumarol was stopped and reintroduced 24 hours later at her habitual dose (3 mg/day) without hemorrhagic complications.

Although the interaction of azathioprine or 6-MP with acenocoumarol is not established, studies in rats indicate that 6-MP increases prothrombin synthesis or activation<sup>3</sup> and decreases warfarin activity.<sup>2,5</sup> An increase in warfarin requirements can be interpreted as a prothrombotic state in patients with disorders

requiring immunomodulatory therapy.<sup>5,6</sup> Our patient had a promyelocytic leukemia, known to cause a prothrombotic state. Our patient required a progressively increasing dose of acenocoumarol that she maintained during the remission period of the hematologic process; only when it finished, did she return to the normal requirements. In spite of the short life of acenocoumarol compared to warfarin, the increase of INR after stopping 6-MP was delayed, which suggests a metabolic interaction between 6-MP and OA, possibly induction of hepatic microenzymes activity, as seen with barbiturates.<sup>5</sup> According to the behavior of our patient, OA dosage (acenocoumarol or warfarin) should be reviewed no later than a week after ending azathioprine or 6-MP and the OA dose reduced to the amount before 6-MP treatment.

M<sup>a</sup> Angeles Fernández, Anabel Regadera, Justo Aznar

Unit of Anticoagulant Therapy. Department of Clinical Pathology, University Hospital "La Fe", Valencia, Spain

### Key words

Oral anticoagulants, 6-mercaptopurine, acenocoumarol

### Correspondence

M<sup>a</sup> Angeles Fernández, M.D., Unidad de Terapéutica Anticoagulante, Hospital Universitario "La Fe", Avda Campaner, 21, 46009 Valencia, Spain. Phone: international +34-963868795 – Fax: international +34-963868730 – E-mail: muro@san.gva.es

### References

- Hirsh J. Oral anticoagulant drugs. *N Eng J Med* 1991; 324:1865-75.
- Martindale J. The Extra Pharmacopeia. 31<sup>st</sup> ed. JEF Reynolds Ed, London, 1996.
- Martini A, Jähnchen E. Studies in rats on the mechanisms by which 6-mercaptopurine inhibits the anticoagulant effect of warfarin. *J Pharmacol Exp Ther* 1997; 201:547-53.
- Stockley IH. In: [anonymous]. Drug interactions. 4<sup>th</sup> ed. Pharmaceutical Press: London, 1997.
- Singleton JD, Conyers L. Warfarin and azathioprine: an important drug interaction. *Am J Med* 1992; 92: 217.
- Rivier G, Khamashta MA. Warfarin and azathioprine: a drug interaction does exist. *Am J Med* 1993; 95:342.

### Autologous peripheral blood stem cell transplantation in a patient with multiple sclerosis and concomitant Ph<sup>+</sup> acute leukemia

Sir,

Multiple sclerosis (MS) is a demyelinating disease of the central nervous system in which T-cell mediated immune destruction of myelin is thought to be pathogenetically relevant.

Immunomodulating and immunosuppressive agents

such as corticosteroids,  $\beta$ -interferon, azathioprine and cyclophosphamide are employed in the therapy of the disease. Their efficacy is not, however, optimal. Recently, high-dose chemotherapy with autologous stem cell reinfusion has been proposed as an experimental treatment. Being potentially hazardous, it has been restricted to a subset of patients with a progressive clinical course. Promising results have been reported by Fassas in patients with severe disability.<sup>1-5</sup>

We describe our experience with a 35-year old male affected by Philadelphia chromosome (Ph)-positive acute leukemia and relapsing-remitting MS. The coexistence of both diseases allowed us to evaluate the effects of immunoablation with high-dose chemotherapy in a patient with a relapsing-remitting form of MS, a disease subtype with a relatively favorable prognosis and, therefore, not eligible for aggressive therapeutic trials. The patient received a peripheral blood stem cell transplantation (PBSCT) after induction and consolidation chemotherapy including fludarabine and high dose of Ara-C.

The patient's neurological symptoms were first manifested in 1988 by left hemihypoesthesia which resolved spontaneously after a few weeks.

Two relapses occurred in 1989 and 1991, characterized respectively by left facial paresis and right optic neuritis, requiring treatment with 6-M-prednisolone 1 g/day for five days in each case. Brain magnetic resonance imaging (MRI) performed during the first relapse showed the presence of periventricular, hyperintense areas compatible with a demyelinating process.

Acute leukemia was diagnosed in November 1997. WBC count was  $46 \times 10^9/L$  with 66% of bone marrow blasts. Myeloperoxidase positivity was documented in 3% of bone marrow blast cells and flow cytometry showed HLA-DR, CD34, CD19, CD22, CD13, CD33, TdT positivity. Cytogenetic analysis revealed the presence of 50% Ph<sup>+</sup> metaphases with BCR/ABL rearrangement (p190/p210) at molecular level. No central nervous system (CNS) involvement was documented at diagnosis. The patient was treated with the FLAG schedule (fludarabine 30 mg/m<sup>2</sup> and Ara-C 2 g/m<sup>2</sup> D 1-5; G-CSF from day 1 until neutrophil recovery), achieving morphologic complete remission on day +28. The consolidation regimen consisted of fludarabine 30 mg/m<sup>2</sup>+ Ara-C 2 g/m<sup>2</sup> days 1-5, and mitoxantrone 6 mg/m<sup>2</sup> days 3-5, followed by G-CSF from day +15 in order to mobilize peripheral blood stem cells.

On day +18 from the start of consolidation, a single leukapheresis was performed, collecting  $24.8 \times 10^6/kg$  CD34<sup>+</sup> cells. Neither purging procedures nor positive selection of CD34<sup>+</sup> cells were utilized and PCR analysis performed at the time of collection still documented BCR/ABL rearrangement both in the marrow and in the apheresis product, while cytogenetics showed complete disappearance of the Ph-chromosome.

Subsequently the patient received high-dose hy-

droxyurea (4 g/m<sup>2</sup>/day) for 8 days, followed by a busulphan-cyclophosphamide conditioning regimen;  $12.4 \times 10^6/kg$  CD34<sup>+</sup> cells were reinfused and G-CSF was administered during the neutropenic period. Supportive therapy included phenobarbital as prophylaxis of busulphan-induced seizures and i.v. acyclovir 15 mg/kg/day to prevent Herpesvirus infections. The only infective complication during aplasia was a Staphylococcus sepsis responding to i.v. teicoplanin. No extra-hematologic toxicity was observed and engraftment was documented on day +9 both for neutrophils  $> 0.5 \times 10^9/L$  and platelets  $> 20 \times 10^9/L$ .

Three months after transplantation the patient was in complete hematologic remission with persistent evidence of BCR/ABL rearrangement at PCR; one month later leukemic relapse was documented by bone marrow biopsy.

Clinical and gadolinium-enhanced MRI follow-up of the neurological disease was performed pre- and post-induction therapy and pre- and post- autologous transplantation, showing no evidence of disease activity.

Our experience suggests that intensive immunosuppressive treatment followed by high-dose therapy and stem cell transplantation is feasible, with no risk of exacerbating neurotoxicity even in a patient with relapsing-remitting MS. As the "early timing" of stem cell autograft is critical in hematologic diseases for the success of the therapy, we suggest that "earlier" stem cell therapy in MS could be considered in the future.

Giovanna Meloni, Saveria Capria, Marco Salvetti\*, Iole Cordone, Marco Mancini, Franco Mandelli

Dipartimento di Biotecnologie Cellulari ed Ematologia;  
\*Dipartimento di Scienze Neurologiche;  
Università "La Sapienza", Rome, Italy

### Acknowledgments

Supported by ROMAIL (MPI 40%)

### Correspondence

Giovanna Meloni, MD, via Benevento 6, 00161 Rome, Italy.  
Phone: international +39-06-857951 — Fax: international +39-06-85795293 — E-mail: meloni@bce.med.uniroma1.it

### References

1. Marmont A, Van Békum DW. Stem cell transplantation for severe autoimmune diseases: new proposals but still unanswered questions. *Bone Marrow Transplant* 1995; 16:497-8.
2. Fassas A, Agnastopulos A, Kazis A, et al. Peripheral blood stem cell transplantation in the treatment of progressive multiple sclerosis: first results of a pilot study. *Bone Marrow Transplant* 1997; 20:631-8.
3. Burt RK, Burns WH, Miller SD. Bone marrow transplantation for multiple sclerosis: returning to Pandora's box. *Immunol Today* 1997; 18:559-61.
4. Tyndall A, Gratwohl A. Hemopoietic blood and mar-

- row transplants in the treatment of severe autoimmune disease. *Curr Opin Hematol* 1997; 4:390-4.
5. Marmont AM. Stem cell transplantation for severe autoimmune diseases: progress and problems. *Haematologica* 1998; 83:733-43.

### Life threatening lung toxicity induced by low doses of bleomycin in a patient with Hodgkin's disease

Sir,

Bleomycin is a polypeptide antibiotic isolated from *Streptomyces verticillus*. Its activity against a variety of tumors, particularly squamous cell carcinoma of various origins, lymphomas and germ cell tumors has been demonstrated for over 20 years.<sup>1</sup> Possible toxicities include dermatitis, mucositis, alopecia, fever, as well as pulmonary toxicity (PT). Approximately 1% to 2% of patients develop fatal PT, and an additional 5% to 10% develop non fatal PT.<sup>2-4</sup> Several risk factors have been described, such as cumulative dose, the presence of renal impairment, prior pulmonary function abnormalities, adjunctive thoracic radiotherapy, high dose oxygen therapy, and age above 70.<sup>1,4</sup> Total dose is clearly a risk factor. The incidence of fatal PT increases with a total dose higher than 400 U.<sup>1,4,5</sup> In contrast, sporadic cases have been reported of bleomycin PT with total doses lower than 100 U.<sup>6</sup> The pathogenesis of bleomycin PT remains unknown.

We report the case of a patient who developed severe bleomycin induced PT after a very low dose of bleomycin. The patient, a 63-year old man, was treated with COPP/ABV hybrid regimen for stage 1A (left axillary lymph nodes) Hodgkin's disease, nodular sclerosis. His past medical history included esophageal replacement by a colon transposition after a caustic esophageal burn, and he smoked half a pack of cigarettes a day. The patient denied any history of allergy. Seven days after the second cycle of COPP/ABV with a cumulative dose of 34 U of bleomycin he required hospital admission because of fever, breathlessness and a dry cough. Physical examination revealed a temperature of 37.8°C, a respiratory rate of 20 breaths per minute and crepitations at both lung bases. The WBC count was 3,200 cells/mL with 1,920 neutrophils. The hemoglobin value was 10.4 gr/dL, and the platelet count was 248,000 cells/mL. With the patient breathing air, the arterial blood gas determination showed a PaO<sub>2</sub> of 49 mmHg, PaCO<sub>2</sub> of 34 mmHg, pH of 7.48 and a saturation level of 87%. Electrolyte levels, liver tests, and coagulation studies were within normal limits. The admission chest radiograph demonstrated bilateral basal diffuse interstitial infiltrates. CT scan of the chest revealed a decrease in the size of the axillary lymph nodes. Bronchoscopy was negative for infection. The patient started treatment with empiric antibiotics for presumed infection and inspired oxy-

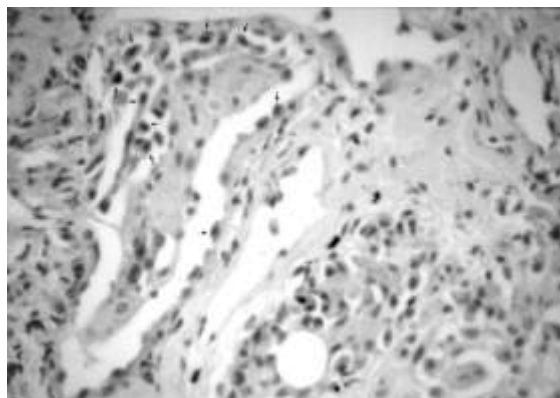


Figure 1. Light microscopy of lung biopsy showing alveolar spaces and atypical pneumocytes with large and hyperchromatic nucleus (arrows).

gen concentrations of 35-40%. Despite this treatment, his respiratory function deteriorated rapidly and he was transferred to the intensive care unit for intubation and ventilation. Chest radiography showed extensive alveolar and interstitial shadowing of both lungs. After admission to the intensive care unit, pulmonary function continued to deteriorate throughout this time. A transbronchial biopsy was done and the biopsy specimen showed a large number of atypical pneumocytes (type II cells) with big and hyperchromatic nucleus. No eosinophilic infiltration was observed (Figure 1). Antibiotic therapy was stopped, and prednisone 1 mg/kg/day was started. There was a marked improvement in his pulmonary function and chest radiographs revealed gradual clearing over a 7-day period. One month after starting corticosteroid therapy chest radiography showed almost complete resolution of the infiltrates. The corticosteroids were completely withdrawn after the clear chest radiograph. Three cycles of COPP regimen have been administered, and the patient is now free of disease and asymptomatic.

This patient had an unusual life threatening bleomycin PT after a very low cumulative dose (34U). Only three cases of severe PT induced by bleomycin at doses lower than 40U have been reported.<sup>7-9</sup> Moreover, our patient had none of the well established risk factors for fatal bleomycin induced PT. The exclusion of infection and the pathology results all pointed to a diagnosis of acute or subacute bleomycin-induced interstitial pneumonitis. In addition, a rapid response was observed to prednisone treatment. The low cumulative dose, the absence of risk factors and the prompt corticosteroid response suggest a hypersensitivity response. Sporadic cases of bleomycin hypersensitivity pneumonitis have been reported.<sup>10</sup> Although radiologic and functional pulmonary changes were similar to the usual bleomycin interstitial pneumonitis, lung biopsies showed a pattern of hypersensitivity reaction. Biopsy specimens from the reported cases of hypersensitivity pneumonitis all showed similar characteris-