Teclistamab in relapsed/refractory Waldenström macroglobulinemia

Waldenström macroglobulinemia (WM) is a rare indolent B lymphoma with an annual incidence of 3-4 cases per million.[1] The disease is characterized by bone marrow (BM) infiltration by malignant cells with lymphoplasmacytic differentiation, a detectable serum monoclonal IgM immunoglobulin (mIgM), and the recurrent MYD88 L265P somatic mutation in the majority of cases (>90%).[2] Time-limited rituximab-based chemoimmunotherapy, such as bendamustine/rituximab, and continuous therapy with covalent Bruton tyrosine kinase inhibitors (BTKi) (ibrutinib, zanubrutinib) are key treatment options in the management of WM.[3] While current therapies provide high overall response rates with durable control, complete remissions (CR) with eradication of clonal cells remain difficult to achieve, and the disease is still considered incurable.[3] Relapsed disease, particularly after BTKi failure, is a therapeutic challenge and is associated with an adverse prognosis.[4]

Bispecific antibodies (bsAb) redirect T cells toward malignant cells by simultaneous binding of a tumor-associated antigen and CD3 on T cells. They are highly active agents in relapsed or refractory multiple myeloma (targeting BCMA, GPRC5D) and B cell lymphomas (CD20).[5] Recent data suggest that anti-BCMA bsAb effectively eliminate both tumor and normal plasma cells (PC) as well as B cells.[6] Thus, we hypothesized that teclistamab, a BCMA targeted bsAb, might be a novel and effective treatment approach in WM. Here we present, what is to our knowledge, the first case report of a relapsed/refractory WM patient successfully treated with an anti-BCMA bsAb. This case report was conducted in accordance with the principles of the Declaration of Helsinki. Written informed consent was obtained from the patient, and all samples were processed according to standard operating procedures approved by the Institutional Ethics Committee under approval number 413/2012.

A 56-year-old non-Hispanic White male with otherwise unremarkable medical history was diagnosed with symptomatic WM in 2014, preceded by IgM kappa monoclonal gammopathy of undetermined significance (MGUS) by nine years earlier. At diagnosis, BM infiltration was 70% lymphoplasmacytic lymphoma. Next-generation sequencing (NGS) on CD19-sorted BM cells identified MYD88 L265P and a CXCR4 C-terminal truncating frameshift mutation (p.T318Nfs*26). Disease was low risk by International Prognostic Scoring System for WM (IPSSWM) and intermediate risk according to the modified staging system (MSS-WM). In 2023, WM progression was accompanied by the development of hepatosplenomegaly. The diagnosis was subsequently reconfirmed by BM evaluation in 2018, 2023, and 2025.

Prior to teclistamab, the patient had received seven lines of therapy: rituximab, cyclophosphamide, dexamethasone (2014); achieving stable disease (SD) with rituximab, cyclophosphamide, doxorubicin, vincristine, prednisone (2014); achieving partial remission (PR) with bendamustine, rituximab (2018); bortezomib, dexamethasone, rituximab (2023; SD followed by extramedullary progressive disease [PD]); ibrutinib (2023-2024; 6 months, SD); zanubrutinib (2024-2025; 12 months); achieving a minimal response (MR) followed by extramedullary PD; venetoclax (2025; ramp-up to 800 mg/day, 5 months) achieving SD as the best response followed by PD. Two stem cell collections yielded suboptimal $CD34^+$ counts ($2.6x10^6$ and $1.8x10^6$ cells/kg) and the products were not released due to failed quality-control parameters. Mobilization failure was attributed to extensive prior cytotoxic therapy and late collection.

By October 2025, venetoclax was considered ineffective because of worsening edema, ascites, hepatosplenomegaly and absent hematologic response. The liver and spleen measured 23.2 cm and 16.8 cm in the midclavicular line, respectively. Liver or spleen biopsy was not performed. Concomitant AL amyloidosis was not demonstrated on abdominal fat pad biopsy. BM aspirate analyzed by flow cytometry, performed according to EuroFlow protocols, demonstrated 0.15% PC (100% clonal) with $CD19^+$ $CD38^+$ $CD45^+$ $CD138^+$ cytKappa$^+$ immunophenotype and 0.1% B lymphocytes (100% clonal) with a $CD5^-$, $CD11c^-$, $CD19^+$, $CD20^+$, $CD22^+$, $CD25^{low}$, $CD27^+$, $CD38^{low}$, $CD79b^+$, $CD81^+$, $CD305^-$, $sIgM^+$, cytKAPPA$^+$ immunophenotype. The trephine biopsy was not performed. Fluorescence *in situ* hybridization was negative for del(17p), and *TP53* mutation was not detected by NGS. Spectral cytometry was also performed for detailed lymphoid cell and PC phenotyping with use of anti-BCMA/PE conjugate,[7] detecting 0.1% PC, 90% of which were BCMA-positive. No considerable BCMA expression was detected on mature B cells.

Teclistamab monotherapy was initiated in December 2025 after off-label reimbursement approval based on highly refractory symptomatic WM, absence of standard alternatives, and the biological rationale for BCMA targeting. At treatment initiation, laboratory workup showed anemia (Hb 112 g/L; reference range 135-175 g/L), elevated β2-microglobulin (6.67 mg/L; reference range 0.8-2.34 mg/L), IgM 25 g/L (reference range 0.4-2.3 g/L), m-IgM 13.5 g/L, free light chain (FLC) kappa 357 mg/L (reference range 3.3-19.4 mg/L), and FLC ratio 87, with suppressed IgG 4.4 g/L (reference range 7-16 g/L) and IgA <0.22 g/L (reference range 0.88-4.1 g/L); albumin, LDH, and CRP were within normal range, and soluble BCMA was 102.9 μg/L. Teclistamab was

administered subcutaneously according to the standard step-up schedule: 0.06 mg/kg, 0.3 mg/kg, then 1.5 mg/kg weekly. As per local institutional protocol, tocilizumab 8 mg/kg was given before the first step-up dose to reduce the risk and severity of cytokine release syndrome (CRS). No CRS or neurotoxicity occurred. Grade 3 neutropenia developed on day 8 and resolved after one dose of granulocyte colony-stimulating factor. From day 12, the patient developed renal impairment (peak creatinine 164 μmol/L; reference range 60-105 umol/L, GFR 0.66mL/s; reference range 1-2.35 mL/s) of unclear etiology despite comprehensive workup, without oliguria, proteinuria, hematuria, obstruction, infection, thrombotic microangiopathy, or metabolic disturbance. Renal function stabilized after cycle 2 and normalized by cycle 4 without intervention. Immunoglobulin replacement, Pneumocystis prophylaxis, and varicella-zoster prophylaxis were administered. No infectious complications have occurred during follow-up to date.

For response assessment, 11th International Workshop on Waldenstrom's macroglobulinemia response criteria were used. A rapid hematologic response was observed: PR after cycle 1, very good partial response after cycle 2, and CR after cycle 4, maintained through cycle 5, with early normalization of free light chains (FLC) (Figures 1, 2C). Flow cytometry of the BM aspirate after the third cycle showed complete eradication of clonal PC and clonal B cells (Figure 2A). A radiologic response was also documented, with partial regression of hepatomegaly and resolution of splenomegaly; liver and spleen diameters decreased to 19.0 cm and 11.5 cm, respectively (Figure 2B). The patient also experienced rapid clinical improvement during cycle 1, with disappearance of lower-extremity edema and subsequent regression of ascites. At five months, the hematologic CR and clinical benefit were ongoing, with a CR duration of four weeks at the time of manuscript submission. Teclistamab is planned for 12 months, with interval extension to every two weeks from month 6 and every four weeks from month 9 if disease control and tolerability persist.

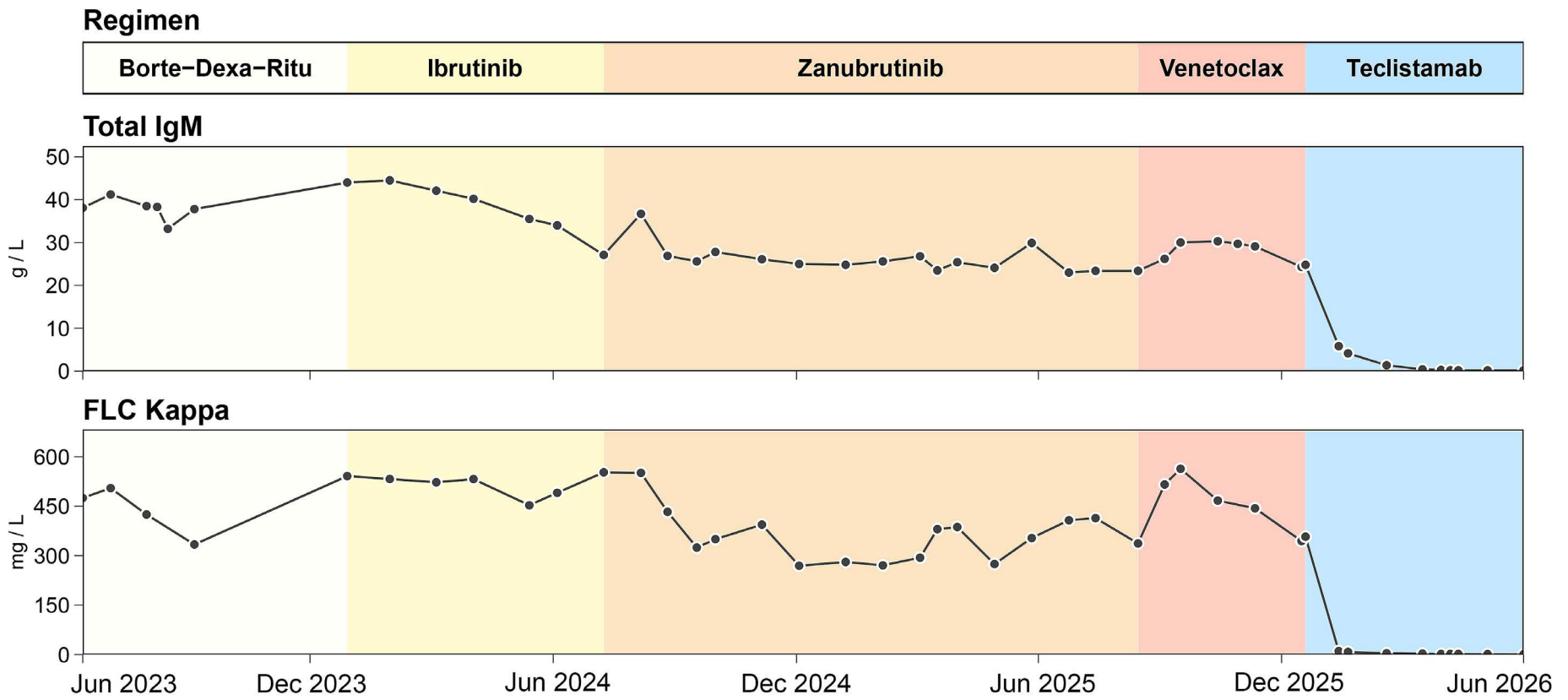

Figure 1. Longitudinal monitoring of serum total IgM. Longitudinal monitoring of serum total IgM involved free light chain (FLC) kappa concentrations during treatment course. Borte-Dexa-Ritu: bortezomib-dexamethasone-rituximab; CT: computed tomography; Hb: hemoglobin; HSM: hepatosplenomegaly; TCP: thrombocytopenia.

Malignant cells in WM most likely originate from an IgM+ memory B cell with partial plasma-cell differentiation into a lymphoplasmacytic/PC clone that secretes IgM.[8] Flow cytometry studies in WM have clearly demonstrated the co-existence of clonal B cells and an identical light-chain-isotype clonal PC population with an immunophenotypic profile resembling normal PC rather than myeloma PC.[9] This biological overlap supports the investigation of B-cell and PC-associated targets as potential therapeutic strategies in WM. Daratumumab monotherapy produced suboptimal activity in WM, with an overall response rate of 23% and median progression-free survival of two months, underscoring the need for alternative targets and strategies.[10] Direct data on BCMA expression in WM are limited; however, broader analyses suggest BCMA expression in subsets of non-Hodgkin lymphomas, including WM, generally at lower levels than in multiple myeloma.[11] Elsawa *et al*. found BCMA expression by flow cytometry in 8/12 (67%) WM patients, with mostly low and occasional intermediate expression.[12]

There are conflicting reports on BCMA expression on precursor, naïve, and memory B cells.[13] Despite limited expression of BCMA on B cells by flow cytometry, anti-BCMA bsAb are able to effectively target and eliminate all B cell subsets from the small pre B stage onward. Single cell RNA sequencing demonstrated low but detectable BCMA mRNA expression across mature B cells and B cell precursors, including immature B cells and both small and large pre B cells, with the highest expression observed in the small pre B subset.[6]

Bispecific antibodies are among the most active agents currently available for relapsed or refractory multiple myeloma and B-cell lymphomas, producing high response rates even in heavily pretreated patients.[5] Off-label use of teclistamab has recently been reported in 3 patients with refractory BCMA-positive plasmablastic lymphoma.[14] Evidence of bsAB activity in WM is very limited. A 2022 case

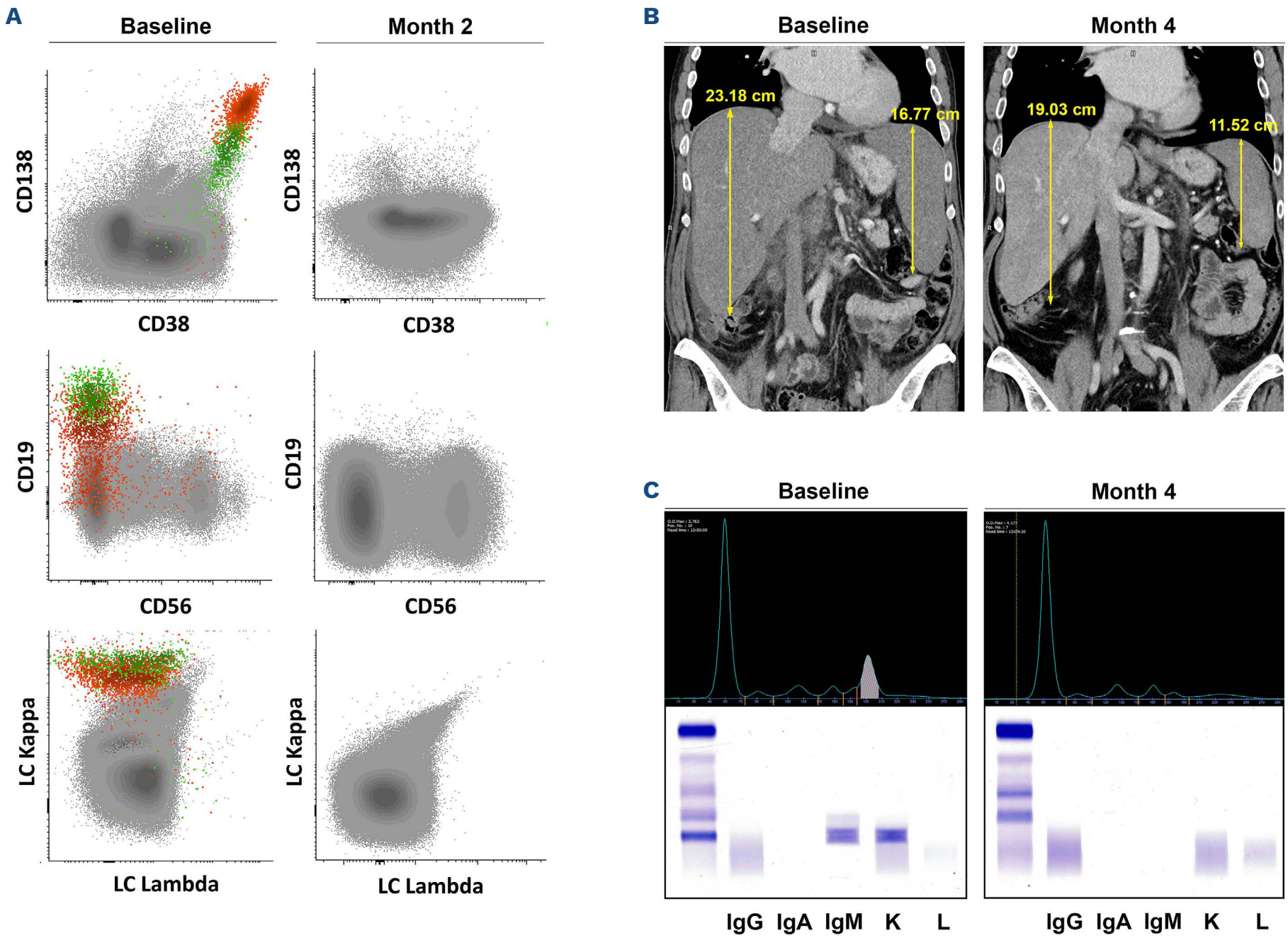

Figure 2. Multimodal assessment of response to teclistamab therapy. (A) Flow cytometry of the bone marrow aspirate before teclistamab administration and after three months of therapy, showing complete eradication of both clonal plasma cells and B cells. (B) Computed tomography demonstrating hepatosplenomegaly before teclistamab initiation and partial regression of hepatomegaly and normalization of spleen size at month 4 of therapy. (C) Serum protein electrophoresis and immunofixation at baseline and at month 4 of therapy.

report described plamotamab, a CD20xCD3 bsAb, in ibrutinib-refractory, CXCR4-mutated extramedullary WM, inducing minor hematologic response and near-complete extramedullary disease resolution before relapse with CD20-negative disease.[15] A phase II trial of epcoritamab (CD20xCD3) in previously treated WM (clinicaltrials.gov identifier: NCT06510491) is currently recruiting; however, no preliminary results have been reported to date. Etentamig (ABBV-383), a BCMAxCD3 bsAB, is being evaluated in a phase I/II trial for RRWM (clinicaltrials.gov identifier: NCT07420959), led by the Mayo Clinic.

In this heavily pretreated relapsed/refractory WM patient, teclistamab monotherapy led to a rapid and deep hematologic response with complete eradication of clonal PC and B cells in the BM. The patient had received multiple prior lines of therapy, including standard chemoimmunotherapy, a proteasome inhibitor, first and second generation BTKi, and venetoclax administered over several years, none of which induced a major response. In contrast, teclistamab proved to be highly effective and very well tolerated with no serious adverse events. Although limited to a single-patient observation, this case provides initial clinical evidence supporting BCMA-directed bsAb as a promising therapeutic approach in WM by targeting both malignant plasma cells and B cells.

Authors

Michal Kascak,[1,2]* Ludmila Muronova,[1,2]* Ondrej Venglar,[1,2] Gabriela Kascakova,[3] Eva Radova,[1,2] Lucie Broskevicova,[1,2] Tereza Popkova,[1,2] Katerina Karasova,[1,2] Tereza Novakova,[1,2] Jana Mihalyova,[1,2] Juraj Duras,[1,2] Pavlina Kusnierova,[4,5] Martin Havel,[3] Tereza Sevcikova,[1,6] David Zihala,[1,2,6] Roman Hajek[1,2] and Tomas Jelinek[1,2]

[1]Department of Hematooncology, University Hospital Ostrava; [2]Department of Hematooncology, Faculty of Medicine, University of Ostrava; [3]Department of Nuclear Medicine, University Hospital Ostrava; [4]Institute of Laboratory Medicine, Faculty of Medicine, University of Ostrava; [5]Institute of Laboratory Medicine, Department of Clinical Biochemistry, University Hospital Ostrava and [6]Department of Biology and Ecology, Faculty of Science, University of Ostrava, Ostrava, Czech Republic

**MK and LM contributed equally as first authors.*

Correspondence:
T. JELINEK - tomas.jelinek@fno.cz

https://doi.org/10.3324/haematol.2026.301159

Received: April 28, 2026.
Accepted: July 3, 2026.
Early view: July 16, 2026.

Published under a CC BY license

Disclosures

MK has received honoraria for participation in advisory boards and satellite symposia from Gilead, Takeda, BMS, Roche, Swixx, and AstraZeneca. JM has received conference sponsorship from Abbvie and Johnson&Johnson; and honoraria for advisory boards from Gilead, Abbvie, AstraZeneca, and Johnson&Johnson. TP has received honoraria from Johnson&Johnson, Pfizer, and Sanofi. JD has received honoraria from Abbvie, and Roche; and reports consulting or an advisory role for Abbvie, Bristol Myers Squibb, Eli Lilly, Johnson&Johnson, Roche, Swixx, and Takeda. RH reports grants or contracts from Amgen, BMS, Celgene, Janssen, Novartis, and Takeda; consulting fees from AbbVie, Amgen, BMS, Celgene, Janssen, Novartis, PharmaMar, and Takeda; honoraria for lectures, presentations, and speaker bureaus from Amgen, BMS, Celgene, Janssen, PharmaMar, and Takeda; support for attending meetings and/or travel from Amgen, Celgene, Janssen, and Takeda; and participation on a data safety monitoring board or advisory board for Amgen, BMS, GSK, Janssen, Oncopeptides, Sanofi, and Takeda. TJ has received research funding from Johnson&Johnson and Sanofi; and honoraria and consultancy/advisory role for Bristol Myers Squibb, GlaxoSmithKline, Johnson&Johnson, Pfizer, and Sanofi. All the other authors have no conflicts of interest to disclose.

Contributions

MK and LM are responsible for study concept and data curation, and wrote the original draft of the manuscript. OV performed the flow cytometric analysis, curated the data, and created the figures. GK and MH are responsible for assessment of the imaging studies. PK is responsible for biochemical analyses. TJ is responsible for study concept and data curation. All the authors reviewed and edited the final version of the manuscript for publication.

Funding

This work was supported by OPJAK SALVAGE project (No. CZ.02.01.01/00/22_008/0004644) with co-financing from EU and the State Budget; by the European Union project LERCO (No. CZ.10.03.01/00/22_003/0000003); by the Czech Health Research Council (NU23-03-00374); by Institutional support (MH CZ— DRO—FNOs/2022, MH CZ—DRO— FNOs/2023, MH CZ—DRO—FNOs/2024); by the Ministry of Education, Youth and Sports of the Czech Republic through the e-INFRA CZ (ID:90254). TJ was supported by an EHA Physician Scientist Research Grant RG-202409-06772.

Data-sharing statement

The data that support the findings of this case report are available on request from the corresponding author.

References

1. McMaster ML. The epidemiology of Waldenström macroglobulinemia. Semin Hematol. 2023;60(2):65-72.
2. Alaggio R, Amador C, Anagnostopoulos I, et al. The 5th edition of the World Health Organization classification of haematolymphoid tumours: lymphoid neoplasms. Leukemia. 2022;36(7):1720-1748.
3. Gertz MA. Waldenström macroglobulinemia: 2025 update on diagnosis, risk stratification, and management. Am J Hematol. 2025;100(6):1061-1073.
4. Frustaci AM, Zappaterra A, Galitzia A, et al. Salvage treatment after covalent BTKi failure: an unmet need in clinical practice in Waldenström macroglobulinemia. Hemasphere. 2025;9(2):e70094.
5. Braun A, Gouni S, Pulles A, Strati P, Minnema MC, Budde LE. Bispecific antibody use in patients with lymphoma and multiple myeloma. Am Soc Clin Oncol Educ Book. 2024;44(3):e433516.
6. Jelinek T, Zihala D, Zabaleta A, et al. Selective B-cell subset depletion underlies increased infection risk in patients with MM treated with anti-BCMA vs anti-GPRC5D bsAbs. Blood. 2026;147(10):1070-1082.
7. Venglar O, Radova E, Broskevicova L, Hajek R, Jelinek T. OMIP-117: 40-parameter/37-color spectral cytometry panel for robust immunoprofiling of human lymphoid subsets in cancer patients. Cytometry A. 2025;107(10):641-648.
8. García-Sanz R, Jiménez C, Puig N, et al. Origin of Waldenström's macroglobulinaemia. Best Pract Res Clin Haematol. 2016;29(2):136-147.
9. Jelinek T, Bezdekova R, Zatopkova M, et al. Current applications of multiparameter flow cytometry in plasma cell disorders. Blood Cancer J. 2017;7(10):e617.
10. Castillo JJ, Libby EN, Ansell SM, et al. Multicenter phase 2 study of daratumumab monotherapy in patients with previously treated Waldenström macroglobulinemia. Blood Adv. 2020;4(20):5089-5092.
11. Dogan A, Siegel D, Tran N, et al. B-cell maturation antigen expression across hematologic cancers: a systematic literature review. Blood Cancer J. 2020;10(6):73.
12. Elsawa SF, Novak AJ, Grote DM, et al. B-lymphocyte stimulator (BLyS) stimulates immunoglobulin production and malignant B-cell growth in Waldenström macroglobulinemia. Blood. 2006;107(7):2882-2888.
13. Carpenter RO, Evbuomwan MO, Pittaluga S, et al. B-cell maturation antigen is a promising target for the immunotherapy of multiple myeloma. Clin Cancer Res. 2013;19(8):2048-2060.
14. Cannova JM, DuVall AS, Kline J, Feinberg N, Wool GD, Riedell PA. Targeting BCMA in plasmablastic lymphoma with teclistamab: a case study of three patients. J Natl Compr Canc Netw. 2026;24(3):128-131.
15. Parrondo RD, Paulus A, Alegria V, et al. Plamotamab (XmAb 13676) for ibrutinib-refractory CXCR4-mutated extramedullary Waldenström macroglobulinemia. Leuk Lymphoma. 2022;63(3):738-742.