Emapalumab and eltrombopag rescue for prolonged immune effector cell-associated hemophagocytic syndrome after CAR T-cell therapy in multiple myeloma

Chimeric antigen receptor (CAR) T-cell therapy and bispecific antibodies (BsAb) have demonstrated efficacy in relapsed/refractory multiple myeloma.[1] While cytokine release syndrome (CRS), immune effector cell (IEC)-associated neurotoxicity syndrome (ICANS), and prolonged cytopenias are well-recognized toxicities, IEC-hemophagocytic lymphohistiocytic syndrome (IEC-HS) is an emerging complication that lacks standardized management.[2] Treatment of hemophagocytic lymphohistiocytosis, a hyperinflammatory syndrome driven by uncontrolled macrophage and T-cell activation, now includes anakinra, ruxolitinib, and emapalumab (anti-interferon [IFN]γ monoclonal antibody),[3] yet the optimal approach to IEC-HS is undetermined.

We present the case of a patient with high-risk relapsed/refractory multiple myeloma who progressed to plasma cell leukemia (PCL) with hypereosinophilic syndrome after BsAb therapy and developed prolonged IEC-HS following CAR T-cell infusion. We detail three phases of the management of this case: pre-emptive inflammatory control, early CRS mitigation, and treatment of refractory IEC-HS. We demonstrate how chemokine C-X-C motif ligand 9 (CXCL9)-guided emapalumab treatment combined with eltrombopag achieved transfusion independence while preserving a deep anti-myeloma response. Elevated levels of CXCL9, a biomarker of systemic IFNγ activity, identified persistent IFNγ-driven marrow inflammation, providing a rationale for IFNγ blockade.[4] This study was approved by the Mount Sinai institutional review board (GCO#: 11-01978).

A 75-year-old male with International Staging System stage II IgG-λ relapsed/refractory multiple myeloma and high-risk cytogenetics (+1q21, −1p32, t(14;16)) progressed through five lines of therapy over 7 months. Three cycles of talquetamab (a BsAb targeting G protein-coupled receptor class C group 5 member D [GPRC5D]) induced a complete response with measurable residual disease at 0.0016% by next-generation sequencing, permitting stem-cell collection and leukapheresis for ciltacabtagene autoleucel (ciltacel) manufacturing. Talquetamab was paused as ferritin exceeded 2,000 ng/mL, which predicts adverse outcomes after CAR T-cell therapy.[5]

After 3 months off talquetamab, the patient's myeloma rapidly progressed to PCL, refractory to talquetamab re-initiation, with intractable diarrhea and marked hypereosinophilia. Eosinophils accounted for 92.4% of peripheral leukocytes (absolute count, $23.5\times10^3/\mu L$) and 64% of bone marrow cells (Figure 1A). Work-up excluded infections, autoimmune diseases, HLA-B*58:01, and myeloproliferative neoplasms, including those associated with *PDGFRA/PDGFRB* aberrations. Positive findings included serum IgE 405 kU/L (normal: 0-214 kU/L) and *KRAS* p.A146V mutation. Administration of prednisone 1 mg/kg daily for 4 days resolved both the diarrhea and eosinophilia.

Immunohistochemistry and single-cell RNA sequencing confirmed the absence of GPRC5D protein and RNA expression (Figure 1B, C). Peripheral flow cytometry revealed γδ T-cell expansion (16% of lymphocytes). Given the rapidly progressive PCL and hypereosinophilia, direct CAR T-cell infusion carried an unacceptable risk of fatal CRS, ICANS, and movement and neurocognitive treatment-emergent adverse events (MNT). Therefore, the patient was given carmustine 100 mg/m² and melphalan 100 mg/m² followed by a stem cell boost (3.17×10^6 $CD34^+$ cells/kg), for rapid debulking, achieving a very good partial response.

Ferritin levels remained >2,000 ng/mL, prompting 2 weeks of prednisone treatment before lymphodepletion. Subcutaneous anakinra 200 mg every 8 hours was started prophylactically on day 2 after the cilta-cel infusion for 2 weeks, then continued daily for 285 days. The patient developed grade 1 CRS, with no ICANS or MNT, and received tocilizumab. Cytokine profiling revealed interleukin (IL)-1β peaking at 21.5 pg/mL (normal: <1.2 pg/mL), IL-2Rα at 11,375 pg/mL (normal: 223-710 pg/mL), IL-6 at 4,747 pg/mL (normal: <5 pg/mL), IFNγ at 89.6 pg/mL (normal: <8.6 pg/mL), and tumor necrosis factor (TNF)α at 63.4 pg/mL (normal: <2.2 pg/mL) (Figure 1D). IL-1β, IL-6, and IFNγ levels peaked within the first 1-2 weeks and declined thereafter, consistent with early attenuation by anakinra and tocilizumab; TNFα and IL-2Rα continued to rise, peaking around day 24 and remaining elevated through day 57.

Cytopenias were observed after cilta-cel infusion, but rather than recovering with expected post-lymphodepletion kinetics, they deepened and became refractory and the patient was transfusion-dependent, coinciding with a ferritin rise to ~33,000 ng/mL around day 20 (Figure 2). Cytokine measurements were more consistent with ongoing macrophage activation than resolving CRS (Figure 1D). Over 6 months, the patient required >70 red-cell/platelet transfusions and received weekly granulocyte colony-stimulating factor. Serial assessment of the IFNγ pathway during this prolonged cytopenic phase was unavailable. Soluble CXCL9 was first measured on day 247 for suspected IEC-HS and consideration of IFNγ-directed therapy.

The patient met the 2004 criteria for hemophagocytic lymphohistiocytosis:[6] fever >38.5°C, hypertriglyceridemia,

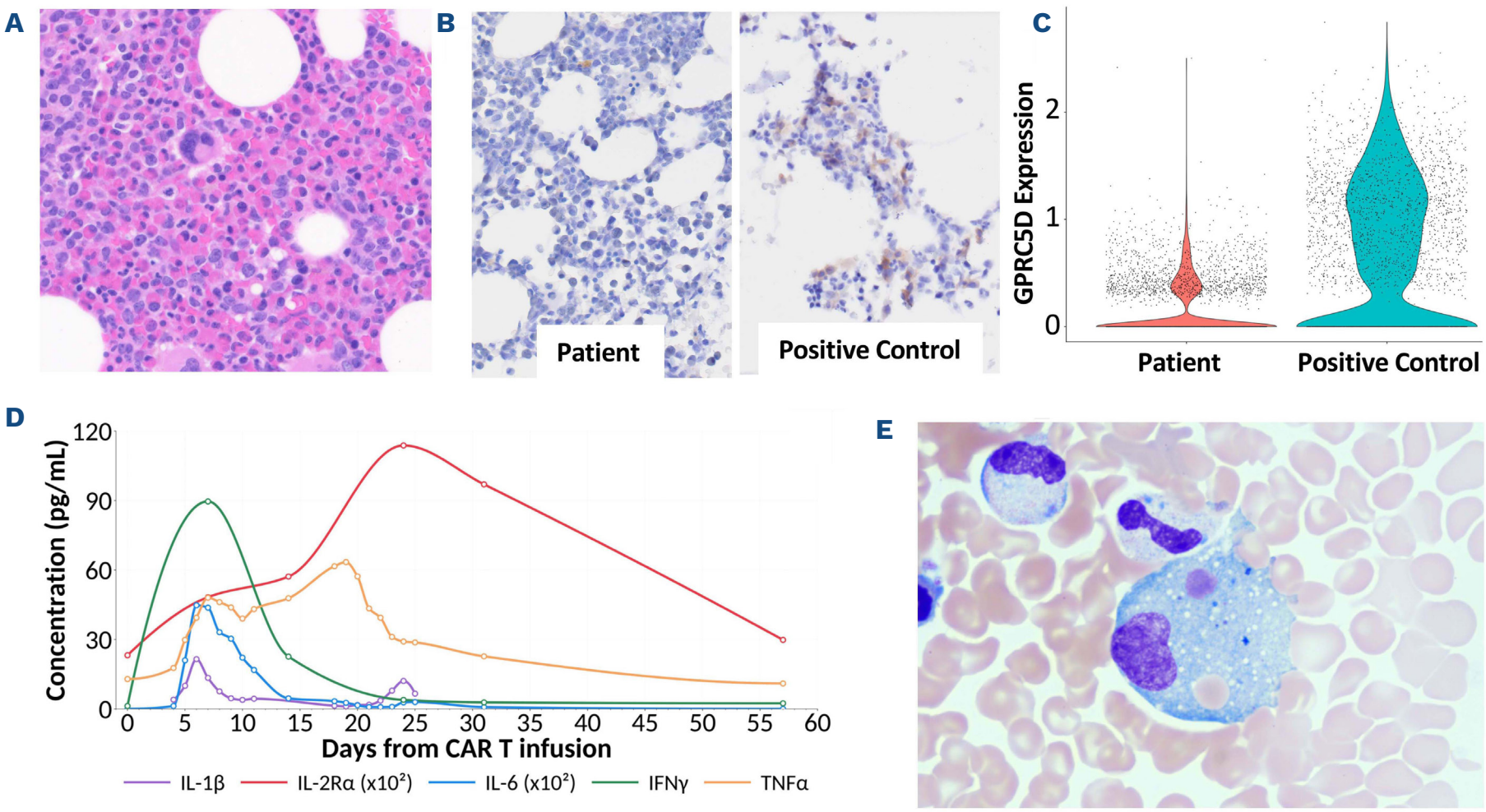

Figure 1. Multimodal characterization of an aggressive plasma cell leukemia trajectory and subsequent immune effector cell hemophagocytic lymphohistiocytic syndrome. (A) Hematoxylin & eosin-stained bone marrow aspirate and biopsy demonstrating marked hypereosinophilia during rapid disease progression, with eosinophils comprising the majority of nucleated cells. (B) Immunohistochemistry of the patient's bone marrow at the time of progression after talquetamab treatment showing absence of GPRC5D compared to a positive control. (A, B)Original magnification, 40X. (C) Single-cell RNA sequencing of the plasma cell compartment, showing loss of GPRC5D RNA expression compared to a positive control. (D) Longitudinal cytokine measurements after ciltacabtagene autoleucel illustrating elevations in the levels of IL-1β, IL-2Rα, IL-6, IFNγ, and TNFα. (E) Oil Wright Giemsa–stained bone marrow aspirate smear at 3 months after ciltacabtagene autoleucel treatment with macrophages showing evidence of hemophagocytosis. Original magnification, 100X. CAR: chimeric antigen receptor; GPRC5D: G protein-coupled receptor class C group 5 member D; IL-1β: interleukin 1 beta; IL-2Rα,: interleukin 2 receptor alpha; IL-6: interleukin 6; IFNγ: interferon gamma; TNFα; tumor necrosis factor alpha.

hypofibrinogenemia, transaminitis, cytopenias, hyperferritinemia, elevated soluble CD25/IL-2Rα, and hemophagocytosis on bone marrow smpled at day 100 (Figure 1E). However, soluble CD25/IL-2Rα was not measured prior to the CAR T-cell infusion. The patient also fulfilled IEC-HS-specific criteria:[2] hyperferritinemia, refractory cytopenias, transaminitis, lactate dehydrogenase elevation, hypertriglyceridemia, and bone marrow hemophagocytosis; the fibrinogen nadir (161 mg/dL) was just above the <150 mg/dL threshold. Critically, the marrow was cellular with active but ineffective hematopoiesis amidst hemophagocytosis, so additional stem cell infusion was deferred. Analysis of T-cell receptor β/γ gene rearrangements did not reveal any clonal T-cell populations, arguing against a diagnosis of T-cell large granular lymphocytic leukemia, so high-dose intravenous immunoglobulin was not administered. Throughout this period of toxicity, measurable residual disease by next-generation sequencing remained negative.

Prednisone and anakinra yielded modest improvements of platelet counts after addition of eltrombopag (150 mg daily). A brief transition from anakinra to ruxolitinib showed no benefit (Figure 2). Given the elevated CXCL9 level (2,735 pg/mL), measured by the ELLA platform (Cincinnati Children's Hospital), emapalumab was initiated on day 255 with twice-weekly step-up dosing (1, 3, 6, and 10 mg/kg), followed by a single 10 mg/kg dose 1 week later, then 10 mg/kg every 2 weeks for four additional doses (a total of 9 doses). The response was dramatic: IFNγ became undetectable within 1 week, CXCL9 normalized within 3 weeks, and the patient transited from heavy transfusion dependence to complete independence, with decreased granulocyte colony-stimulating factor requirements.

Infectious complications were modest while on emapalumab: self-limited *E. coli* enterocolitis and mild cytomegalovirus viremia (peak viral load 384 IU/mL) that resolved with 30 days of administration of valganciclovir.

At 2 years after cilta-cel, the patient remains in stringent complete response and is negative for measurable residual disease. He has no circulating B cells and remains immunocompromised; however, his $CD4^+$ T-cell count normalized

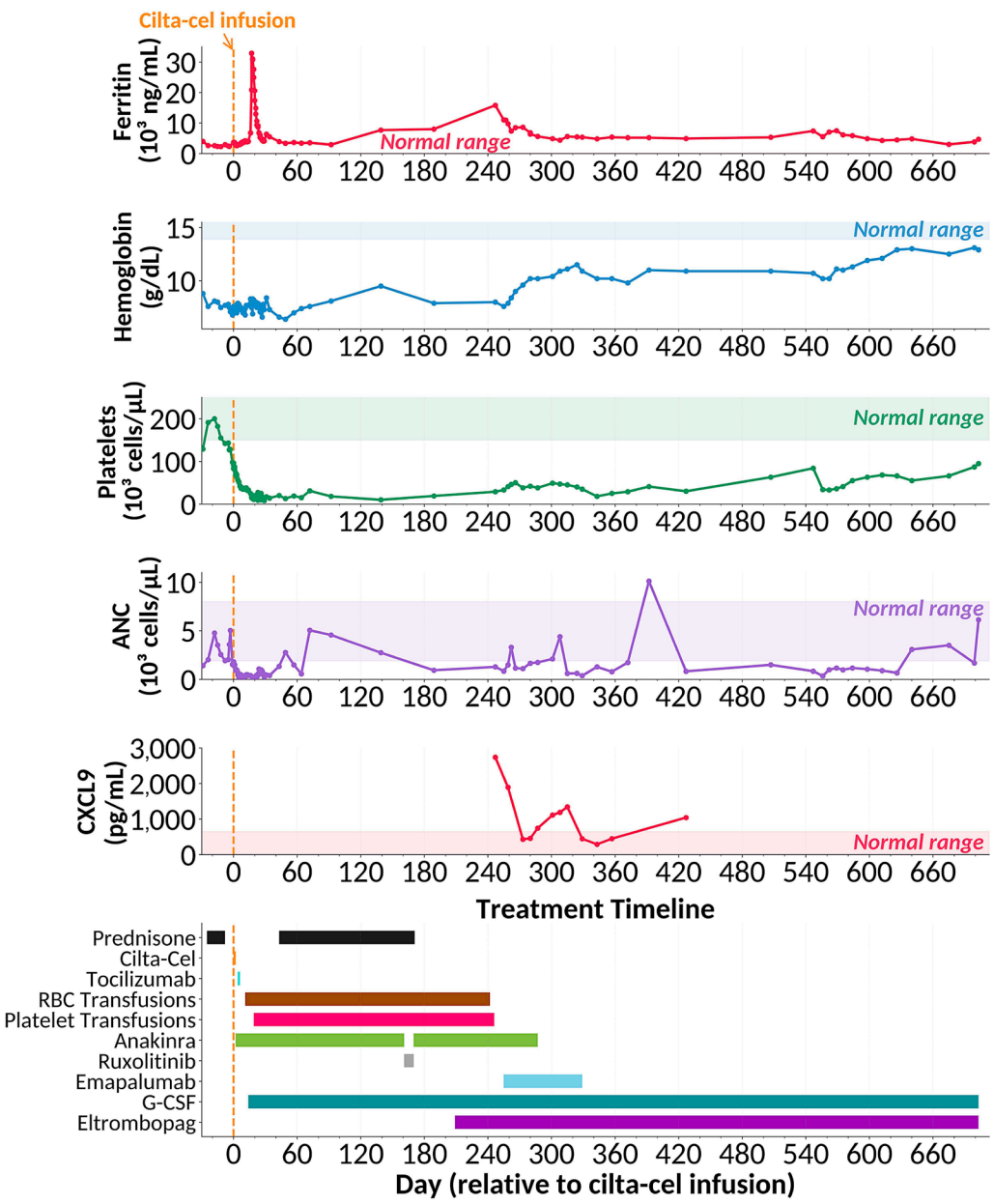

Figure 2. Longitudinal treatment course and hematologic recovery following chimeric antigen receptor T-cell therapy. This figure illustrates the complete therapeutic timeline beginning shortly before chimeric antigen receptor (CAR) T-cell infusion and extending to 1.5 years after the CAR T-cell therapy. Shown alongside the sequence of interventions are the corresponding trajectories of ferritin level, hemoglobin concentration, platelet and absolute neutrophil counts, and CXCL9 level. The figure highlights the period of refractory immune effector cell hemophagocytic lymphohistiocytic syndrome marked by cytopenias and hyperferritinemia and demonstrates the hematologic improvement following initiation of eltrombopag and emapalumab. ANC: absolute neutrophil count; cilta-cel: ciltacabtagene autoleucel; CXCL9: C-X-C motif ligand 9; G-CSF: granulocyte colony-stimulating factor; RBC: red blood cell.

within 280 days, reflecting immune reconstitution. Ferritin levels remain chronically elevated with stable counts.

Classical hemophagocytic lymphohistiocytosis features a hyperactivated yet ineffective immune response in which $CD8^+$ T cells produce high IFNγ levels, driving a self-amplifying inflammatory loop between lymphocytes and macrophages.[7] IEC-HS shares this pathophysiology, with CAR T cells inducing sustained macrophage activation via IFNγ.[2] Susceptibility is likely modulated by disease burden, CAR construct biology, host immune milieu, and antecedent inflammation.[2] Our patient had several pro-inflammatory features: high-risk myeloma, persistently elevated ferritin, antecedent PCL with hypereosinophilia, and γδ T-cell expansion (24% of lymphocytes during BsAb therapy). Although direct associations between PCL-associated hypereosinophilia or γδ expansion and IEC-HS are not established, BsAb can promote γδ T-cell expansion,[8] which may modulate eosinophil biology.[9] Notably, the manufactured CAR T-cell product contained a sizeable $CD4^+CD7^-$ population (24% of lymphocytes), a phenotype linked to chronic immune activation[10] and T-cell lymphoproliferative disorders,[11] suggesting that the BsAb-exposed T-cell compartment may have contributed to the pro-inflammatory trajectory.

The prolonged hyperinflammation likely reflected multiple non-mutually exclusive factors: robust, durable cilta-cel persistence sustaining immune activation beyond the CRS window; high disease burden (high B-cell maturation antigen expression) driving CAR T-cell activation; antecedent BsAb exposure skewing the T-cell compartment, evidenced by γδ expansion and $CD4^+CD7^-$ cells in the manufactured product; and marrow microenvironment priming by aggressive PCL with hypereosinophilia. The relative contributions of these factors cannot be determined from a single case but may inform risk stratification.

Chemotherapy plus stem cell boost before CAR T-cell therapy likely provided a benefit, as direct CAR T-cell infusion in the setting of progressive PCL and hypereosinophilia carried a high risk of severe CRS, ICANS, and MNT.[5] Persistent ferritin elevation prompted pre-emptive corticosteroids and prophylactic anakinra, which may have limited CRS to grade 1 and prevented ICANS; pre-CAR T tumor debulking with carmustine/melphalan likely also reduced inflammation. Longitudinal cytokine data highlight the transition from acute CRS to chronic IEC-HS: early declines in IL-1β and IL-6 levels indicated effective attenuation by anakinra and tocilizumab, but persistent IL-2Rα and TNFα

elevations through day 57, worsening transfusion-dependent cytopenias, and hyper-elevated ferritin concentrations suggested macrophage activation no longer responsive to IL-1/IL-6 blockade. Although IFNγ-pathway activity was not measured during the intervening period, the markedly elevated CXCL9 on day 247 and the rapid response to emapalumab support an IFNγ-driven process. The decision to use emapalumab was guided by the elevated level of CXCL9, a validated biomarker of systemic IFNγ activity in hemophagocytic lymphohistiocytosis.[4,12] A reduction below ~300 pg/mL correlates with treatment response,[12] and levels ≥3,500 pg/mL may identify patients most likely to benefit from IFNγ-targeted therapy.[13] Rapid CXCL9 normalization correlated with clinical improvement. Importantly, day-100 bone marrow demonstrated hemophagocytosis rather than hypocellularity, confirming that IFNγ neutralization - not additional stem cells - addressed the root cause. This distinction is clinically relevant: prolonged cytopenias after CAR T-cell therapies are common and stem cell boosts are increasingly used as a default intervention, but when cytopenias are driven by IEC-HS, additional stem cells will not resolve IFNγ-mediated marrow inflammation. Accurate identification of IEC-HS, guided by bone marrow morphology and CXCL9 levels, is essential for therapeutic decision-making.

Real-world experience with emapalumab for IEC-HS is limited, and high per-dose cost is a significant barrier, particularly in cases in which CXCL9 testing is unavailable.[2-4] However, CXCL9-guided selection provides a rationale that may optimize cost-effectiveness: in our patient, the transition from >70 transfusions to transfusion independence substantially reduced healthcare utilization. Eltrombopag played a complementary role by supporting hematopoietic progenitors and bypassing thrombopoietin receptor resistance in IFNγ-rich states.[14] This case highlights the importance of integrating CXCL9-guided IFNγ-directed immunomodulation with hematopoietic support in refractory IEC-HS, an approach that reversed prolonged inflammatory marrow failure while preserving a measurable residual disease-negative remission. As cellular therapies expand, early recognition of IEC-HS, biomarker-guided IFNγ-directed therapy, and tailored hematopoietic support will be essential for improving outcomes.

Authors

Tarek H. Mouhieddine,[1,2] Junia Vieira Dos Santos,[1] Harshita Sehgal,[1] Christian Salib,[3] Shafinaz Hussein,[3] Amy Duffield,[3] Shambavi Richard,[1] Adolfo Aleman,[1] Alessandro Lagana,[1] Samir Parekh[1] and Sundar Jagannath[1]

[1]Tisch Cancer Center, Department of Hematology and Medical Oncology, Icahn School of Medicine at Mount Sinai, New York, NY; [2]Jerome Lipper Multiple Myeloma Center, Division of Plasma Cell Neoplasias, Department of Medical Oncology, Dana-Farber Cancer Institute, Harvard Medical School, Boston, MA and [3]Department of Pathology, Molecular, and Cell-Based Medicine, Molecular Microbiology Laboratory, Icahn School of Medicine at Mount Sinai, New York, NY, USA.

Correspondence:
T.H. MOUHIEDDINE - tarek_mouhieddine@dfci.harvard.edu

https://doi.org/10.3324/haematol.2026.300894

Received: March 12, 2026.
Accepted: June 26, 2026.
Early view: July 2, 2026.

©2026 Ferrata Storti Foundation
Published under a CC BY-NC license

Disclosures

SR reports honoraria from Johnson & Johnson (J&J), Bristol Myers Squibb (BMS), Genentech, Karyopharm Therapeutics, MJH LifeSciences, Haymarket, and OncLive; research funding from J&J, BMS, C4 Therapeutics, AstraZeneca, and Heidelberg Pharma; and advisory/steering committee roles with BMS, Genentech, J&J, Karyopharm Therapeutics, and AstraZeneca. SP reports consulting or advisory roles with Grail, Celgene/BMS, Caribou Biosciences, imCORE, and Poseida Therapeutics; and research funding from the National Cancer Institute (R01 CA252222, R01 CA244899, R01 CA262754, K12 CA270375, CA196521). SJ reports consulting or advisory roles with BMS, J&J, Karyopharm Therapeutics, Legend Biotech, Takeda, Sanofi, Regeneron Pharmaceuticals, and Caribou Biosciences; and travel support from BMS, J&J, and Regeneron Pharmaceuticals. All other authors have no conflicts of interest to disclose.

Contributions

THM conceptualized the study, collected and analyzed data, and wrote the manuscript. SJ and SP conceptualized the study, analyzed and interpreted data, and edited the manuscript. JVDS, CS, SH, and AA analyzed and interpreted data and edited the manuscript. HS, AD, SR, and AL reviewed and edited the final manuscript.

Artificial Intelligence

Artificial intelligence (Claude, Anthropic) was used to assist with manuscript editing, including language refinement and word count reduction, and with generating figure plots. All scientific content, clinical data, data interpretation, and intellectual contributions were generated entirely by the authors. The authors assume full responsibility for the accuracy and integrity of the final manuscript.

Data-sharing statement

Data may be available upon request from the corresponding author.

References

1. Costa LJ, Banerjee R, Mian H, et al. International Myeloma Working Group Immunotherapy Committee recommendation on sequencing immunotherapy for treatment of multiple myeloma. Leukemia. 2025;39(3):543-554.
2. Hines MR, Knight TE, McNerney KO, et al. Immune effector cell-associated hemophagocytic lymphohistiocytosis-like syndrome. Transplant Cell Ther. 2023;29(7):438.e1-438.e16.
3. Zoref-Lorenz A, Witzig TE, Cerhan JR, Jordan MB. Malignancy-associated HLH: mechanisms, diagnosis, and treatment of a severe hyperinflammatory syndrome. Leuk Lymphoma. 2025;66(4):628-636.
4. Johnson WT, Epstein-Peterson ZD, Ganesan N, et al. Emapalumab as salvage therapy for adults with malignancy-associated hemophagocytic lymphohistiocytosis. Haematologica. 2024;109(9):2998-3003.
5. Gagelmann N, Dima D, Merz M, et al. Development and validation of a prediction model of outcome after B-cell maturation antigen-directed chimeric antigen receptor T-cell therapy in relapsed/refractory multiple myeloma. J Clin Oncol. 2024;42(14):1665-1675.
6. Henter JI, Sieni E, Eriksson J, et al. Diagnostic guidelines for familial hemophagocytic lymphohistiocytosis revisited. Blood. 2024;144(22):2308-2318.
7. Brisse E, Wouters CH, Matthys P. Hemophagocytic lymphohistiocytosis (HLH): a heterogeneous spectrum of cytokine-driven immune disorders. Cytokine Growth Factor Rev. 2015;26(3):263-280.
8. Mouhieddine TH, dos Santos JV, Ghodke-Puranik Y, et al. Immune dynamics associated with patient outcomes identified by multimodal single-cell analysis in multiple myeloma patients receiving talquetamab monotherapy. Blood. 2023;142(Suppl 1):1927.
9. Sanz M, Mann BT, Ryan PL, et al. Deep characterization of human gammadelta T cell subsets defines shared and lineage-specific traits. Front Immunol. 2023;14:1148988.
10. Moll M, Reinhold U, Kukel S, et al. CD7-negative helper T cells accumulate in inflammatory skin lesions. J Invest Dermatol. 1994;102(3):328-332.
11. Porwit-MacDonald A, Bjorklund E, Lucio P, et al. BIOMED-1 concerted action report: flow cytometric characterization of CD7+ cell subsets in normal bone marrow as a basis for the diagnosis and follow-up of T cell acute lymphoblastic leukemia (T-ALL). Leukemia. 2000;14(5):816-825.
12. Jacqmin P, Laveille C, Snoeck E, et al. Emapalumab in primary haemophagocytic lymphohistiocytosis and the pathogenic role of interferon gamma: a pharmacometric model-based approach. Br J Clin Pharmacol. 2022;88(5):2128-2139.
13. Johnson W, Rocco J, Patel R, et al. CXCL9 is a predictive biomarker of survival with IFNγ-targeted therapy in adult HLH patients. Blood. 2025;146(Suppl 1):2996.
14. Alvarado LJ, Huntsman HD, Cheng H, et al. Eltrombopag maintains human hematopoietic stem and progenitor cells under inflammatory conditions mediated by IFN-gamma. Blood. 2019;133(19):2043-2055.