

Key words

Massive, hemolysis, *Clostridium perfringens*.

Acknowledgements

This work was partially supported by Grant FIS96/0274 from the Government of Spain.

Correspondence

Dr. A. Pereira, M.D., Servicio de Hemoterapia y Hemostasia Hospital Clínic de Barcelona, Villarroel 170, 08036 Barcelona, Spain. Fax: international +34.93.2275448 – E-mail: apereira@medicina.ub.es

References

1. Chaplin H, Glazer H, Hockett R, Krewson L, Murphy K. Abdominal pain, total intravascular hemolysis and death in 53-year-old woman. *Am J Med* 1990; 88:667-74.
2. Hübl W, Mostbeck B, Hartleb H, Pointner H, Kofler K, Bayer PM. Investigation of the pathogenesis of massive hemolysis in a case of *Clostridium perfringens* septicemia. *Ann Hematol* 1993; 67:145-7.
3. Pun K, Wehner J. Abdominal pain and massive intravascular hemolysis in a 47-year-old man. *Chest* 1996; 110:1353-5.
4. Bätge B, Filejski W, Kurowski V, Klüter H, Djonlagic H. Clostridial sepsis with massive intravascular hemolysis: rapid diagnosis and successful treatment. *Intensive Care Med* 1992; 18:488-90.c
5. Ifthikaruddin J, Holmes J. *Clostridium perfringens* septicemia and massive intravascular haemolysis as a terminal complication of autologous bone marrow transplant. *Clin Lab Haemat* 1992; 14:159-61.
6. Jones T, O'Sullivan D, Smilack J. A 66-year-old woman with fever and hemolysis. *Mayo Clin Proc* 1996; 71:1007-10.
7. Bush G, Clements R, Phillips M, Kent R. *Clostridium perfringens* sepsis with intravascular hemolysis following laparoscopic cholecystectomy: a newly reported complication. *Am Surg* 1996; 62:326-7.
8. Gutierrez A, Florencio R, Ezpeleta C, Cisterna R, Martinez M. Fatal intravascular hemolysis in a patient with *Clostridium perfringens* septicemia. *Clin Infect Dis* 1995; 20:1064-5.
9. Singer A, Migdal P, Oken J, Chale S, Moll U. *Clostridium perfringens* septicemia with massive hemolysis in a patient with Hodgkin's lymphoma. *Am J Emerg Med* 1997; 15:152-4.
10. Rogstad B, Ritland S, Lunde S, Hagen A. *Clostridium perfringens* septicemia with massive hemolysis. *Infection* 1993; 21:60-2.

An atypical (b3/a3) junction of the *bcr/abl* gene lacking *abl* exon a2 in a patient with chronic myeloid leukemia

Sir,

We report the case of a patient with Philadelphia+ chronic myeloid leukemia expressing a rare type of BCR/ABL mRNA lacking ABL exon a2 sequences (BCR/ABL junction b3/a3). Clinical outcome showed brief hematologic remission. The role of the diversity of BCR/ABL fusion proteins and their relationship to

leukemia phenotype are discussed.

A small proportion of Philadelphia chromosome + (Ph+) chronic myeloid leukemia (CML) patients fail to express a b2/a2 or b3/a2 transcript¹⁻⁸ (Figure 1a). At present 8 Ph+ cases have been reported (3 CML, 4 ALL, 1 unknown) with a variant BCR/ABL mRNA expression lacking ABL exon a2 sequences^{5,6} (Table 1). Of the three CML patients only two had a b3/a3 junction. Herein, we report a further b3/a3 type of BCR/ABL transcript detected by RT-PCR in a patient with Ph+ CML. Conditions for blood cell lysis, RNA extraction, RT and PCR for BCR/ABL have been described.^{7,8} Specific PCR for BCR/ABL transcripts was performed using primers R110 (BCR exon e1) and AZ (ABL exon a3).

A 23-year-old male patient (M.R.) was diagnosed with chronic-phase CML in May 1994. His peripheral blood showed leukocytosis: WBC: $95.8 \times 10^9/L$; 1% basophils; 1% promyelocytes; 78% neutrophils; 13% lymphocytes; 7% monocytes; platelet count: $485 \times 10^9/L$; hemoglobin level: 12.7 g/dL. The spleen was not palpable. Cytogenetic analysis showed Ph chr. Therapy with Ara-C (40 mg/die/i.m. for ten days) plus α -interferon (α -IFN)⁹ (4 million $\mu/day/m^2$) (18 monthly course) was started: the WBC fluctuated between 2 and $5.5 \times 10^9/L$ during the following 18 months (hematologic remission). Then, due to progressive loss of hematologic remission and increased WBC, α -IFN was withdrawn and hydroxyurea therapy started. The patient is currently alive and well in first chronic phase. In initial screening by PCR, no expected amplification product was found with EA500 (ABL exon a3) and EA122 (BCR exon e12) primers (for e13/a2 or e14/a2 junctions), which usually amplify 99% of CML associated transcripts. A lower weight amplification product was detected 173 base pairs (bp) smaller than that expected for b3/a2 junction: 215 bp rather than the expected 388 bp (Figure 1b). Directly sequenced BCR/ABL cDNA PCR products revealed a b3/a3 junction and absence of c-ABL exon 2 derived sequences. To our knowledge, this

Table 1. Summary of leukemia types and molecular features of eight reported cases including the case presented in this letter.

Patient (age at onset)	Type of fusion products	Type of leukemia
1* (3 years)	b3/a3	cALL
2* (1 year)	e1/a3	cALL
3* (39 years)	e1/a3	ALL (pre-pre-B)
4* (61 years)	b2/a3	ALL (pre-B)
5* (unknown)	b2/a3	unknown
6* (59 years)	b2/a3	CML
7# (19 years)	b3/a3+b2/a3	CML
8* (39 years)	b3/a3	CML
9° (23 years)	b3/a3	CML

cALL, common ALL; pre-B ALL, precursor-B ALL; *cases reviewed in ref. 5; # case in ref. 6.; °present case.

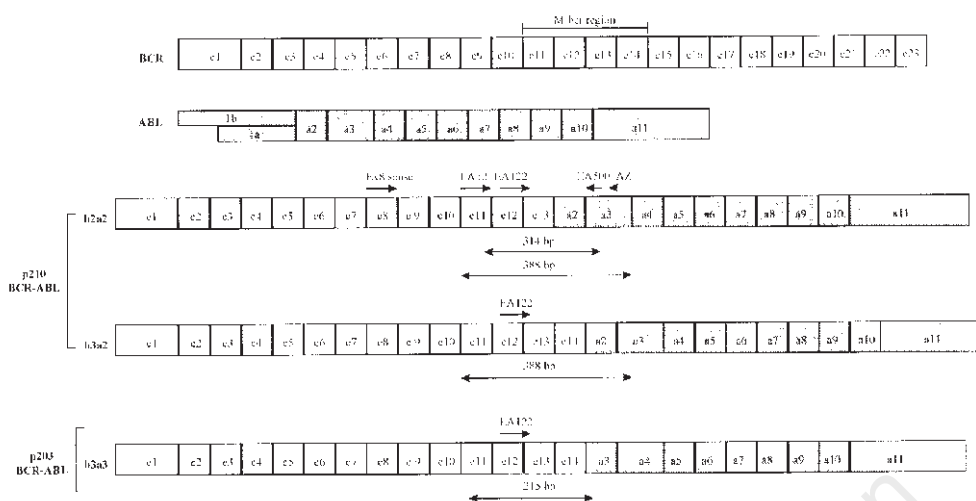


Figure 1a. Schematic representation of BCR, ABL, and some BCR/ABL mRNA transcripts. The most frequent and our reported BCR/ABL fusion proteins with their molecular masses (p210 and p203) and their corresponding bcr/abl RNA types of junction are indicated on the left side, respectively. White boxes = BCR exons (not in scale) numbered from e1 to e23; grey boxes = ABL exons (not in scale) numbered from a1 (alternatively spliced exons alb and ala, were represented) to a11. Primers AZ, EA12, EA122, and EA500 used for RT-PCR for BCR and BCR/ABL are designated by arrows. The expected amplification product sizes with different combination of primers were designed as a \leftrightarrow and the corresponding number of base pairs (bp) is given above the lines.

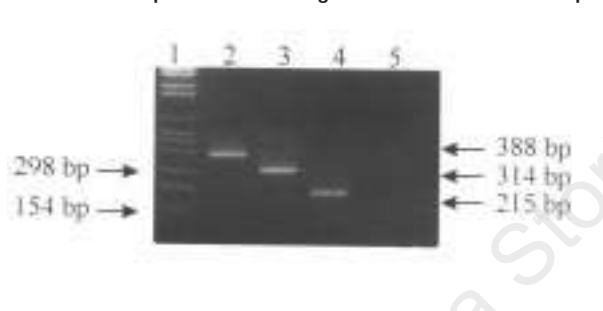


Figure 1b. Agarose gel electrophoresis separation of PCR for BCR/ABL transcripts. Lane 1 = Molecular weight marker VI from Boehringer Mannheim with some sizes of DNA which are recognized by numbers and arrows on the left and right sides of picture, respectively, lanes 2 to 4 = RT-PCR with primers EA122-EA500 from total RNA from four CML Ph⁺ patients with b3/a2 (lanes 2) or b2/a2 type of transcript (lanes 3), respectively. The expected sizes of PCR products (388 bp and 314 bp) are given on the left side of the picture in italic numbers and arrows; lane 4 = RT-PCR from patient M.R. with primers EA122-EA500 shows the presence of an amplified band of 215 bp corresponding to the b3/a3 type of transcript; lane 5: negative control for RT-PCR.

is the third Ph⁺ CML patient described with b3/a3 (or e14/a3) BCR/ABL. Our data show that rare breakpoints outside and inside M-bcr have to be considered in Ph⁺ CML and that variant BCR/ABL fusion transcripts and proteins can be expressed in Ph⁺ CML patients.¹⁰ Some variability of the molecular defects corresponding to the presence of a Ph chr exists in human hematologic malignancies. The roles of different BCR/ABL fusion proteins and their relationships to

leukemia phenotype are currently unclear. The age of our patient was similar to that of the other reported cases:^{5,6} one of the cases previously reported (#8 in Table 1) was a 39-year-old CML patient while the second was 19 (#7 in Table 1). This suggests that these breaks could be more frequent in young CML patients. The two patients with CML phenotype and b3/a3 transcript had high WBC counts and progression of disease during α -IFN therapy. In our patient, too, a high WBC was seen: this opens the question as to whether this is a characteristic of this variant Ph⁺ syndrome, according with the immunophenotype. Further studies will be needed in order to understand the clinical characteristic of these patients in relation to the molecular features.

Marilina Amabile,* Giovanni Martinelli,* Carolina Terragna,*
Vittorio Montefusco,* Antonio Tabilio,* Sante Tura*

*Institute of Hematology and Medical Oncology "Seragnoli",
University of Bologna; °Institute of Clinical Medicine,
University of Perugia, Italy

Acknowledgments

The authors are grateful to Mr. Robin MT Cooke for editorial assistance.

Funding

This work was supported by Italian Association of Cancer Research (AIRC), by Italian C.N.R. no. 98.00526.CT04 target project, by M.U.R.S.T. 40% and by "30 Ore per la Vita" AIL grants.

Correspondence

Giovanni Martinelli, M.D., Molecular Biology Unit, Institute of Hematology and Medical Oncology "Seràgnoli", University of Bologna, via Massarenti, 9, 40138 Bologna, Italy. Phone: international + 39-051-6364075 – Fax: international +39-051-398973 – E-mail: gmartino@kaiser.alma.unibo.it

References

- Zaccaria A, Martinelli G, Buzzi M, et al. M-BCR breakpoint location does not predict survival in Philadelphia chromosome-positive chronic myeloid leukemia. *Haematologica* 1992; 77:16-20.
- Saglio G, Guerrasio A, Tassinari A, et al. Variability of the molecular defects corresponding to the presence of a Philadelphia chromosome in human hematologic malignancies. *Blood* 1988; 72:1203-8.
- Saglio G, Guerrasio A, Rosso C, et al. New type of Bcr/Abl junction in Philadelphia chromosome-positive chronic myelogenous leukemia. *Blood* 1990; 76:1819-24.
- Pane F, Frigeri F, Sindona M, et al. Neutrophilic-chronic myeloid leukemia: a distinct disease with a specific molecular marker (BCR/ABL with C3/A2 junction). *Blood* 1996; 88:2410-4.
- Iwata S, Mizutani S, Nakazawa S, Yata J. Heterogeneity of the breakpoint in the ABL gene in cases with BCR/ABL transcript lacking ABL exon a2. *Leukemia* 1994; 8:1696-702.
- Polak J, Zemanova Z, Michalova K, Klamova H, Cermak J, Haskovec C. A new case of chronic myeloid leukemia (CML) in myeloid blast crisis with an atypical (b3/a3) junction of the BCR/ABL gene [letter]. *Leukemia* 1998; 12:250.
- Testoni N, Martinelli G, Farabegoli P, et al. A new method of "in cell RT-PCR" for the detection of bcr-abl transcript in chronic myeloid leukemia patients. *Blood* 1996; 87:3822-7.
- Martinelli G, Testoni N, Montefusco V, et al. Detection of bcr-abl transcript in chronic myelogenous leukemia patients by reverse transcription polymerase chain reaction and capillary electrophoresis. *Haematologica* 1998; 83:593-601.
- Stegmann JL, Granados E, Penarrubia MJ. Interferon-alpha lymphoblastoid in chronic myeloid leukemia patients unresponsive to recombinant IFN alpha 2. *Haematologica* 1997; 82:731-2.
- Hochhaus A, Reiter A, Skladny H, et al. A novel BCR-ABL fusion gene (e6a2) in a patient with Philadelphia chromosome-negative chronic myelogenous leukemia. *Blood* 1996; 88:2236-40.

Cytomegalovirus retinitis revealing a leukemic γ/δ t-cell lymphoma

Sir,

We report a case of γ/δ T-cell lymphoma (γ/δ TCL) in a patient treated for sarcoidosis, revealed by cytomegalovirus (CMV) infection. Clinical presentation was atypical with lymph node and leukemic involvement. To our knowledge, such a clinical history has never been reported.

Case report. A 44-year-old man was admitted to

Table 1.

	1994	1996
<i>Peripheral blood lymphocytes</i>		
Total count ($\times 10^9/L$)	0.88	1.0
% CD3	60	83
% CD4	33	3
% CD8	32	2
% CD56	19	Not done
% γ/δ T cells	0	74
<i>Lymph nodes</i>		
Morphology	Lymphoid hyperplasia B and T	Diffuse pleiomorphic lymphoid cell proliferation with irregular nuclei
Immunostaining	Normal	γ/δ TCR+, $\alpha\beta$ TCR-, CD3+, CD43+, CD45+, CD4-, CD8-, CD5-

hospital in May 1994, because of pruritic papulous skin lesions. Cervical and inguinal nodes were enlarged. Hematologic tests showed eosinophils $1.24 \times 10^9/L$; lymphocytes: $0.88 \times 10^9/L$; ESR: 10 mm per hour; serum angioconvertase activity: 266 IU/mL (N=45-145). The immunophenotypic profile of peripheral blood lymphocytes (PBCL) evidenced an increase in CD56+ without γ/δ T cells (Table 1). Skin biopsy showed a sarcoid-like granulomatous inflammation. The histologic characteristics of the cervical lymph nodes were lymphoid B and T hyperplasia. There were no atypical lymphoid cells. A diagnosis of sarcoidosis was made. Prednisolone was started, with effect on the skin lesions.

In September 1996 this patient developed sudden visual loss. Ophthalmologic examination and serological tests evidenced a CMV retinitis. There was generalized lymphadenopathy and splenomegaly, but not hepatomegaly. Lumbar puncture was normal. The HIV test was negative. The immunophenotypic profile of PBCL evidenced CD4 and CD8 lymphocytopenia with 74% of γ/δ T cells+. A CT scan revealed mediastinal lymph nodes and homogenous splenomegaly. The bone marrow biopsy was normal and CD3 immunostaining did not reveal neoplastic infiltrating. Treatment with foscarnet induced stabilization of the retinal lesions. Histopathologic examination of a lymph node showed a diffuse pleiomorphic CD3+, CD4-, CD5-, CD8-, CD43+, CD19-, CD56-, CD45+ lymphoid cell proliferation. The lymphoid cells were atypical with abundant cytoplasm and irregular nuclei. The cells were γ/δ TCR+, TiA-1+, granzyme B+. Epstein-Barr virus was detected (LMP-1+). Polymerase chain reaction revealed a clonal rearrangement of γ T cell receptor gene and heavy (IgH) chain immunoglobulins. Sequential chemotherapy was started with no improvement. Monoclonal gammopathy (MG) IgG λ appeared after four