

- from a functional enigma. *Blood* 1989; 73: 625-35.
8. Spiekermann K, Emmendoerffer A, Elsner J, et al. Altered surface marker expression and function of G-CSF-induced neutrophils from test subject and patients under chemotherapy. *Br J Haematol* 1994; 87:31-8.

Resolution of thrombocytopenia after treatment for *Helicobacter pylori*: a case report

Sir,

We report the case of a 51-year-old man with idiopathic thrombocytopenic purpura who experienced a complete and lasting normalization of platelet count after antibiotic treatment for a *Helicobacter pylori* infection.

A 51-year-old man with previously untreated chronic idiopathic thrombocytopenic purpura (ITP) was admitted because of melena. An upper gastrointestinal endoscopy showed a small bleeding ulcer in the paracardial region of the stomach. The patient was treated with i.v. ranitidine until endoscopically documented resolution of bleeding, and with a short course of i.v. immunoglobulins (40 g/die for 4 days), which allowed the platelet count to increase to a maximum of $162 \times 10^9/L$. Soon after a laparosplenectomy was performed without complications. The patient was discharged three days after surgery with a platelet count of $40 \times 10^9/L$. He continued to take ranitidine orally (150 mg daily) for 2 months. Six months after his splenectomy he was admitted again because of a second episode of endoscopically documented gastric bleeding manifested by melena. Over this period his platelet count never exceeded $100 \times 10^9/L$ (Figure 1).

Considering that about 80% of gastric ulcers are associated with *Helicobacter pylori* infection^{1,2} and that our patient had a positive serologic test for *Helicobacter* (35 IU/mL, normal values less than 15 IU/mL) (Enzygnost anti-*Helicobacter pylori*, Boehringer, Germany) he was treated with amoxicillin (1 g three times a day) and omeprazole (40 mg daily) for 14 days. Afterwards he continued assuming oral omeprazole (20 mg daily). His platelet count, which was monitored every two weeks, started to increase at the end of antibiotic therapy and reached normal and stable values after 5 weeks (Figure 1). The first endoscopic control was performed 6 weeks after the end of treatment. No ulcers were seen, nor was *Helicobacter pylori* found, but a polyclonal B lymphocytic infiltration of the mucosa was detected. Three subsequent endoscopic controls with multiple biopsies were performed every three months. Histologic specimens remained negative for *Helicobacter pylori* and the lymphocytic infiltrate was not documented again. A serologic test for *Helicobacter pylori* was 20 IU/mL 6 months after the end of therapy. *Helicobacter pylori* infection can be associated with development of lymphoid follicles in the stomach, which may disappear after eradication of the micro-organism.^{3,4} This kind of infection has been hypothesized to be related with the development

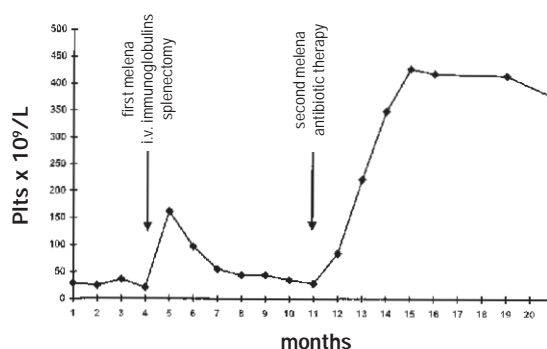


Figure 1. A diagnosis of chronic ITP was established three months before the first melena. Platelet count ranged between 25 and $35 \times 10^9/L$, bone marrow was normal and a direct antiplatelet antibodies test was positive. After the first episode of melena, the patient was treated with high dose i.v. immunoglobulins and splenectomy with a transitory response. After the second melena the patient was treated with amoxicillin and omeprazole and achieved a complete and stable response.

of gastric MALT lymphoma;^{5,6} its possible involvement in some autoimmune disorders is still an open question.^{7,8} Recently it was reported that *Helicobacter pylori* eradication can be followed by a significant increase in platelet count in patients with ITP and that the prevalence of such infection in patients with ITP can be high.⁹ Diagnosis of *Helicobacter pylori* infection in our case was based only on epidemiological probability and serologic data, since it was not possible to obtain histologic documentation of infection and other non-invasive tests were not available. The diagnostic accuracy of serology is, however, high¹⁰ and the infection was very probable in our patient who had a gastric ulcer and a positive serologic test. The normalization of his platelet count following antibiotic treatment was impressive: on the basis of this observation and of the recent report by Franceschi *et al.*⁹ a relationship between *Helicobacter pylori* infection and ITP can be hypothesized. This deserves further investigation in a larger number of patients.

Stefania Grimaz, Daniela Damiani, Piero Brosolo,*
Cristina Skert, Antonella Geromin, Giovanni de Pretis*

Chair and Division of Hematology, Department of Clinical and Morphological Research, University Hospital, and *Division of Gastroenterology and Digestive Endoscopy, S. Maria della Misericordia Hospital, Udine, Italy

Key words

Thrombocytopenia, *helicobacter pylori*

Correspondence

Stefania Grimaz, Chair and Division of Hematology, University Hospital, p. S. Maria della Misericordia, 33100 Udine, Italy. Phone: international +39-0432-559662 – Fax: international +39-0432-559661 – E-mail: daniela.damiani@drmm.uniud.it

References

1. Sobala GM, Axon ATR. *Helicobacter pylori*, gastric ulceration and postoperative stomach. In: Rathbone BJ, Heatley RV, eds. *Helicobacter pylori* and gastroduodenal disease. Oxford: Blackwell Scientific Co.; 1992. p. 150-7.
2. Walsh JH, Peterson WL. The treatment of *Helicobacter pylori* infection in the management of peptic ulcer disease. *N Engl J Med* 1995; 333:984-91.
3. Valle J, Seppala K, Sipponen P, Kosunen T. Disappearance of gastritis after eradication of *Helicobacter pylori*. A morphometric study. *Scand J Gastroenterol* 1991; 26:1057-85.
4. Genta RM, Hammer HW, Graham DY. Gastric lymphoid follicles in *Helicobacter pylori* infection: frequency, distribution and response to triple therapy. *Hum Pathol* 1993; 24:557-63.
5. Wotherspoon AC, Ortiz-Hidalgo C, Falzon M, Isaacson PG. *Helicobacter pylori*-associated gastritis and primary B-cell gastric lymphoma. *Lancet* 1991; 338: 1175-6.
6. Parsonnet J, Hansen S, Rodriguez I, et al. *Helicobacter pylori* infection and gastric lymphoma. *N Engl J Med* 1994; 330:1267-71.
7. Negrini R, Lisato L, Zanella I, et al. *Helicobacter pylori* infection induces antibodies cross-reacting with human gastric mucosa. *Gastroenterology* 1991; 101: 437-45.
8. Wright DH. Lymphomas of mucosa-associated lymphoid tissue and antigen drive. *J Pathol* 1996; 178: 111-2.
9. Franceschi F, Gasbarrini A, Tartaglione R, et al. Regression of autoimmune thrombocytopenic purpura after *Helicobacter pylori* eradication [abstract]. Paper presented at the Digestive Disease Week, New Orleans, LA, May 17-20, 1998; 1222, A-302.
10. De Boer WA. Diagnosis of *Helicobacter pylori* infection. Review of diagnostic techniques and recommendations for their use in different clinical settings. *Scand J Gastroenterol* 1997; 32(suppl 223):35-42.

HFE mutation analysis in patients with hepatitis C virus with positive screening for iron overload

Sir,

Patients with hepatitis C virus (HCV) infection frequently have increased levels of serum ferritin and transferrin saturation. Determination of the HFE mutations for hereditary hemochromatosis was performed in 37 patients with positive iron overload screening and HCV infection. The C282Y mutation was observed only in few cases (allele frequency 6.7%). However, the H63D mutation was more frequent than in the control group (28.4% vs 15.7%). The role of this mutation in the iron abnormalities of these patients needs to be clarified.

It has been reported that patients with liver damage due to HCV have higher levels of serum ferritin and transferrin saturation than hepatitis B virus-positive patients. The levels of serum ferritin and transferrin saturation have been correlated with liver iron concentration in HCV patients.¹ Moreover, some

authors have postulated that determination of HFE mutations is the best diagnostic test for hereditary hemochromatosis (HH).² The aim of this work was to ascertain the role of HFE mutations in HCV patients with high levels of transferrin saturation and serum ferritin (a positive iron overload screening).

Accordingly, 37 outpatients with HCV infection and positive screening for iron overload (serum ferritin higher than 450 µg/L and transferrin saturation exceeding 45%) were analyzed by PCR reactions and enzymatic digestions of amplified products for the two known HFE gene mutations related to HH (C282Y, in which cysteine is replaced by tyrosine at position 282, and H63D, in which aspartic acid replaces histidine).³

Only 1 case out of 37 was homozygous for the C282Y mutation of the HFE gene and 3 were heterozygous (allele frequency 6.7%). As for the second mutation, two cases were homozygous and 17 were heterozygous for the H63D mutation of the HFE gene (allele frequency 28.4%).

When these results were compared with those of a group of blood donors who were studied by our group, no difference in the C282Y mutation was observed (Fisher's exact test, $p=0.21$). However, the prevalence of the second mutation (H63D) was significantly higher than that in the anonymous voluntary donors living in our area (Chi square, $p=0.016$)⁴ (Table 1).

Our data do not confirm an association of iron abnormalities in HCV infected patients with the C282Y mutation of HFE; however, it seems that a larger group of patients will be necessary to establish the frequency of the C282Y mutation in HCV patients. On the other hand, the high frequency of the H63D mutation in these patients suggests that this mutation plays a role. However, the significance of this mutation remains obscure and some authors have suggested that in these cases the HFE protein has an abnormal function.⁵ Similar results have been published regarding patients with porphyria cutanea tarda in an Italian study.^{6,7}

Table 1. Genotype frequencies for the HFE mutations in HCV infected patients compared with those in a group of blood donors.

Genotypes	HCV (n=37)	Blood donors (n=108)
CC/HH	14	70
CY/HH	3	6
YY/HH	1	-
CC/HD	17	28
CC/DD	2	2
CY/HD	-	2
C282Y*	6.7%	3.7%
H63D*	28.4%	15.7% [#]

Genotypes are given for amino acid 282 (C282Y)/amino acid 63 (H63D) of the HFE protein. CC/HH is the wild type. *Allele frequencies. #Statistical difference ($p=0.012$, Chi square test).