



## Acute hemorrhagic leukoencephalitis in patients with acute myeloid leukemia in hematologic complete remission

LIVIO PAGANO,\* LUIGI MARIA LAROCCA,<sup>o</sup> MARIA LUGIA VACCARIO,<sup>#</sup> CARLO MASULLO,<sup>#</sup> ANDREA ANTINORI,<sup>@</sup> FRANCESCO PIERCONTI,<sup>o</sup> TOMMASO TARTAGLIONE,<sup>^</sup> PAOLA CATTANI,<sup>§</sup> LUCA MELE,\* FRANCESCO EQUITANI,\* GIUSEPPE LEONE\*

\*Istituto di Semeiotica Medica, <sup>o</sup>Istituto di Anatomia Patologica, <sup>#</sup>Istituto di Neurologia, <sup>@</sup>Istituto di Malattie Infettive,

<sup>^</sup>Istituto di Radiologia, <sup>§</sup>Istituto di Microbiologia, Università Cattolica del Sacro Cuore, Rome, Italy

### ABSTRACT

The authors describe the cases of three patients affected by acute myeloid leukemia, in complete remission, who rapidly developed neurologic symptoms leading to death. Neither clinical characteristics, nor radiological or microbiological procedures, allowed an etiological diagnosis of the neurologic syndrome. *Post-mortem* examination of the brain showed both macroscopic and microscopic findings compatible with acute hemorrhagic leukoencephalitis. The difficulty in distinguishing this entity from other CNS disease-related complications (e.g. leukemia infiltration, drug toxicity, hemorrhages) should not lead to an underestimation of the true incidence of this complication. We believe that with more attention to the possibility of this complication there would probably be both a greater possibility of collecting clinical informations about the real impact of this dramatic disease and a stronger hope of finding the right treatment for it.

©1999, Ferrata Storti Foundation

Key words: acute hemorrhagic leukoencephalitis, acute myeloid leukemia

Central nervous system (CNS) involvement during the course of acute leukemia is not infrequent and may be due to various causes that are divided into those that are a direct effect of the disease upon CNS and those primarily treatment-related. It is well recognized that the CNS may be infiltrated by myeloid or lymphoid leukemia cells, either as meningeal leukemia or as nodular masses.<sup>1-3</sup>

Other major causes of CNS involvement in patients with hematologic malignancies are infectious diseases. *Staphylococcus epidermidis* or *S. aureus* frequently complicate chemotherapy of leukemic CNS infiltration, performed by reservoir.<sup>4</sup> Other frequent causes of CNS infection are filamentous fungi: *Aspergillus spp.* or *Mucorales*,<sup>5,6</sup> can induce the development of fatal cerebral abscesses. Viruses as

*Cytomegalovirus* (CMV), *Herpes simplex virus* (HSV), *Varicella-zoster virus* (VZV) and *JC virus* (JCV), by inducing leukoencephalitis and so causing irreparable damage, play a relevant role in CNS damage, especially in leukemic patients who have undergone bone marrow transplantation procedures.<sup>7-9</sup> Cerebral toxoplasmosis and cryptococcosis are observed more rarely in leukemic patients than in HIV patients.

In literature we find descriptions of neurologic syndromes due to different chemotherapeutic agents, such as L-asparaginase or methotrexate. The onset of these syndromes may occur either during different therapeutic phases of the antileukemic treatment or during transplantation procedures.<sup>10,11</sup> Furthermore there is a high risk of CNS bleeding in all leukemic patients because of the marked thrombocytopenia related to leukemic bone marrow infiltration or following chemotherapy.<sup>12,13</sup>

In this paper we report the cases of 3 patients with acute myeloid leukemia (AML) who died, in complete remission (CR), of neurologic complications. All patients presented the same clinical characteristics and the complication led rapidly to death within few days. The *post-mortem* findings were diagnostic of acute hemorrhagic leukoencephalitis (AHE).

### Case report

Between January 1992 and December 1997 we recorded 231 new cases of adult patients, aged from 15 to 91 years old, with acute leukemia (178 AML and 53 acute lymphoblastic leukemia). Twenty-six cases of neurologic complications were observed: 13 CNS leukemia (8 ALL and 5 AML), 5 hemorrhages (3 AML and 2 ALL), 1 encephalitis due to drug toxicity (methotrexate) in a patient with ALL, and 4 fungal infections (2 *Aspergillus spp.*, 1 *Mucor spp.* and 1 *Blastoschizomyces capitatus*) all in AML patients. Of the AML patients, 86 (50%) achieved a CR and three of them (3.4%) developed neurologic symptoms evolving into coma. These three patients died and autopsy showed the typical picture of acute hemorrhagic leukoencephalitis.

Correspondence: Livio Pagano, MD, Istituto di Semeiotica Medica, Università Cattolica S. Cuore, Largo Francesco Vito 1, 00168 Rome, Italy. Fax: international +39-06-3051343.

**Case #1**

A 71-year-old white man was diagnosed as being affected by acute myeloid leukemia (FAB M5a). Since his clinical condition was good, he started chemotherapy with mitoxantrone and cytosine arabinoside (Ara-C). During the post-chemotherapeutic phase of aplasia he developed a fever of unidentified origin (38.7°C). He was treated with a combination of broad-spectrum antibiotics (cephalosporine plus aminoglycoside) and recovered from the infection. A bone marrow examination, performed at recovery from aplasia, demonstrated the achievement of CR. A few days after this examination, the patient developed asthenia, diarrhea and neurologic symptoms (slurred speech, vomiting, somnolence and confusion). A diagnostic lumbar puncture showed normal CSF glucose and protein concentrations and a cerebrospinal fluid cellular count of 4/mm<sup>3</sup>. A full blood count showed Hb 12.1 g/dL, WBC 14.5×10<sup>9</sup>/L (neutrophils 12×10<sup>9</sup>/L and lymphocytes 0.5×10<sup>9</sup>/L) and a platelet count of 256×10<sup>9</sup>/L. Coagulation parameters (PT, aPTT, fibrinogen) were within the normal ranges. Treatment with glycerol and glucocorticoids was started but the neurological deterioration progressed and the patient died without having responded to treatment.

**Case #2**

A 44-year-old white female with AML (FAB M5a) achieved a CR after induction treatment (idarubicin, Ara-C, etoposide). During the aplasia following consolidation treatment (amsacrine plus Ara-C) she developed a polymicrobial bacteremia, due to *Candida albicans* and *Flavobacterium spp.* associated with pneumonia. She was treated with a cephalosporine plus aminoglycoside and amphotericin B and recovered. Seventeen days later, the patient developed visual disturbances, bilateral Lasègue sign, left facial paresis and confusion. Examination of the CSF revealed: glucose 124 mg/dL, protein 16 mg/dL, cells 1/mm<sup>3</sup>. The full blood count showed leukocytosis (15×10<sup>9</sup>/L) with a marked increase in neutrophils (13×10<sup>9</sup>/L) and lymphopenia (0.4×10<sup>9</sup>/L). Platelet count (212×10<sup>9</sup>/L) and other coagulative parameters were normal. Glycerol and glucocorticoid therapy was immediately administered intravenously but neurologic signs (vomiting, diarrhea, disturbance of consciousness and bladder incontinence) rapidly worsened evolving into coma. The patient died without any signs of leukemia relapse after 9 days.

**Case #3**

A 70-year-old white man was diagnosed as having AML (FAB M0). Except for a previous history of chronic subdural hematoma he was in a good clinical condition. Induction treatment with idarubicin plus Ara-C was prescribed. One month after the start of chemotherapy the patient, who had achieved a CR, developed a *Pseudomonas aeruginosa* bacteremia associated with pneumonia. Targetted antibiotic treatment with cephalosporine plus aminoglycoside induced recovery from the infection. A few days later

he manifested neurologic symptoms characterized by headache, sphincter incontinence, lower limb paresis and hypotonia and a mild left finger-to-nose dysmetria; furthermore he developed vomiting and diarrhea. A full blood count revealed 10.3×10<sup>9</sup>/L WBC with 8.3×10<sup>9</sup>/L neutrophils and 1×10<sup>9</sup>/L lymphocytes, 300×10<sup>9</sup>/L platelets and 13.5 g/dL hemoglobin. Coagulation parameters were within the normal ranges. A lumbar puncture showed mildly increase glucose (57 mg/dL) and protein concentrations (81 mg/dL) and 2/mm<sup>3</sup> cells. Despite treatment with glucocorticoids and glycerol, the altered state of consciousness progressively worsened into deep coma and the patient died after 10 days.

**Results**

The clinical characteristics and laboratory results of the three patients are summarized in Table 1.

**Hematologic and chemical examinations**

At the onset of neurologic symptoms and in the follow-up the blood count revealed normal hemoglobin levels and platelet counts, but in all cases substantial neutrophilia (ANC >10×10<sup>9</sup>/L). Coagulation parameters were within the normal ranges. Bone marrow examination demonstrated complete remission.

None of the patients had metabolic abnormalities or showed hyperammonemia.

CSF glucose and cell count were normal in all patients, whereas CSF protein content was increased in two patients.

**Microbiological studies**

Serology for CMV, HSV, VZV, *Epstein-Barr virus* (EBV), *human immunodeficiency virus*, *Cocksakie virus B1-B6*, *Measles*, *Rubella* and *Cryptococcus*, as well as fungal stains, bacilli smears and culture studies, were negative. CSF samples as well as tissue samples obtained during autopsy were tested for bacteria, fungi, CMV, HSV, VZV, JVC, EBV and *Toxoplasma gondii*.

DNA amplification for EBV-DNA, JCV-DNA and *T. gondii*-DNA was performed on the CSF samples by nested PCR techniques.<sup>14-16</sup> Moreover, the same PCR were performed on paraffin embedded tissue samples, after having removed the paraffin. HSV-DNA and CMV-DNA amplification were also performed by nested PCR on CSF specimens.<sup>17-19</sup>

The nested PCR, both on CSF and on autopsy tissues, gave negative results in all patients.

**Electroencephalography**

In all patients an EEG, performed at the onset of the neurologic symptoms, showed diffuse slow aspecific activity without focal signs.

**Radiological procedures**

*CT brain scan.* CT did not reveal focal alteration of brain parenchyma density or pathologic enhancement after contrast medium administration in any patient. In all cases CT could only demonstrate diffuse atrophic changes.

*Brain magnetic resonance imaging.* MRI was performed

**Table 1a. Clinical and laboratory characteristics of patients.**

Case	Underlying leukemia	Infectious prodromi	Latency between infectious prodromi and neurologic symptoms	Latency between neurologic symptoms and death	Signs and symptoms	Microbiological exams, CSF and CNS tissue	CSF results		
							Glucose	Protein	Cells
#1	AML-M5a	FUO	15 days	15 days	confusion, somnolence, vomiting	negative	56	47	3
#2	AML-M5a	fungemia, bacteremia pneumonia	17 days	9 days	visual disturbances, confusion, Lasègue sign, left VII paresis, vomiting, incontinence	negative	124	16	1
#3	AML-M0	bacteremia pneumonia	9 days	10 days	headache, incontinence, frenage, vomiting	negative	57	81	2

**Table 1b. Results of EEG and brain imaging.**

Case	EEG	Brain CT scan	Brain MRI
#1	diffuse	atrophic changes slowing	not performed
#2	diffuse	atrophic changes slowing	atrophic changes, hyperintensity on Pdw and T2w images of both thalami
#3	diffuse slowing	atrophic changes and chronic subdural hematomas	atrophic changes; leukoencephalopathic foci

in only two cases. Diffuse signal hyperintensity of both thalami and periaqueductal WM was evident on both proton density weighted (Pdw) and T2-weighted (T2w) images. These images demonstrated some small hyperintense parenchymal areas interpreted as aspecific leukoencephalopathic changes, located in the subcortical frontal and parietal white matter, in the corona radiata and in the centrum semiovalis. In both patients MRI confirmed the CT evidence of atrophic degenerative parenchymal changes. No pathologic intracranial contrast enhancement was identified in the brain parenchyma after gadolinium injection.

#### **Histologic examination**

The autopsy examination was limited to the brain following our usual practice in these circumstances. Macroscopic examination of the brain, performed according to Chacot's technique, did not show any typical lesions related to opportunistic infections. The cerebral hemispheres appeared symmetrical but swollen and softened. The leptomeninges were minimally thickened and opacified; serial coronal sections of parietal or posterior regions showed demarcation between grey and white matter, which appeared edematous, discolored and softened with diffuse petechial hemorrhages. The components of

the basal ganglia and the internal capsule were softened, congested and edematous too, and they also contained petechial hemorrhages. The ventricles were reduced in size.

Microscopic examination of cerebral parenchyma, the meninges and subarachnoid spaces did not show any leukemic infiltration, but did show several areas characterized by marked edema, and pericapillary extravasation of erythrocytes without evidence of destruction of the blood vessel walls. In addition ball and ring hemorrhages around vessels associated with microglial reaction and focal demyelination, as shown by the Marchi stain, were present (Figures 1 and 2).

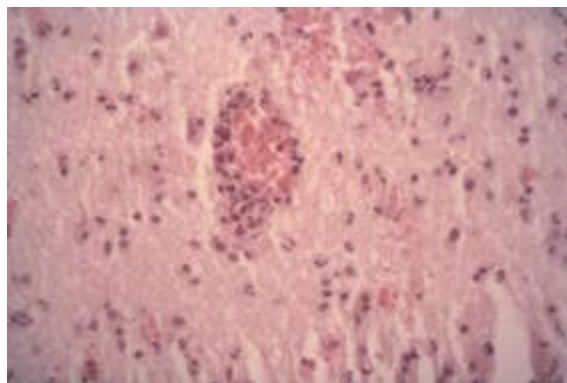
#### **Discussion**

Neurologic complications in patients with acute leukemia are rather frequent and potentially serious. The CNS damage can be the consequence of either direct or indirect effects of malignancy, or complications of chemotherapy.<sup>1-6</sup>

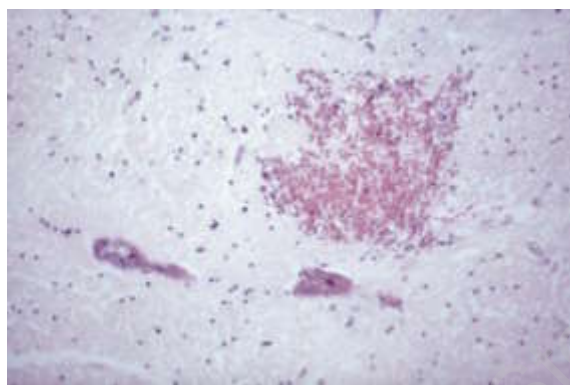
No part of the CNS is immune from potential damage and several reports highlight an increase of these complications especially in transplanted patients.<sup>7-9</sup> A direct drug-related toxic effect, drug-induced metabolic encephalopathy, drug-induced intracranial hemorrhage or infection (due to myelosuppression) or modification of mental attitude and behavior as a consequence of the drugs may be manifestations of neurotoxicity in patients who have received high doses of chemotherapy. Moreover neurological syndromes due to paraneoplastic cerebellar degeneration, caused by an autoimmune mechanism, have been reported in hematologic malignancies, in particular in patients with Hodgkin's disease.<sup>13,20,21</sup>

All our cases had a similar clinical course: in hematologic CR, a few days after an infection (FUO, sepsis, pneumonia) they developed a neurologic syndrome which rapidly evolved into coma and death. Since there was the suspicion of infectious encephalitis, all the patients underwent various microbiological tests, but none of these laboratory examinations were positive. Neither the EEG nor the CSF studies





**Figure 1.** Neutrophils present in the vessel wall and spreading in the white matter constitute the inflammatory infiltration in acute hemorrhagic encephalitis (×250, May Grünwald Giemsa stain).



**Figure 2.** In white matter there are ball and ring hemorrhages associated with necrosis of white matter in a perivascular distribution and spreading into the brain tissue (×400, E.E. stain).

revealed significant abnormalities. The CT scan showed aspecific brain atrophy. At MRI a diffuse alteration of the signal intensity of both thalami and periaqueductal white matter was observed. Symptomatic treatment and empirical anti-infective therapies were completely ineffective and only autopsy allowed the cause of death to be diagnosed.

The microscopically revealed presence in the brain of typical small ring and ball hemorrhages around the vessels, without evidence of severe wall damage, marked edema, leukocytes spreading in the white matter and pericapillary extravasation of erythrocytes was diagnostic of acute hemorrhagic encephalitis.

Acute hemorrhagic leukoencephalitis is a rare hyperacute inflammatory disease of cerebral white matter, and was established as a pathologic entity in 1941.<sup>22</sup> It is characterized by the development in a few days of severe neurologic symptoms (confusion, stupor, speech disturbance, hemiparesis, seizures).<sup>23,24</sup> Coma and death commonly follow within a week. The usual laboratory findings are: peripheral neutrophilia, mild

increase of CSF protein, aspecific and diffuse slow cerebral electrical activity. CT scan and MRI show areas of demyelination or edema plus areas subsequently evolved into hemorrhagic lesions.<sup>25</sup> A temporal relationship has been noted between certain infective diseases, such as upper respiratory tract infections, VZV and, especially, *Mycoplasma pneumoniae*, and the subsequent development of AHE in the following 2-3 weeks.<sup>22,24</sup> The pathogenesis of this syndrome is unknown but the possibility of it having an autoimmune origin is supported by various factors such as a latency between a previous infection and the onset of leukoencephalitis, and the lack of identification of an infectious organism.<sup>22</sup> Support for the autoimmune etiology hypothesis is strengthened by the similarity of AHE to experimental allergic encephalomyelitis; furthermore in humans with acute disseminated encephalomyelitis there is evidence of activation of autoreactive T-cells against myelin basic protein.<sup>26,27</sup> Due to the rapid clinical course and to the difficulty of a complete diagnosis before the cerebral histological examination, usually only autopsy is able to confirm the diagnosis.

In literature many therapies, both medical (immunosuppressive therapy with a combination of glucocorticoids and cyclophosphamide, and plasmapheresis) and surgical, have been tested, but patients seldom recover from this complication.<sup>24, 28-32</sup>

In our experience the incidence of CNS complication in patients with AML is about 8% and in most cases the complications are related to leukemic infiltration or bleeding. They are seldom due to infections. An etiological diagnosis of these events is usually achieved on the basis of clinical, radiologic, microbiologic and cytologic procedures. The lack of identification of the cause of death is a disturbing event, especially when it happens in patients in CR.

In our patients the clinical course, the negativity of the microbiologic and radiologic examinations and the neuropathologic findings are compatible with a diagnosis of AHE.

This is the first time that AHE is reported as a neurologic complication in patients with hematologic malignancies. In a recent report<sup>33</sup> five out of 39 (13%) transplanted patients developed CNS involvement, and had a clinical course very similar to that observed in our patients. Unfortunately pathology studies were not performed in any of those patients.

The fact that the clinical course progresses in such a rapid and aspecific way leads us to underestimate the incidence of this pathology. We believe that if physicians paid more attention to the possibility of this complication, especially in patients who have undergone high-dose chemotherapy, there would probably be both a greater possibility of collecting clinical information about the real impact of this dramatic disease and a stronger hope of finding the right treatment for it.

### Contributions and Acknowledgments

We thank Prof. Giorgio Macchi for his enlightening suggestions.

### Funding

This work was financially supported by a grant from the Ministry of University and Scientific and Technological Research (MURST) of Italy.

### Disclosures

Conflict of interest: none.

Redundant publications: no substantial overlapping with previous papers.

### Manuscript processing

Manuscript received October 7, 1998; accepted January 18, 1999.

### References

- Bleyer WA. Central nervous system leukemia. *Ped Clin North Am* 1988; 35:789-814.
- Stewart DJ, Keating MJ, McCredie KB, et al. Natural history of central nervous system acute leukemia in adults. *Cancer* 1981; 47:184-96.
- Marra R, Pagano L, Storti S, Leone G, Accorrà F, Bizzi B. Solid leukemic intracerebral deposits in patients with acute leukemia. *Haematologica* 1986; 71:303-6.
- Iacoangeli M, Roselli R, Pagano L, et al. Intrathecal chemotherapy for treatment of overt meningeal leukaemia: comparison between intraventricular and traditional intralumbar puncture. *Ann Oncol* 1995; 6: 377-82.
- Pagano L, Ricci P, Tonso A, et al. Mucormycosis in patients with haematological malignancies: a retrospective clinical study of 37 cases. *Br J Haematol* 1997; 99:331-6.
- Pagano L, Ricci P, Montillo M, et al. Localization of Aspergillus to the central nervous system among patients with acute leukemia: report of 14 cases. *Clin Infect Dis* 1996; 23:628-30.
- Cordonnier C, Feuillade F, Vernant JP, Marsault C, Rodet M. Cytomegalovirus encephalitis occurring after bone marrow transplantation. *Scand J Haematol* 1983; 31:248-52.
- Graus F, Rogers LR, Posner JB. Cerebrovascular complications in patients with cancer. *Medicine* 1985; 64:14-34.
- Creutzig U, Ritter J, Budde M, Jurgens H, Riehm H, Schellong G. Early death due to hemorrhage and leukostasis in childhood acute myelogenous leukemia. *Cancer* 1987; 60:3071-9.
- Barnard S, Hansen KS. An acute cerebellar syndrome following high-dose chemotherapy and blood cell autotransplant. *Bone Marrow Transplant* 1997; 20: 87-8.
- Barcos M, Lane W, Gomez G, et al. An autopsy study of 1206 acute and chronic leukemias (1958-1982). *Cancer* 1987; 60:827-37.
- Graus F, Sainz A, Sierra J, et al. Neurologic complications of autologous and allogeneic bone marrow transplantation in patients with leukemia: a comparative study. *Neurology* 1996; 46:1004-9.
- Snider S, Bashir R, Bierman P. Neurological complications after high-dose chemotherapy and autologous bone marrow transplantation for Hodgkin's disease. *Neurology* 1994; 44:681-4.
- Cingolani A, De Luca A, Ammassari A, et al. Toxoplasma gondii-DNA detection in cerebrospinal fluid by polymerase chain reaction in the differential diagnosis of AIDS-related focal brain lesion. *J Med Microbiol* 1996; 45:472-6.
- Cingolani A, De Luca A, Larocca LM, et al. Minimally invasive diagnosis of acquired immunodeficiency syndrome-related primary central nervous system lymphoma. *J Natl Cancer Inst* 1998; 90:364-9.
- De Luca A, Cingolani A, Linzalone A, et al. Improved detection of JCV-DNA in cerebrospinal fluid for the diagnosis of AIDS-related progressive multifocal leucoencephalopathy. *J Clin Microbiol* 1996; 34:1343-6.
- Jiwa NM, Van Gemert GW, Raap AK, Van de Rijka FM. Rapid detection of human cytomegalovirus DNA in peripheral blood leukocytes of viremic transplant recipients by the polymerase chain reaction. *Transplantation* 1989; 48:72-6.
- Aurelius E, Johansson B, Skoldenberg B, Staland A, Forsgen M. Rapid detection of herpes simplex encephalitis by nested polymerase chain reaction assay of cerebrospinal fluid. *Lancet* 1991; 337:189-92.
- Mahaligan R, Wellish M, Wolf W, et al. Latent varicella-zoster viral DNA in the human trigeminal and thoracic ganglia. *N Engl J Med* 1990; 323:627-31.
- Cehreli C, Payzin B, Undar B, Yilmaz U, Alakavuklar MN. Paraneoplastic cerebellar degeneration in association with Hodgkin's disease: a report of two cases. *Acta Haematol* 1995; 94:210-3.
- Schlake HP, Husstedt IW, Grottemeyer KH, Potter R. Paraneoplastic subacute cerebellar degeneration in Hodgkin's disease. *Clin Neurol Neurosurg* 1989; 91: 329-39.
- Hurst EW. Acute haemorrhagic leuco-encephalitis: a previously undefined entity. *Med J Austr* 1941; 2:1-6.
- Posey K, Alpert JN, Langford LA, Yeakley JW. Acute hemorrhagic leucoencephalitis: a cause of acute brainstem dysfunction. *South Med J* 1994; 87:851-4.
- Geerts Y, Dehaene I, Lammens M. Acute hemorrhagic leucoencephalitis. *Acta Neurol Belg* 1991; 91:201-11.
- Dangond F, Lacomis D, Schwartz RB, Wen PY, Samuels MA. Acute disseminated encephalomyelitis progressing to hemorrhagic encephalitis. *Neurology* 1991; 41:1697-8.
- Lisak RP, Zweiman B. In vitro cell mediated immunity of cerebrospinal lymphocytes to myelin basic protein in primary demyelinating diseases. *N Engl J Med* 1977; 297:850-3.
- Lisak RP, Beham PO, Zweiman B, Shetty T. Cell mediated immunity to myelin basic protein in acute disseminated encephalomyelitis. *Neurology* 1974; 24: 560-4.
- Fisher RS, Clark AW, Wolinsky JS, Parhad IM, Moses H, Mardiney MR. Postinfectious leucoencephalitis complicating Mycoplasma pneumoniae infection. *Arch Neurol* 1983; 40:109-13.
- Seales D, Greer M. Acute hemorrhagic leucoencephalitis. A successful recovery. *Arch Neurol* 1991; 48:1086-8.
- Mastrodinos B, Barnett GH, Awad IA. Intensive care management of acute hemorrhagic leucoencephalitis with favorable neurologic outcome. *Cleve Clin J Med* 1992; 59:549-52.
- Rosman NP, Gottlieb SM, Bernstein CA. Acute hemorrhagic leucoencephalitis: recovery and reversal of magnetic resonance imaging findings in a child. *J Child Neurol* 1997; 12:448-54.
- Markus R, Brew BJ, Turner J, Pell M. Successful outcome with aggressive treatment of acute haemorrhagic leucoencephalitis. *J Neurol Neurosurg Psychiatry* 1997; 63:551.
- Bavaro P, Di Girolamo G, Di Bartolomeo P, et al. Neurologic complications in allogeneic bone marrow transplantation. *Haematologica* 1998; 83 (suppl 9):57.