Haematologica 1999; 84:260-269 trends in hematology

Thrombotic thrombocytopenic purpura and autoimmunity: a tale of shadows and suspects

CAMILLO PORTA,*# ROBERTO CAPORALI,° CARLOMAURIZIO MONTECUCCO°
*Sezione di Medicina Interna ed Oncologia Medica and Pronto Soccorso ed Accettazione, and °Servizio di Reumatologia, IRCCS Policlinico San Matteo, Pavia, Italy; #Italian Cooperative Group for the study and treatment of TTP

ABSTRACT

Background and Objective. **The key pathogenic feature of TTP is the formation of platelet aggregates within the microcirculation; however, the etiology of such aggregates has been elusive for years. A large amount of evidence points to an abnormal interaction between damaged vascular endothelium and platelets, although the cause of the primary microvascular endothelial cell injury is seldom clear. The autoimmune hypothesis often recurs, and this is based on a number of observations: the claimed superiority of plasma-exchange over plasma infusion, the anecdotal report of the presence of immunocomplexes and autoantibodies in TTP patients, the efficacy of the administration of corticosteroids and other immunosuppressant agents, and the concomitant occurrence of TTP in association with autoimmune diseases, especially systemic lupus erythematosus (SLE). This review will focus on the complex relationships between TTP and humoral autoimmunity; in particular, similarities and differences between TTP, SLE and antiphospholipid (aPL) antibodies syndrome, as well as the putative role of several other antibodies directed towards endothelial cells and/or platelets, including the recently discovered anti-CD36 antibodies and antivWF-cleaving metalloprotease, will be discussed.**

Design and Methods. **The authors have been involved in the study and treatment of TTP and autoimmune diseases for years; furthermore, the PubMed data base of the National Library of Congress has been extensively searched using the Internet.**

Conclusions. **Although over the years evidence has increased in favor of the autoimmune hypothesis for TTP etiopathogenesis, TTP should not yet be considered an autoimmune disease. Autoantibodies should be regarded as only one of the many different insults which can trigger microvascular thrombosis even though the autoimmune theory of the pathogenesis of TTP is gaining more and more strength. As far as concerns the relationship between TTP, SLE and aPL antibodies-related disorders, these diseases should be distinguished on the basis of both different clinical presentations and accurate antibody screening, although this approach should definitely not delay the prompt start of treatment.**
©1999, Ferrata Storti Foundation

Key words: thrombotic thrombocytopenic purpura, autoimmunity

Correspondence: Camillo Porta, M.D., Medicina Interna ed Oncologia Medica, I.R.C.C.S. Policlinico San Matteo, p.le Camillo Golgi, I-27100 Pavia, Italy. Fax: international +39-0382-566223 – E-mail: cporta@tin.it

Thrombotic thrombocytopenic purpura (TTP) is a rare hematologic syndrome first described in 1924 by Eli Moschowitz who used the term *acute pleiochromic anemia with hyaline thrombosis of terminal arterioles and capillaries.*[1] It was Karl Singer, however, who introduced the term TTP, more than twenty years later.[2]

Nowadays, TTP is estimated to occur in about 1 case per million people,[3] with a preference for young women in their thirties; however, over the past decade, the incidence of TTP appears to have increased,[4] presumably due to heightened awareness of the syndrome. An occlusive microangiopathy preferentially localized to terminal arterioles and capillaries (but not usually venules) in the whole body causes the clinical manifestations of TTP, i.e., the presence of microangiopathic schistocytic hemolytic anemia, consumption thrombocytopenia causing severe hemorrhagic diathesis, fluctuating central nervous system abnormalities, fever and renal impairment of different degrees.[1]

However, the classic pentad of symptoms described above is observed in only about 40% of TTP patients, with renal symptoms being observed in as few as 38% of patients in our country,[5] while the triad of anemia, thrombocytopenia and bizarre neurologic abnormalities can be observed in up to 75% of patients.[3] It has, therefore, been proposed that TTP should be redefined as a syndrome of Coombs' negative microangiopathic hemolytic anemia and thrombocytopenia in the absence of other possible causes of these manifestations.[6,7]

The key pathogenic feature of TTP is the formation of platelet aggregates; however, the etiology of such aggregates has been elusive and controversial for years. Several recent studies point to abnormal interaction between damaged vascular endothelium and platelets,[8] although other investigators found different platelet aggregating plasma proteins of the family of cysteine proteinases,[9,10] at times thought to be cathepsin-L[10,11] or calpain.[12] As a matter of fact, the hypothesis of endothelial damage is supported by several experimental findings: abnormal production and metabolism of von Willebrand factor (vWF) multimers, with ultra-large vWF multimers, capable of increasing platelet adhesiveness *in vitro*, shed into the circulation by endothelial cells,[13] reduced vascular prostacyclin (PGI_2) production,[14] impaired fibri-

©Ferrata Storti Foundation

nolytic activity,[15] increased vascular endothelial cell markers in blood,[16] and pro-apoptotic effects of TTP plasma on microvascular endothelial cells *in vitro*.[17]

Despite the presence of a number of ill-defined secondary TTP (or thrombotic microangiopathies if one also include the closely-related hemolytic uremic syndrome, HUS) (Table 1), the cause of the primary microvascular endothelial cell injury is seldom clear, especially in the vast majority of TTP cases, the idiopathic ones. An autoimmune hypothesis explaining the primary cause of endothelial damage often recurs.[18] The hypothesis is based on many observations: a) the superiority of plasma-exchange over plasma infusion in the treatment of TTP[7] – although still debated by some authors – suggests the possibility that removing a possible humoral pathogenetic factor may be more effective than administering a possibly lacking factor;[19] b) immunocomplexes and several autoantibodies were anecdotally reported as pathogenetic factors in TTP;[20-24] c) some TTP patients seem to be cured by the administration of corticosteroids[24] and other immunosuppressant agents such as vincristine,[25] cyclophosphamide,[26] azathioprine;[27] d) TTP may occur in association with autoimmune diseases, especially systemic lupus erythematosus (SLE) (reviewed in ref. #28) and the differential diagnosis between TTP and SLE is particularly difficult.

This review will focus on the complex relationships between TTP and humoral autoimmunity; in particular, similarities and differences between TTP, SLE and antiphospholipid (aPL) antibodies syndrome, as well as the putative role of several antibodies directed towards endothelial cells, platelets, and/or plasma proteases, will be discussed.

Table 1. Proposed, simplified classification of the thrombotic microangiopathies (TTP and HUS).

TTP/HUS	
Idiopathic	
Malignancy-associated	
Drug-associated:	standard-dose chemotherapy agents; high-dose chemotherapy agents given as induction within bone marrow transplantation procedures; immunosuppressants given after transplantation; estroprogestins; D-penicillamine; others;
Pregnancy and post-partum-associated	
Autoimmune-associated:	SLE; RA; Sjögren's syndrome; mixed connective tissue disease; scleroderma; adult onset Still's disease; polymyositis; myasthenia gravis;
Infection-associated:	enterotoxin-producing *E-Coli* strains; others

TTP, SLE, and antiphospholipid antibodies

Biological viewpoint

It is well known that SLE and related diseases may present with recurrent thromboses and thrombocytopenia[28] that are usually associated with aPL autoantibodies detected by either lupus anticoagulant test, false positive serologic tests for syphilis or solid phase immunosorbent assay.[29,30] aPL antibodies bind to anionic phospholipids, such as phosphatidylserine, which are important constituents of the platelet and cell membrane, even though, under normal conditions, these are concentrated within the inner leaflet of the phospholipid bilayer. aPL antibodies are known to need a co-factor to bind to platelets and to endothelial cells;[31,32] most often this is β_2-glycoprotein-I (β_2-GP-I),[33,34] although prothrombin, protein C and protein S are alternative targets of aPL antibodies.[35] Shi *et al.*[36] studied the effect of aPL antibodies on platelet aggregation to physiologic stimuli without showing any major influence. However, other investigators showed that monoclonal antibodies to β_2-GP-I possess lupus anticoagulant properties and strongly potentiated the platelet aggregation response to adrenaline or ADP when β_2-GP-I was present.[37] This effect was shown to be dependent upon a secondary interaction of the Fc fragment of the antibody with the platelet FcgRII receptor, suggesting a platelet activation mechanism comparable to that seen in heparin-induced thrombocytopenia.[38]

Since endothelium seems to play a key role in the pathogenesis of both TTP and SLE, some attention has recently been devoted to the endothelial production of nitric oxide (NO) which, together with PGI_2 and lipoxygenase products, contributes to maintaining normal endothelial non-thrombogenicity.

As a matter of fact, under normal conditions, the shear stress-induced release of NO continuously causes relaxation of vascular smooth muscle cells and contributes to the prevention of platelet adhesion and aggregation in normal blood vessels;[39] furthermore, substances with strong vasoconstrictor properties (serotonin, ADP, thromboxane A_2 and platelet aggregating factor), secreted by aggregating thrombocytes, are potent releasers, through the interaction with specific receptors on endothelial cells, of NO which counteracts their action.[40] In TTP and/or aPL antibodies-related conditions, impaired NO release might thus be postulated, as has already been demonstrated to occur in pre-eclampsia,[41] a condition in which endothelial cell damage plays a key role.

However, recent results seem to suggest that NO is not implicated in the pathogenesis of these diseases,

©Ferrata Storti Foundation

since plasma concentrations of nitrates (a sensitive index of NO production) identical to those of normal healthy volunteers were titered in idiopathic TTP patients, in aPL antibodies-positive and negative SLE patients, and in primary aPL antibodies syndrome patients.[42,43]

More in general, the occurrence of thromboses in patients with autoimmune diseases appears to be multifactorial, several mechanisms having been proposed at times to contribute to the disruption of homeostasis between the normal procoagulant and anticoagulant pathways. The production of autoantibodies that a) bind to coagulation factors or counter-regulatory proteins, b) cause endothelial cell injury or activation, c) bind directly to platelets, d) impair fibrinolysis, e) inhibit PGI_2 production, or determine an imbalance between PGI_2/thromboxane ratio, may act as triggering events for abnormal coagulation.[28,29]

Clinical viewpoint

Besides having in common possible pathogenetic events, in particular, endothelial cell injury, TTP and SLE also have several clinical findings in common - i.e., fever, central nervous system symptoms, renal disease and hemolytic anemia which is autoimmune in SLE and microangiopathic in TTP (the hematologic characteristics of TTP, SLE and primary aPL antibodies syndrome are compared in Table 2); thus, a patient with thrombotic thrombocytopenia plus the above symptoms should be carefully examined to differentiate between TTP and aPL antibodies-positive SLE.

Idiopathic TTP is usually not related to aPL; indeed, even though some authors have made a diagnosis of TTP even in the presence of aPL antibodies, our experience strongly supports the evidence that anticardiolipin antibodies and other SLE-related autoantibodies, such as anti-β_2-GP-I antibodies (Figure 1), are absent in TTP patients.[44,45]

The possible, but rare, association between TTP and SLE complicates the picture further.

Table 2. Comparison of the hematologic characteristics of TTP, SLE and primary aPL antibodies syndrome.

Hematologic characteristic	*TTP*	*SLE*	*Primary aPL syndrome*
Thrombocytopenia	consumptive (microangiopathic)	immune-mediated	immune-mediated
Microangiopathic hemolytic anemia	present	absent	absent
Schistocytes	present	rare	absent
aPL antibodies	absent	variable	present at high titer

To our knowledge, more than 30 cases of TTP occurring in SLE patients have been reported in the literature to date.[28]

An intriguing question is whether aPL antibodies may have a role in the development of TTP in SLE patients. Several TTP cases have been reported in SLE patients with positive aPL assay;[46,47] furthermore, aPL were found in a few cases of post-partum HUS.[48] This has led to the suggestion that these antibodies have a pathogenic role in platelet aggregation and/or endothelial damage causing TTP. However, as outlined before, our own experience clashes with this viewpoint. Indeed, if we take into account that aPL are present in up to 50% of SLE patients,[49,50] a positive aPL assay could be expected in one half of patients with SLE-associated TTP, independently of any pathogenic role in the latter disorder.

Traditional estimates of the diagnosis of TTP in SLE patients range from 1% to 4%,[28,51] although *post-mortem* examination of SLE patients suggests that this association may be present in a significantly higher percentage of SLE patients succumbing to multiorgan system failure.[52] In Italy, we first found 4 cases of SLE (all aPL-negative) in 103 TTP patients gathered by the Italian Cooperative Group for TTP – i.e. an incidence of 3.8%,[53] but the rate now appears even lower – 2.28%, since no SLE cases were recorded in 72 more TTP patients enrolled in a national multicenter trial.[54]

The diagnosis of SLE usually precedes that of TTP, even though cases of TTP preceding or occurring simultaneously with the diagnosis of SLE have also been reported; TTP may present in clinically quiescent SLE, or else complicate an active SLE.[28] The different pattern of association of the two diseases obviously determines the optimal treatment approach; thus, TTP episodes developing in quiescent SLE patients should be treated as *de novo* TTP cases, while, in concomitant TTP and active SLE, treatment should be directed at both conditions. Granted that plasma-exchange (with or without antiplatelet drugs and/or steroids) is the treatment of choice for TTP, corticosteroids with or without a second-line agent such as cyclophosphamide, remain the treatment of choice for active life-threatening SLE and should be utilized along with plasma-exchange in the proper clinical setting.

A procedure which may theoretically be useful to treat this rare association is the perfusion of autologous plasma over filters containing staphylococcal protein-A covalently bound to polyacrylamide beads.[55] This treatment has already proved to be effective in the treatment of TTP induced by antineoplastic drugs,[56] another rare kind of secondary TTP.[57]

In conclusion, even though the concomitant presence of TTP, SLE and aPL antibodies in the same patient is possible, there is no evidence, to date, that aPL antibodies play any pathogenic role in TTP, even in SLE patients.

©Ferrata Storti Foundation

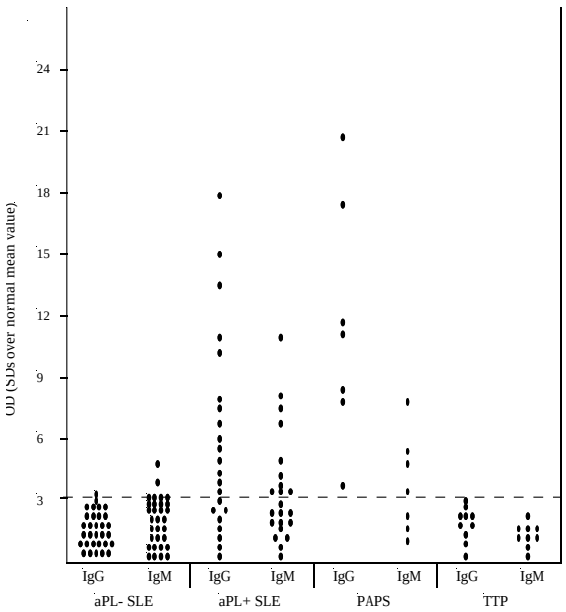

Figure 1. Anti-β_2-glycoprotein-I (anti-β_2-GP-I) antibodies in 31 antiphospholipid antibodies-negative SLE (aPL$^-$ SLE), 22 antiphospholipid antibodies-positive (aPL$^+$ SLE) SLE, 7 primary antiphospholipid syndrome (PAPS), and 10 thrombotic thrombocytopenic purpura (TTP) patients. Anti β_2-GP-I antibodies were detected using a sensitive immunosorbant assay, as described by Del Papa *et al.*[31] The upper normal limit was considered as the optical density (OD) mean value of 15 control subjects ± 3 standard deviations (SDs).

TTP and other autoantibodies

Antineutrophil cytoplasmic antibodies (ANCA)

Several experimental data support the hypothesis that neutrophils participate in the pathophysiology of hemolytic-uremic syndrome (HUS),[58-60] a syndrome which shares so many similarities with TTP that many authors consider TTP and HUS only qualitatively different expressions of a unique physiopathologic entity.[14] Recently, Rollino *et al*. found the serum of one HUS patient (of 4 tested) positive for both anti-proteinase 3 (PR3-Abs, or C-ANCA) and anti-myeloperoxidase (MPO-Abs, or P-ANCA) antibodies and thus hypothesized the participation of ANCA (which can cause endothelial cell damage through different mechanisms), together with anti-elastase antibodies, in the pathophysiology of HUS, at least in certain patients.[61] Since it is theoretically possible that neutrophils could initiate, via ANCA-induced degranulation and free radical production, the endothelial damage that ultimately leads to the clinical pattern of acute TTP, even without leaving any clear evidence of their involvement behind, our Group tested the sera from 29 acute phase TTP patients for the presence of ANCA. The absence of ANCA in the sera of our patients[62] seems to exclude their involvement in the pathogenesis of TTP. Moreover, even in HUS, the participation of ANCA in the etiopathogenesis of this disease seems far from convincing, especially in the light of an earlier study demonstrating the absence of ANCA in the sera of 27 HUS patients.[63] Furthermore, the concomitant C-ANCA and P-ANCA positivity reported by Rollino *et al*. in a single patient[61] could be a casual association, since vasculitis patients hardly ever have both types of antibodies,[64,65] as would be expected if the autoantibody formation was a secondary phenomenon.

Anti-factor VIII antibodies

The case of a male patient with long-standing hairy cell leukemia under interferon-α treatment who developed anti-factor VIII antibodies and recurrent TTP has been recently described.[66] Despite the fact that, to our knowledge, this is the only case of anti-factor VIII antibodies in TTP reported to date in the literature, some interesting observations may be extrapolated from this patient.

Hairy cell leukemia has been associated with several autoimmune phenomena, but never with TTP or with the development of anti-factor VIII autoantibodies, the latter being most often seen in patients with hemophilia A treated with factor replacement therapy, or in otherwise healthy elderly subjects.[56] Conversely, the development of a vast array of autoimmune phenomena and diseases may follow and complicate interferon treatment;[67] furthermore, interferon-induced damage to microvascular endothelial cells has been demonstrated *in vivo*.[68]

Even though the authors of this case report stressed that the involvement of interferon-α in the development of both anti-factor VIII antibodies and TTP could only be postulated and not unquestionably proved, this original report seems once again to highlight the central role of endothelial damage in the pathogenesis of TTP, while the nature of the antibodies insulting microvascular endothelial integrity, leading to TTP, seems less important.

Antiplatelet antibodies

Antiplatelet antibodies in TTP patients[69-72] and, more often, patients showing, at different times during their clinical history, both ITP and TTP have been described in the literature,[72-77] and a case of concomitant TTP and autoimmune anemia has also been reported.[73] However, many of the above cases could be (and have been) criticized, since the classic criteria to diagnose TTP were seldom present, meaning that the disease described might have been, in at least some of the reported cases, simply Evans' syndrome – i.e., the association of autoimmune anemia and thrombocytopenia;[78] even the microscopy observation of schistocytes in peripheral blood smears is not sufficient in these cases, since subclinical erythrocyte fragmentation has been proved in nearly all ITP patients.[78,79] Currently, the established criteria to diagnose TTP require the absence of other causes responsible for both anemia and thrombocytope-

©Ferrata Storti Foundation

nia,[6,7,54] thus including antiplatelet antibodies. Unfortunately, the present methodology used to measure these antibodies is still affected by a high rate of false negative and false positive results; therefore, the risk of misdiagnosing a case of TTP because of the presence of false positive anti-platelet antibodies should also be considered.

On the other hand, the presence of antiplatelet antibodies cannot be used, *per se*, to rule out SLE or aPL antibodies-related conditions; as a matter of fact, a French group has recently suggested that antibodies directed against major platelet membrane glycoproteins, such as glycoprotein IIb-IIIa and glycoprotein Ib-IX, are present in a great number of patients with SLE and primary aPL antibodies syndrome,[80] probably playing a role in the development of the thrombocytopenia observed in the above diseases.

Anti-endothelial cell antibodies

The hypothesis of endothelial cell injury by anti-endothelial cell antibodies in TTP patients, leading to the overt syndrome, dates back to 1988, when Leung *et al*. demonstrated these antibodies, both of the IgG and IgM types, in 3 of 5 adult TTP patients and in 13 of 14 children with the classic – i.e., pediatric, HUS.[21] Since immunofluorescence, ELISA, and complement-fixation techniques might fail to detect antibodies against antigenic sites which are either inaccessible or not displayed in recognizable cellular structures, Koenig *et al.* subsequently demonstrated, using Western blot analysis, some antibodies binding to human renal microvascular cell proteins. The most important antigen was a 43 KDa one, found in 13 of 14 and 4 of 5 TTP and HUS patients, respectively;[22] subcellular fractionation localized these antigens to cytosolic and nuclear compartments,[22] thus confirming the initial hypothesis. Unfortunately, to our knowledge, this interesting research vein has not been exploited further.

Anti-CD36 antibodies

More recently, much experimental attention has been devoted to CD36 (also known as glycoprotein IV [gpIV]), a membrane antigen occurring in platelets, endothelial cells, reticulocytes, monocytes, and other cells and tissues.[81,82] Interestingly, CD36 expression in endothelial cells is characteristically restricted to capillary endothelial cells and is not seen in the endothelia of large vessels;[83,84] furthermore, monoclonal antibodies directed against CD36 have been demonstrated to induce platelet activation[85] and, most important, this glycoprotein has already been demonstrated to be the receptor of p37, a platelet agglutinating protein[86,87] previously isolated and purified from the plasma of TTP patients.[88,89]

©Ferrata Storti Foundation

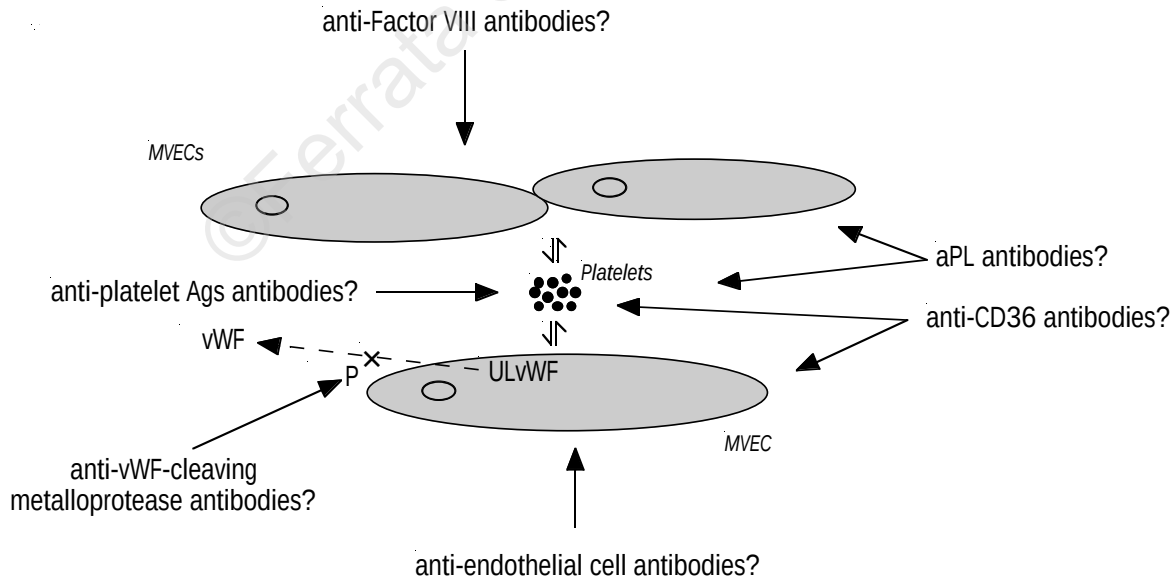

Figure 2. TTP is currently considered as the clinical result of an abnormal interaction between microvascular endothelium and platelets. As shown in this picture, several autoantibodies may interact with microvascular endothelial cells (MVECs), platelets and/or the vWF-cleaving proteases, leading alternatively to a primary endothelial damage followed by enhanced platelet aggregation, or to an enhanced platelet aggregation, followed by subsequent endothelial damage.
ULvWF: ultra-large vWF multimers; P: vWF-cleaving metalloproteases.

In 1994, using an accurate and elegant experimental design, Tandon *et al*. demonstrated that antibodies directed against CD36 occur in about 80% of TTP patients.[23] The authors reasoned that these antibodies might be part of a spectrum of autoantibodies arising from immune system hyperactivity or in response to membrane changes in TTP patients, leaving the fundamental question open: is it the endothelial cell damage (in this case due to an autoimmune reaction) leading to abnormal platelet aggregation, or a primary platelet aggregation causing endothelial damage and consequently an autoimmune response directed against endothelial cell antigen (Figure 2), which is central in TTP etiopathogenesis?

Interestingly, more and more pieces of evidence suggest the involvement of anti-CD36 autoantibodies in the pathogenesis of thrombotic complications in patients with lupus anticoagulant but not SLE,[90] active SLE with[80] or without aPL antibodies,[91] and thrombotic complications with recurrent fetal loss but neither SLE, nor aPL antibodies or TTP,[92] which further complicates the complex relationships between SLE and TTP. However, these results should be confirmed on larger case series for better characterization of the specificity of CD36 antibodies in different diseases.

Breaking news: antibodies against von Willebrand factor cleaving metalloprotease

vWF, whose unusually large multimers were proposed as the agglutinating substance responsible for platelet aggregation under high intravascular shear stress conditions in TTP patients,[13] is secreted by endothelial cells as an extra large polymer of a polypeptide joined by disulfide bonds.[93] Subsequently, this extra large polymer is physiologically cleaved in the circulation between tyrosine at position 842 and methionine at position 843 by a 200-Kd plasma metalloprotease into smaller, functionally low-adhesive dimers of 176-Kd and 140-Kd, respectively.[94-97]

A severe deficiency of this protease was found in the plasma of 4 patients with chronic relapsing TTP,[98] while in another patient with recurrent TTP, both a deficiency of protease activity and an autoantibody against the same vWF-cleaving protease was described.[99]

Very recently, Tsai and Lian in New York and Furlan *et al.* in Switzerland, independently found little – if any – plasma vWF-cleaving metalloprotease activity during acute TTP episodes (with a return to baseline values at disease recovery), together with an IgG autoantibody directed against components of the enzyme, which accounted for the above lack of metalloprotease activity;[100,101] the above findings were consistent between the two studies and were observed on a significative number of TTP patients.

Furthermore, the study by Furlan *et al.*[100] provide an useful tool to distinguish TTP from HUS, an extremely controversial topic, especially between hematologists and nephrologists; indeed, TTP patients had little or no vWF-cleaving metalloprotease activity in plasma, whereas the enzyme was normal or nearly so in patients considered to have familial or acquired HUS,[100] a finding which can also explain why PE therapy, which is so effective in treating TTP patients, yields disappointing results in patients with acquired HUS.[102]

These intriguing findings seem to add another – relevant – brick in the construction of an autoimmune theory for the pathogenesis of TTP, even though, as stressed by Moake in his editorial accompanying the metalloprotease papers, TTP is only *less of a mystery*, but still a mystery.

TTP and other autoimmune diseases

Rare case reports have dealt with the association of TTP with a vast array of autoimmune diseases, such as rheumatoid arthritis, Sjögren's syndrome, mixed connective tissue disease, scleroderma, polymyositis, adult onset Still's disease, and myasthenia gravis.[28] However, in some of the above cases, the development of TTP may have been related to factors other than the underlying autoimmune disease, such as infections or medications;[28] in particular, three of the patients with TTP and rheumatoid arthritis developed TTP during D-penicillamine treatment for the autoimmune disease.[103-105] These TTP cases should, therefore, be considered as drug-, and not autoimmunity-related, since D-penicillamine, a drug characterized by an impressive array of adverse reactions including thrombocytopenia, leukopenia, bone marrow aplasia and renal function impairment, occasionally also causes classic TTP,[106] or TTP-like episodes.[107] Unfortunately, the biological mechanisms underlying the development of TTP in each autoimmune condition was not investigated in these rare cases, so that the above reports are of anecdoctal interest only.

Conclusions

The extreme rarity of TTP makes it difficult both to perform clinical trials in these patients and to study the biological pathophysiology of the disease itself. Indeed, basic research on TTP has been limited until recently by the scarcity of both patients and biological samples; furthermore, the aggressivenes of this life-threatening disease often impels physicians to start treatment immediately (frequently using corticosteroids), which may interfere with subsequent biological investigations.

Even though over the years evidence has increased in favor of the autoimmune hypothesis for the etiopathogenesis of TTP, TTP should not yet be considered an autoimmune disease. Further insights into the biology of anti-CD36 antibodies, and anti-vWF cleaving protese, could radically change this point of view in the future.

At present, autoantibodies should be regarded as

only one of the many different insults which can cause endothelial damage or abnormal platelet aggregation, thus triggering microvascular thrombosis with all its consequences - i.e., platelet consumption leading to hemorrhagic diathesis, erythrocyte fragmentation with consequent anemia, thrombotic and/or ischemic complications in different organs or tissues.

As already stressed within this review, TTP, SLE and aPL antibodies-related disorders should be distinguished on the basis of both different clinical presentation (through an accurate search for commonly accepted diagnostic criteria for one or other condition) and on the basis of accurate antibody screening; thus, we believe that the presence of aPL autoantibodies should give evidence against a diagnosis of TTP; however, this is clearly not a categorical statement, since we cannot exclude that aPL antibodies may, in a minority of patients, be associated with a primary endothelial damage ultimately resulting in overt TTP.

Despite the undoubted and repeatedly stressed utility of accurate antibody screening emerging from this review, if a patient presents with the clinical triad (or indeed the classic pentad) of symptoms and signs suggestive of TTP, it would certainly be considered malpractice not to start plasma-exchange as soon as technically possible; indeed, if one was to wait for antibody titers to return (which could take days in some institutions) to confirm or exclude the diagnosis of TTP, mortality rates would return to the dismal rates noted before the institution of plasma-exchange therapy. A prompt execution of plasma-exchange has been demonstrated to be a key element in determining treatment success.[5]

Contributions and Acknowledgments

All three authors contributed equally to the writing of the manuscript.

Disclosures

Conflict of interest: none.

Redundant publications: no substantial overlapping with previous papers.

Manuscript processing

Manuscript received August 17, 1998; accepted November 25, 1998.

References

1. Moschkowitz E. Hyaline thrombosis of the terminal arterioles and capillaries: a hitherto undescribed disease. Proc NY Pathol Soc 1924; 24:21-4.
2. Singer K, Bornstein FP, Wile SA. Thrombotic thrombocytopenic purpura. Hemorrhagic diathesis with generalized platelet thromboses. Blood 1947; 2:542-4.
3. Ridolfi RL, Bell WR. Thrombotic thrombocytopenic purpura. Medicine 1981; 60:413-28.
4. Torok TJ, Holman RC, Chorbat L. Increasing mortality from thrombotic thrombocytopenic purpura in the United States: analysis of national mortality data 1968-1991. Am J Hematol 1995; 50:84-90.
5. Bobbio-Pallavicini E, Porta C, Fornasari PM, Viarengo GL, Ascari E. Thrombotic thrombocytopenic purpura (TTP): retrospective study on 84 patients and therapeutical prospects. Transfus Sci 1992; 13:39-44.
6. Murphy WG, Moore JC, Warkentin TE, Hayward EP, Kelton JG. Thrombotic thrombocytopenic purpura. Blood Coagul Fibrinolysis 1992; 3:655-9.
7. Rock GA, Shumak KH, Buskard NA, et al. Comparison of plasma-exchange with plasma-infusion in the treatment of thrombotic thrombocytopenic purpura. N Engl J Med 1991; 325:393-7.
8. Rose M, Rowe JM, Eldor A. The changing course of thrombotic thrombocytopenic purpura and modern therapy. Blood Rev 1993; 7:94-103.
9. Murphy WG, Moore JC, Kelton JG. Relationship between platelet aggregating factor and von Willebrand factor in thrombotic thrombocytopenic purpura. Blood 1987; 70:1683-7.
10. Falanga A, Consonni R, Ruggenenti P, Barbui T. A cathepsin-like proteinase activity in thrombotic thrombocytopenic purpura. Br J Haematol 1991; 79:474-80.
11. Consonni R, Falanga A, Barbui T. Further characterization of platelet-aggregating cysteine proteinase activity in thrombotic thrombocytopenic purpura. Br J Haematol 1994; 87:321-4.
12. Kelton JG, Moore JC, Warkentin TE, Hayward CP. Isolation and characterization of cysteine proteinase in thrombotic thrombocytopenic purpura. Br J Haematol 1996; 93:421-6.
13. Moake JL. Studies on the pathophysiology of thrombotic thrombocytopenic purpura. Semin Hematol 1997; 34:83-9.
14. Remuzzi G, Imberti L, De Gaetano G. Prostacyclin deficiency in thrombotic microangiopathies. Lancet 1981; 2:1422-3.
15. Kwaan HC. Role of fibrinolysis in thrombotic thrombocytopenic purpura. Semin Hematol 1987; 24:71-81.
16. Wada H, Kaneko T, Ohiwa M, et al. Increased levels of vascular endothelial cell markers in thrombotic thrombocytopenic purpura. Am J Hematol 1993; 44:101-5.
17. Laurence J, Mitra D, Steiner M, Staiano-Coico L, Jaffe E. Plasma from patients with idiopathic and human immunodeficiency virus-associated thrombotic thrombocytopenic purpura induces apoptosis in microvascular endothelial cells. Blood 1996; 87:3245-57.
18. Neame PB. Immunologic and other factors in thrombotic thrombocytopenic purpura (TTP). Semin Thromb Hemost 1980; 6:416-29.
19. Centurioni R, Bobbio-Pallavicini E, Porta C, et al. Treatment of thrombotic thrombocytopenic purpura with high-dose immunoglobulins. Results in 17 patients. Haematologica 1995; 80:325-31.
20. Burns ER, Zucker-Franklin D. Pathologic effects of plasma from patients with thrombotic thrombocytopenic purpura on platelets and cultured vascular endothelial cells. Blood 1982; 60:1030-7.
21. Leung DY, Moake JL, Havens PL, Kim M, Pober JS. Lytic anti-endothelial cell antibodies in haemolytic-uraemic syndrome. Lancet 1988; 23:183-6.
22. Koenig DW, Barley-Maloney L, Daniel TO. A Western blot assay detects autoantibodies to cryptic endothelial antigens in thrombotic microangiopathies. J Clin Immunol 1993; 13:204-11.
23. Tandon NN, Rock G, Jamieson GA. Anti-CD36 antibodies in thrombotic thrombocytopenic purpura. Br J Haematol 1994; 88:816-25.
24. Gorini M, Luliri P. Steroids: what role in TTP? Trans-

©Ferrata Storti Foundation

fus Sci 1992;13:73-6.
25. Bobbio-Pallavicini E, Porta C, Centurioni R, et al. Vincristine sulfate for the treatment of thrombotic thrombocytopenic purpura refractory to plasma-exchange. Eur J Haematol 1994; 52:222-6.
26. Bird JM, Cummins D, Machin SJ. Cyclophosphamide for chronic relapsing thrombotic thrombocytopenic purpura [letter]. Lancet 1990; i:565-6.
27. Moake JL, Rudy CK, Troll JH, et al. Therapy of chronic relapsing thrombotic thrombocytopenic purpura with prednisone and azathioprine. Am J Hematol 1985; 20:73-9.
28. Fessler BJ. Thrombotic syndromes and autoimmune diseases. Rheum Dis Clin N Am 1997; 23:461-79.
29. Esmon NL, Smirnov MD, Esmon CT. Lupus anticoagulant and thrombosis: the role of phospholipids. Haematologica 1997; 82:474-7.
30. Khamashta MA, Hughes GRV. Antiphospholipid antibodies and antiphospholipid syndrome. Curr Opin Rheumatol 1995; 7:389-94.
31. Del Papa N, Guidali L, Sala A, et al. Endothelial cells as the target for antiphospholipid antibodies. Human polyclonal and monoclonal anti-beta2-glycoprotein-I antibodies react in vitro with endothelial cells through adherent β2-glycoprotein-I and induce endothelial activation. Arthritis Rheum 1997; 40:551-61.
32. Del Papa N, Raschi E, Catelli L, et al. Endothelial cells as target for antiphospholipid antibodies: role of anti-β2-glycoprotein-I antibodies. Am J Reprod Immunol 1997; 38:212-7.
33. McNeil HP, Simpson RJ, Chesterman CN, Krilis SA. Anti-phospholipid antibodies are directed against a complex antigen that includes a lipid-binding inhibitor of coagulation: β2-glycoprotein I (apolipoprotein H). Proc Natl Acad Sci USA 1880; 87:4120-4.
34. Roubey RA. Autoantibodies to phospholipid-binding plasma proteins: a new view of lupus anticoagulants and other "antiphospholipid" autoantibodies. Blood 1994; 84:2854-67.
35. Osoting JD, Derksen RHWM, Bobbink IWG, Hackeng TM, Bouma BN, De Groot PG. Antiphospholipid antibodies directed against a combination of phospholipid with prothrombin, protein C, or protein S: an explanation for their pathogenic mechanism? Blood 1993; 81:2618-25.
36. Shi W, Chong BH, Chesterman CN. β2-glycoprotein I is a requirement for anticardiolipin antibody binding to activated platelets: differences with lupus anticoagulants. Blood 1993; 81:1255-62.
37. Arvieux J, Roussel B, Pouzol P, Colomb MG. Platelet activating properties of murine monoclonal antibodies to β2-glycoprotein I. Thromb Haemost 1993; 70: 336-41.
38. Arnout J. The pathogenesis of the antiphospholipid syndrome: a hypothesis based on parallelism with heparin-induced thrombocytopenia. Thromb Haemost 1996; 75:536-41.
39. Vane JR, Botting RM. Endothelium-thromboresistance. Wien Klin Wochenschr 1991; 103:403-4.
40. Vanhoutte PM, Eber B. Endothelial-derived relaxing and contracting factors. Wien Klin Wochenschr 1991; 103:405-11.
41. Seligman SP, Buyon JP, Clancy RM, Young BK, Abramson SB. The role of nitric oxide in the pathogenesis of preeclampsia. Am J Obstet Gynecol 1994; 171:944-8.
42. Porta C, Buggia I, Bonomi I, Caporali R, Scatola C, Montecucco C. Nitrite and nitrate plasma levels, as markers of nitric oxide synthesis, in antiphospholipid antibodies-related conditions and in thrombotic thrombocytopenic purpura [letter]. Thromb Haemost 1997; 78:965-7.
43. Porta C, Buggia I, Bonomi I, et al. Nitrite and nitrate plasma levels, as markers for nitric oxide synthesis, in thrombotic thrombocytopenic purpura (TTP). A case-control study. Hematology 1996; 1:239-46.
44. Montecucco C, Di Lauro M, Bobbio-Pallavicini E, et al. Anti-phospholipid antibodies and thrombotic thrombocytopenic purpura. Clin Exp Rheumatol 1987; 5:355-8.
45. Caporali R, Choucair J, Bobbio-Pallavicini E, Porta C, Montecucco C. Autoantibody profile in thrombotic thrombocytopenic purpura. Transfus Sci 1992; 13:33-6.
46. Jain R, Chartash E, Susin M, Furie R. Systemic lupus erythematosus and thrombotic microangiopathies. Semin Arthritis Rheum 1994; 24:173-82.
47. Itoh Y, Sekine H, Hosono O, et al. Thrombotic thrombocytopenic purpura in two patients with systemic lupus erythematosus: clinical significance of antiplatelet antibodies. Clin Immunol Immunopathol 1990; 57:125-36.
48. Huang JJ, Chen MW, Sung JM, Lan RR, Wang MC, Chen FF. Post-partum hemolytic uraemic syndrome associated with antiphospholipid antibody. Nephrol Dial Transplant 1998; 13:182-6.
49. Montecucco C, Longhi M, Caporali R, De Gennaro F. Hematological abnormalities associated with anticardiolipin antibodies. Haematologica 1989; 74:195-204.
50. Ames PRJ, Khamashta MA, Hughes GRV. Antiphospholipid syndrome. In: Schur PH, ed. The clinical management of systemic lupus erythematosus. 2nd ed. Philadelphia, Lippincott-Raven, 1996. p. 211-24.
51. Pistiner M, Wallace DJ, Nessim S, Metzger AL, Klinenberg JR. Lupus erythematosus in the 1980s: a survey of 570 patients. Semin Arthritis Rheum 1991; 21:55-64.
52. Devinsky O, Petito CK, Alonso DR. Clinical and neuropathological findings in systemic lupus erythematosus: the role of vasculitis, heart emboli, and thrombotic thrombocytopenic purpura. Ann Neurol 1988; 23:380-4.
53. Porta C, Bobbio-Pallavicini E, Centurioni R, Tacconi F, Caporali R, Montecucco CM. Thrombotic thrombocytopenic purpura in systemic lupus erythematosus [letter]. J Rheumatol 1993; 20:1625-6.
54. Bobbio-Pallavicini E, Gugliotta L, Centurioni R, et al. Antiplatelet agents in thrombotic thrombocytopenic purpura (TTP). Results of a randomized multicenter trial by the Italian Cooperative Group for TTP. Haematologica 1997; 82:429-35.
55. Fox DA, Faix JD, Coblyn J, Fraser P, Smith B, Weinblatt ME. Thrombotic thrombocytopenic purpura and systemic lupus erythematosus. Ann Rheum Dis 1986; 45:319-22.
56. Gordon LI, Kwaan HC. Cancer- and drug-associated thrombotic thrombocytopenic purpura and hemolytic uremic syndrome. Semin Hematol 1997; 34:140-7.
57. Antman K, Skarin A, Mayer R. Microangiopathic hemolytic anemia and cancer: a review. Medicine 1979; 58:377-84.
58. Forsyth KD, Simpson A, Fitzpatrick MM, Barratt TM, Levinsky RJ. Neutrophil-mediated endothelial injury in hemolytic-uremic syndrome. Lancet 1989; i:411-4.
59. Bolande RP, Kaplan BS. Experimental studies on the hemolytic-uremic syndrome. Nephron 1985; 39:228-36.
60. Millford D, Taylor CM, Rafaat F, Halloran E, Dawes J. Neutrophil elastases and haemolytic-uraemic syndrome [letter]. Lancet 1989; ii:1153.
61. Rollino C, Roccatello D, Menegatti E, Piccoli G. Anti-neutrophil cytoplasm and antielastase antibodies in hemolytic-uremic syndrome [letter]. Nephron 1993; 65:320-1.

62. Porta C, Caporali R, Montecucco C, Bobbio-Pallavicini E on behalf of the Italian Cooperative Group for TTP. Lack of evidence of antineutrophil cytoplasmic antibodies involvement in the acute phase of thrombotic thrombocytopenic purpura [letter]. Nephron 1996; 73:352-3.
63. Olavarria F, Mezzano S, Valderrama G. Detection of antineutrophil cytoplasmic antibodies in the classic form of hemolytic uremic syndrome [letter]. Nephron 1994; 66:235.
64. Niles JL. Value of test for antineutrophil cytoplasmic antibodies in the diagnosis and treatment of vasculitis. Curr Opin Rheumatol 1993; 5:18-24.
65. Montecucco C. Role of ANCA in the pathogenesis of Wegener's granulomatosis: a short review. Monaldi Arch Chest Dis 1994; 49:323-6.
66. Moses J, Lichtman SM, Brody J, Wisch N, Moake JL. Hairy cell leukemia in association with thrombotic thrombocytopenic purpura and factor VIII antibodies. Leuk Lymphoma 1996; 22:351-4.
67. Conlon KC, Urba WJ, Smith JW, Steis RG, Longo DL, Clark JW. Exacerbation of symptoms of autoimmune disease in patients receiving alpha-interferon therapy. Cancer 1990; 65:2237-42.
68. Dvorak HF, Gresser I. Microvascular injury in the pathogenesis of interferon-induced necrosis of subcutaneous tumors in mice. J Natl Cancer Inst 1989; 81:497-502.
69. Tada T, Kishimoto H. An autopsy case of thrombotic thrombocytopenic purpura (TTP) complicated with systemic lupus erythematosus (SLE) - demonstration of anti-platelet antibody. Rinsho Ketsueki 1980; 21: 1773-80.
70. Bodensteiner D, Rosenfeld C. Elevated platelet-surface-bound IgM in thrombotic thrombocytopenic purpura. South Med J 1988; 81:81-3.
71. Nakajima T, Koyama T, Kakishita E, Nagai K. Inhibitory effects of TTP sera on binding of anti-platelet glycoprotein IIb-IIIa monoclonal antibodies to human vascular endothelial cells. Am J Hematol 1987; 25: 115-8.
72. Stein RS, Flexner JM. Persistently perplexing purpuras: thrombotic thrombocytopenic purpura and immune thrombocytopenic purpura [letter]. Ann Intern Med 1994; 121:720-1.
73. Krupsky M, Saral R, Hurwitz N, Resnitzky P. Late appearance of thrombotic thrombocytopenic purpura after autoimmune hemolytic anemia and in the course of chronic autoimmune thrombocytopenic purpura: two case reports. Acta Haematol 1991; 85: 139-42.
74. Routy JP, Beaulieu R, Monte M, Saint-Louis J, Sauvageau G, Toma E. Immunologic thrombocytopenic purpura followed by thrombotic thrombocytopenic purpura in two HIV1 patients. Am J Hematol 1991; 38:327-8.
75. Majado MJ, Gonzalez C, Candal R. Thrombotic thrombocytopenic purpura after immune thrombocytopenic purpura [letter]. Sangre (Barc) 1993; 38: 504-5.
76. Olenich M, Schattner E. Postpartum thrombotic thrombocytopenic purpura (TTP) complicating pregnancy-associated immune thrombocytopenic purpura. Ann Intern Med 1994; 120:845-7.
77. Yospur LS, Sun NC, Figueroa P, Niihara Y. Concurrent thrombotic thrombocytopenic purpura and immune thrombocytopenic purpura in a HIV-positive patient: case-report and review of the literature. Am J Hematol 1996; 51:73-8.
78. Zucker-Franklin D, Karpatkin S. Red-cell and platelet fragmentation in idiopathic autoimmune thrombocytopenic purpura. N Engl J Med 1977; 297:517-23.
79. Zucker-Franklin D. Persistently perplexing purpuras: thrombotic thrombocytopenic purpura and immune thrombocytopenic purpura [letter]. Ann Intern Med 1994; 121:721.
80. Macchi L, Rispal P, Clofent-Sanchez G, et al. Antiplatelet antibodies in patients with systemic lupus erythematosus and the primary antiphospholipid syndrome: their relationship with the observed thrombocytopenia. Br J Haematol 1997; 98:336-41.
81. Greenwalt DE, Lipsky RH, Ockenhouse CF, Ikeda H, Tandon NN, Jamieson GA. Membrane glycoprotein CD36: a review of its roles in adherence, signal transduction and transfusion medicine. Blood 1992; 80: 1105-15.
82. Daviet L, McGregor JL. Vascular biology of CD36: roles of this new adhesion molecule family in different disease states. Thromb Haemost 1997; 78:65-9.
83. Knowles DM, Tolidjian B, Marboe C, et al. Monoclonal anti-human monocyte antibodies OKM1 and OKM5 possess distinctive tissue distributions including differential reactivity with vascular endothelium. J Immunol 1984; 132:2170-3.
84. Swerlick RA, Lee KH, Wick TM, Lawley TJ. Human dermal microvascular endothelial but not human umbilical vein endothelial cells express CD36 in vivo and in vitro. J Immunol 1992; 148:78-83.
85. Aiken ML, Ginsberg MH, Byers-Ward V, Plow RF. Effects of OKM5, a monoclonal antibody to glycoprotein IV, on the platelet aggregation and thrombospondin surface expression. Blood 1990; 76:2501-9.
86. Lian ECY, Siddiqui FA, Jamieson GA, Tandon NN. Platelet agglutinating protein p37 causes platelet agglutination through its binding to membrane glycoprotein IV. Thromb Haemost 1991; 65:102-6.
87. Siddiqui FA, Lian ECY. Platelet-agglutinating protein p37 from a thrombotic thrombocytopenic purpura plasma forms complexes with platelet membrane glycoprotein IV (CD36). Biochem Int 1992; 27:485-96.
88. Siddiqui FA, Lian ECY. Novel platelet-agglutinating protein from a thrombotic thrombocytopenic purpura plasma. J Clin Invest 1985; 76:1330-7.
89. Lian ECY, Siddiqui FA. Binding of platelet agglutinating protein p37 from the plasma of a patient with thrombotic thrombocytopenic purpura to human platelets. Thromb Haemost 1991; 65:96-101.
90. Rock G, Chauhan K, Jamieson GA, Tandon NN. Anti-CD36 antibodies in patients with lupus anticoagulant and thrombotic complications. Br J Haematol 1994; 88:878-80.
91. Al-Shahi R, Mason JC, Rao R, et al. Systemic lupus erythematosus, thrombocytopenia, microangiopathic haemolytic anaemia and anti-CD36 antibodies. Br J Rheumatol 1997; 36:794-8.
92. Borzini P, Riva M, Nembri P, et al. CD36 autoantibodies and thrombotic diathesis, thrombocytopenia and repeated early fetal losses. Vox Sang 1997; 73:46-8.
93. Tsai HM, Nagel RL, Hatcher VB, Sussman II. Multimers composition of endothelial cell-derived von Willebrand factor. Blood 1989; 73:2074-6.
94. Dent JA, Berkowitz SD, Ware J, Kasper CK, Ruggeri ZM. Identification of a cleavage site directing the immunochemical detection of molecular abnormalities in type IIA von Willenbrand factor. Proc Natl Acad Sci USA 1990; 87:6306-10 [Erratum, Proc Natl Acad Sci USA 1990; 87:9508].
95. Tsai HM, Sussman II, Nagel RL. Shear stress enhances the proteolysis of von Willebrand factor in normal plasma. Blood 1994; 83:2171-9.
96. Furlan M, Robles R, Lämmle B. Partial purification and characterization of a protease from human plasma

© Karger Sorti Ediz. Srl

cleaving von Willebrand factor to fragments produced by in vivo proteolysis. Blood 1996; 97:4223-34.
97. Tsai HM. Physiologic cleavage of von Willebrand factor by a plasma protease is dependent on its conformation and requires calcium ion. Blood 1996; 87: 4235-44.
98. Furlan M, Robles M, Solenthaler M, et al. Deficient activity of von Willebrand factor-cleaving protease in chronic relapsing thrombotic thrombocytopenic purpura. Blood 1997; 89:3097-103.
99. Furlan M, Robles R, Solenthaler M, Lämmle B. Acquired deficiency of von Willebrand factor-cleaving protease in a patient with thrombotic thrombocytopenic purpura. Blood 1998; 91:2839-46.
100. Furlan M, Robles R, Galbusera M, et al. Von Willebrand factor-cleaving protease in thrombotic thrombocytopenic purpura and the hemolytic-uremic syndrome. N Engl J Med 1998; 339:1578-84.
101. Tsai HM, Lian ECY. Antibodies to von Willebrand factor-cleaving protease in acute thrombotic thrombocytopenic purpura. N Engl J Med 1998;339:1585-94.
102. Moake JL. Moschcowitz, multimers and metalloprotease [editorial]. N Engl J Med 1998; 339:1629-31.
103. Bettendorf U, Potters R. Moschcowitz's disease following D-penicillamine medication. Med Welt 1975; 26:291-5.
104. Speth PA, Boerboons AM, Holdrinet RS, Van de Putte LB, Meyer JW. Thrombotic thrombocytopenic purpura associated with D-penicillamine treatment in rheumatoid arthritis. J Rheumatol 1982; 9:812-3.
105. Trice JM, Pinals RS, Plitman GI. Thrombotic thrombocytopenic purpura during penicillamine therapy in rheumatoid arthritis. Arch Intern Med 1983; 143:1487-8.
106. Ahmed F, Sumalnop V, Spain DM, Tobin MS. Thrombotic thrombocytopenic purpura during penicillamine therapy. Arch Intern Med 1978; 138:1292-3.
107. Harrison EE, Hickman JW. Hemolytic anemia and thrombocytopenia associated with D-penicillamine therapy. Southern Med J 1975; 68:113-5.

©Ferrata Storti Foundation