

Toluol/xylol-induced leukemia

ANTONIO CUNEO, MARIA GRAZIA ROBERTI, GIANLUIGI CASTOLDI

Dipartimento di Scienze Biomediche e Terapie Avanzate, Sezione di Ematologia, Università degli Studi di Ferrara, Italy

A 67-year-old retired school-teacher was referred to our Institute with a 3-week history of fatigue, recent onset of fever, leukopenia with few neutrophils and thrombocytopenia on a blood count. Her past medical history was unremarkable. Since retirement at the age of 60, she had been devoting 4-6 hours a day to artistic painting of windows, using varnishes containing 44% toluol and xylol, in a small domestic environment without ventilation.

The bone marrow (BM) aspiration showed more than 30% blast cells, with trilineage myelodysplasia

(see Figure 1, upper panel).

A karyotype with multiple chromosome changes, including abnormalities of chromosomes 5 and 7 was found in 20 BM marrow cells (Figure 1, lower panel). The patient was treated with an anthracycline drug, plus cytarabine in conventional doses and etoposide. The pancytopenia persisted 1 month after cessation of chemotherapy, followed by early blast cell regrowth. The patient died 3 month later without achieving remission with salvage chemotherapy.

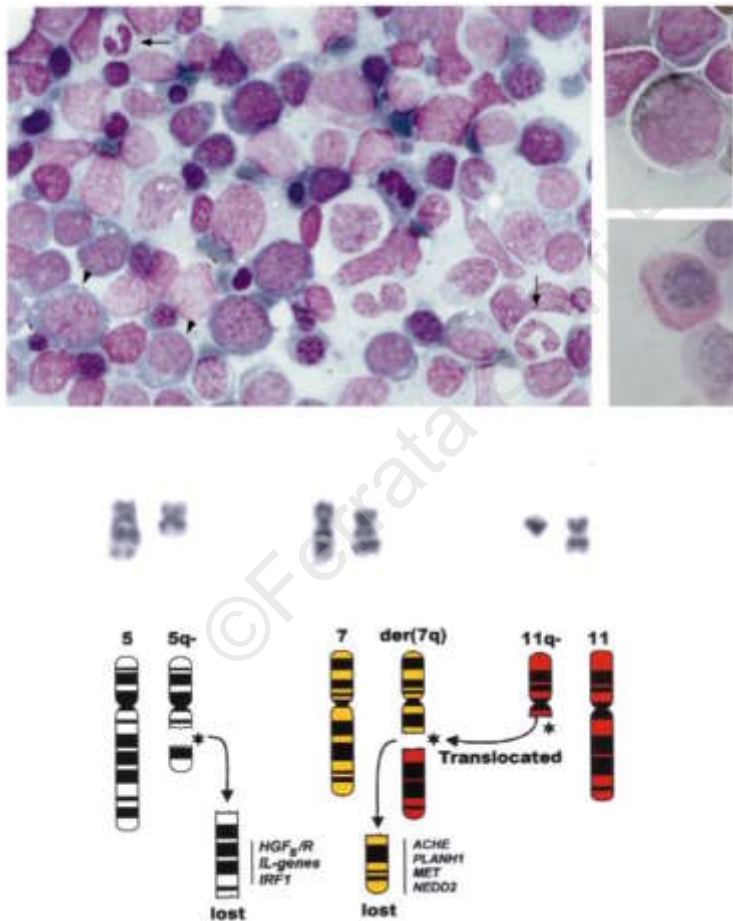


Figure 1. Upper panel: BM picture with blast cells and myelodysplasia of the non-blast cell population, consisting of dyserythropoiesis, dysgranulopoiesis and absence of megakaryocytes. Note megaloblastosis with vacuolization of early erythroblasts (arrowhead), irregularity of the nuclear outline of erythroid cells (thin arrows), and agranular neutrophils (thick arrow). A peroxidase-positive blast (up) and a PAS-positive cell (down), deriving from abnormal accumulation of glycogen or glycoprotein in maturing erythroblasts are shown on the right.

Lower panel: del(5)(q13q31) and der(7)t(7;11)(q22;q13) (on the right of each pair), with the resultant 11q-chromosome (on the left of the pair). The abnormal chromosomes are schematically represented in the lower section, along with potentially relevant genes that were lost as a consequence of the 5q and 7q deletion.

(Abbreviations: HGF/R: genes for hemopoietic growth factors and receptors, including the granulocyte-monocyte colony-stimulating factor (GM-CSF) the early growth factor response-1 (EGF1), the glucocorticoid receptor (GRL), the platelet-derived growth factor receptor- β (PDGFB), the colony-stimulating factor 1 receptor (CSF1R), IL: interleukins, including IL3, IL4, IL5, IL9; IRF-1: interferon response factor 1 gene. ACHE: acetylcholinesterase gene; PLANH1: plasminogen activator inhibitor 1 gene; MET: a proto-oncogene; NEDD2: an apoptosis regulatory gene).

This acute myelogenous leukemia was similar in many aspects to: i) benzene-induced leukemia,¹ ii) to leukemia in subjects declaring prolonged exposure to pesticides and organic solvents in the workplace,² and, iii) to leukemia arising after prior therapy of another tumor using alkylating agents and/or radiotherapy.³ These leukemias are usually *oligoblastic* in nature, they display trilineage myelodysplasia with 5q- and/or 7q- chromosomes and run an unfavorable clinical course. Indeed, genetic damage in environmentally-induced and therapy-related leukemias may be driven by similar transformation mechanisms resulting in hemopoietic neoplasms having several clinicobiologic features in common.

Studies aimed at a more precise definition of the toxicity profile of these solvents are warranted;⁴ in the meantime, careful control on the distribution of toluol and xylol-containing materials and strict sur-

veillance of the protection measures employed in workplaces using these substances appears to be recommendable.

References

1. Jacobs A. Benzene and leukemia. *Br J Haematol* 1989; 72:119-21.
2. Cuneo A, Fagioli F, Pazzi I, et al. Morphologic, immunologic and cytogenetic studies in acute myeloid leukemia following occupational exposure to pesticides and organic solvents. *Leuk Res* 1992; 16:789-96.
3. Iurlo A, Mecucci C, Van Orshoven A, et al. Cytogenetic and clinical investigations in 76 cases with therapy-related leukemia and myelodysplastic syndrome. *Cancer Genet Cytogenet* 1989; 43:227-41.
4. Jacobs A, Geary C, Osman J. Haematological disorders and occupational hazards: a British Society for Haematology/Health and Safety Executive study. *Br J Haematol* 1993; 84:555-7.