



## Acute generalized, widespread bleeding. Diagnosis and management

EDUARDO ROCHA,\*° JOSÉ A. PÁRAMO,\*\*° RAMÓN MONTES,° CARLOS PANIZO\*

\*Department of Hematology, Clínica Universitaria; °Laboratory of Vascular Biology and Thrombosis Research, Facultad de Medicina, Universidad de Navarra, Pamplona, Spain

### Abstract

**Background and Objective.** Acute generalized, widespread bleeding is often related to disseminated intravascular coagulation (DIC), a pathologic process which complicates the clinical course of many diseases and is characterized by huge amounts of thrombin and plasmin within the circulation. The final result is the consumption of platelets, coagulation factors and inhibitors, as well as secondary hyperfibrinolysis, all leading to diffuse hemorrhage and microthromboses. This review article examines the present attitudes to the diagnosis and treatment of overt DIC in clinical practice, emphasizing the importance of an accurate differential diagnosis from some other processes characterized by acute generalized, widespread bleeding.

**Information Sources.** The authors have been working in this field, both at experimental and clinical levels, contributing original papers for many years. In addition, material examined in this review includes articles published in journals covered by MedLine®, recent reviews in journals with high impact factor and in relevant books on hemostasis and thrombosis.

**State of Art and Perspectives.** DIC is an intermediary mechanism of disease which complicates the clinical course of many well-known disorders. Although the systemic hemorrhagic syndrome is the predominant clinical manifestation, massive intravascular thrombosis frequently occurs contributing to ischemia and associated organ damage, making the mortality rate of this condition high. Current concepts on the pathophysiology, laboratory diagnosis and management of DIC are presented. Complex pathophysiological interrelations make the diagnosis of the etiology of the DIC difficult in clinical practice, although simple tests are useful for identification of patients with the process. Laboratory diagnosis of DIC is mainly based on screening assays, which allow a rapid diagnosis, whereas some other highly sensitive but more complex assays are not always available to routine clinical laboratories. The management of DIC is based on the treatment of the underlying disease, supportive and replacement therapies and the control of the coagulation mechanisms. Although some advances have been achieved, management decisions are still controversial, so that therapy should be highly individualized depending on the nature of the DIC and severity

of clinical symptoms. Many syndromes sharing common findings with DIC, such as primary hyperfibrinolysis or thrombotic thrombocytopenic purpura, should be excluded. Finally, new therapeutic approaches to the management of this potentially catastrophic syndrome are required.

©1998, Ferrata Storti Foundation

Key words: disseminated intravascular coagulation, bleeding

The acute appearance of a general and widespread hemorrhagic syndrome, associated with a great number of underlying diseases, is a characteristic finding of disseminated intravascular coagulation (DIC). In clinical practice, some disorders closely related to DIC, such as primary hyperfibrinolysis, thrombotic thrombocytopenic purpura (TTP) and the complex hemostatic abnormalities associated with severe hepatic disorders can mimic a similar clinical condition, often making differential diagnosis difficult. This review will be restricted to bleeding syndromes secondary to DIC. The remaining processes will be considered only in order to mention them as differential diagnoses and list their treatments.

As McKay previously described,<sup>1</sup> DIC is an *intermediary mechanism of disease* associated with a variety of disorders and clinical conditions. It probably represents a hyperactive response of the physiologic control mechanisms to a wide number of tissue insults. Although sometimes DIC can become itself the primary mechanism of disease, in most cases it is an epiphenomenon that complicates a previously established clinical entity.

DIC can appear in the evolution of many diseases (Table 1).<sup>2-6</sup> In hospital clinical practice, the most frequent of these are infections, representing 25-30% of the cases reported in the largest series,<sup>7-9</sup> followed by neoplastic processes, obstetrical accidents, crush injuries and major surgical operations, and liver diseases.

All these conditions can activate the coagulation system by triggering the generation of thrombin within the systemic circulation. This activation occurs as a direct effect of a broad spectrum of endothelial or tissue lesions. Normal endothelium plays a key role

Correspondence: E. Rocha, M.D., Hematology Service, Clínica Universitaria, Universidad de Navarra, P.O. 4209, Pamplona, Spain.  
Phone: international +34-948-296397 • Fax: international +34-948-296500 • E-mail: erocha@unav.es

**Table 1. Some causes of DIC.**

1. Infections:	Gram-negative bacteria (endotoxin) Gram-positive bacteria (mucopolysaccharides) Viruses, fungi, protozoa, others
2. Neoplasia:	Solid tumors (adenocarcinomas, others) Leukemia (promyelocytic, others)
3. Obstetric complications:	Amniotic fluid embolism Abruptio placentae Retained dead fetus Septic abortion Eclampsia
4. Trauma and tissue injury:	Brain injury Crush injury Burns Surgery Hyperthermia Hypothermia
5. Liver disease:	Fulminant hepatic failure Cirrhosis Acute fatty liver of pregnancy LeVeen shunt Reye's syndrome
6. Transfusion reactions:	Acute hemolytic transfusion reaction Massive transfusion
7. Vascular disease:	Aortic aneurysm Giant hemangioma (Kasabach-Merrit syndrome) Malignant hypertension Microangiopathic disorders
8. Venoms (vipers, other snakes, insects)	
9. Respiratory distress syndromes	
10. Shock	
11. Drugs/Therapeutic agents:	Clotting factor concentrates (factor IX) OKT3 monoclonal antibody Interleukin-2
12. Miscellaneous:	Amyloidosis Pancreatitis Autoimmune diseases Renal vascular disorders Kawasaki disease Anaphylaxis Sarcoidosis

in hemostatic regulation through a variety of mechanisms, such as secretion or cell surface expression of heparan sulfate proteoglycan, thrombomodulin, prostacyclin, von Willebrand factor (vWF), tissue factor (TF), tissue plasminogen activator (t-PA) and plasminogen activator inhibitor 1 (PAI-1).<sup>10</sup> Endothelial damage may lead to disturbance or loss of its regulatory functions as a result of physical injury, infec-

tious pathogens or toxins or inflammatory mediators such as bacterial endotoxins, activated complement, interleukin 1 (IL-1), tumor necrosis factor- $\alpha$  (TNF- $\alpha$ ) or neutrophil proteases exposure.<sup>11-13</sup> As far as concerns tissue lesions, these lead to some procoagulant material entering the circulation, particular TF, whose contribution to the activation of coagulation has been demonstrated in experimental DIC studies.<sup>14,15</sup> The contribution of the contact system, particularly factor XII, to the activation of coagulation in DIC is, however, uncertain, although a role for the development of hemodynamic disorders associated with DIC and possibly for the activation of the fibrinolytic system has been proposed.<sup>16-19</sup>

The activation of coagulation after a triggering event can be promoted directly or by the mediation of cytokines, mainly TNF- $\alpha$  and IL-1,<sup>12,13,20-25</sup> contributing to the development of the theoretically well-differentiated stages of the pathophysiological mechanism of DIC (Figure 1). However, in clinical practice these stages are usually intertwined. Generation of circulating thrombin is a direct consequence of the activation of coagulation and responsible for fibrin generation and platelet activation leading to small vessel thrombosis thus producing ischemic lesions, necrosis and functional failure of several organs. The most commonly involved organs are the kidney, lung, central nervous system and skin. Microangiopathic hemolytic anemia also occurs as a result of fibrin deposits within the microcirculation. Moreover, activation of coagulation causes consumption of platelets and coagulation factors which contribute to hemorrhagic diatheses. Formation of intravascular fibrin triggers fibrinolysis and the resulting generation of plasmin through the action of t-PA released in response to cytokines generated by the initial stimulus. Activation of fibrinolysis represents a compensating system that degrades microvascular fibrin clots. The importance of such a mechanism is clearly shown in patients with sepsis due to Gram-negative bacteria, in whom endotoxin causes an increase in the levels of PAI-1<sup>26,27</sup> as shown experimentally by the inhibitor levels being higher in patients with DIC. This is an indicator of a poor prognosis.<sup>28,29</sup> The hyperplasminemia becomes the main cause of the hemorrhagic diathesis for two reasons: it induces the generation of great quantities of fibrinogen degradation products (FDP) and fibrin degradation products with a powerful anti-hemostatic action, and reduces the plasma concentrations of coagulation factors because of its capacity to degrade them. Finally, natural coagulation inhibitors, including antithrombin III (ATIII), proteins C and S and the inhibitor of the extrinsic pathway (TFPI) are also consumed, thus contributing to the increased generation of thrombin and fibrin. The pathophysiologic importance of these inhibitors has been recently evaluated by several clinical and experimental studies, although the results have not always been concordant.<sup>14,20,30-40</sup>

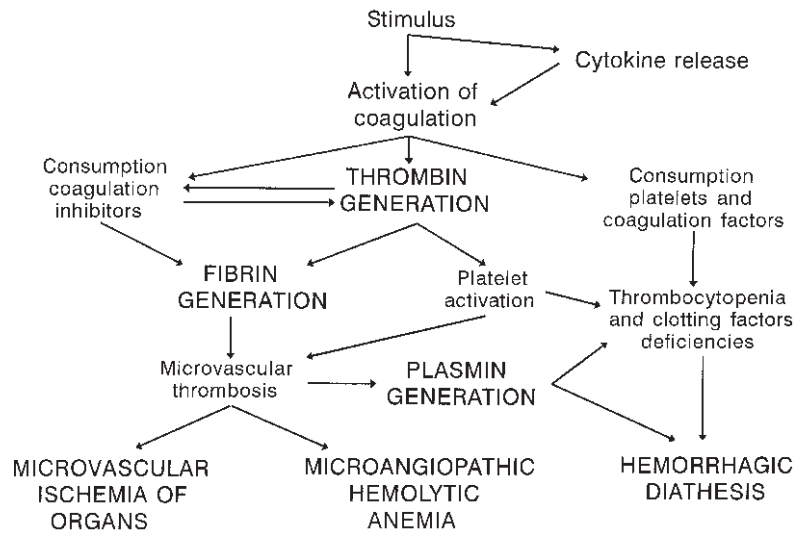


Figure 1. Pathophysiology of DIC.

The intervention of normal compensatory processes must also be considered in the pathophysiology of DIC. These processes include activation of the fibrinolytic system and the liver's capacity to synthesize coagulation factors, as well as production of platelets in the bone marrow in order to compensate for consumption, the clearance mechanisms of the factors responsible for the initial stimulus, activated coagulation factors and FDP by the mononuclear phagocytic system.

Therefore, the pathophysiology of DIC seems to be controlled by two main mechanisms: generation of thrombin and generation of plasmin. When the latter prevails, the clinical picture is characterized mainly by hemorrhagic symptoms. When generation of thrombin dominates, the most important symptoms are those caused by microvascular thrombosis and organ ischemia. It is also important to consider the acute or chronic nature of the process and the quality of activation, systemic or localized. This brief review of the etiology and pathophysiology of DIC is necessary in order to have a clear understanding of the diagnosis and treatment approaches to the condition.

The enormous complexity of the etiology, pathogenesis and pathophysiology of DIC explains why it generates controversy. In fact, it has been impossible to define unified criteria and come to an agreement on the most appropriate laboratory methods for diagnosis. As regards the response to treatment and survival, it should be noted that in many cases these are more related to the primary cause of DIC than to the treatment itself. Furthermore, there are no randomized, prospective assays evaluating any of the possible treatments. In this review we are trying to update the actual knowledge about DIC searching

for maximum objectivity and avoiding any possible dogmatism.

### Clinical presentation of DIC

The diagnosis of DIC is essentially based on clinical findings, the laboratory tests being useful for confirmation. Because of the great variety of primary conditions which can cause DIC, the clinical presentation may be very complex due to signs and symptoms directly related to the underlying disorder as well as to those more characteristic of DIC. On the other hand, DIC can be asymptomatic or manifest as a severe picture of hemorrhage and/or thrombosis, depending on the rates of fibrin formation and lysis.

Hemorrhages are the most frequent and common presentation of the disease.<sup>9</sup> In some cases bleeding appears exclusively at the sites of venous or arterial punctures or at surgical or traumatic wounds. More common is the appearance of widespread petechiae, purpura and hematomas, mucocutaneous bleeding, hematuria, hemoptysis, gastrointestinal bleeding and, occasionally, intracranial hemorrhage.<sup>41-43</sup>

The thrombotic manifestations may not be as clinically obvious as hemorrhages in patients with DIC. However, fibrin microthrombi often result in organ dysfunction. All organs are potentially vulnerable. Acute renal failure occurs frequently and acute tubular necrosis often accompanies this syndrome.<sup>42</sup> Microvascular cerebral thrombosis causes cortical dysfunction manifested by an altered state of consciousness and coma.<sup>41</sup> The combination of pulmonary hemorrhages and thrombosis produces a clinical picture resembling acute respiratory distress syndrome.<sup>44</sup> Thrombosis in large vessels is less frequent except in the cases of an indwelling intravascular catheter and the thrombosis associated with

chronic DIC secondary to malignancies when the incidence of venous thromboembolism is high (Trousseau syndrome).<sup>45</sup>

In some circumstances DIC is associated with purpura fulminans characterized by skin hemorrhagic necrosis and gangrene in the extremities of digits as a consequence of arterial fibrin microthrombi. This syndrome appears in patients with Gram-negative bacterial sepsis<sup>46,47</sup> and also in other diseases<sup>48,49</sup> and is associated with reduced levels of proteins C and S.<sup>50</sup> Two clinical situations related to purpura fulminans are adrenal hemorrhagic necrosis (Waterhouse-Fridrichsen syndrome)<sup>51</sup> and adrenal cortex necrosis.<sup>52</sup>

### Laboratory diagnosis of DIC

Because of the complex pathophysiology of DIC and its association with a variety of processes, the laboratory manifestations in a given patient are extremely variable and depend not only on findings due to DIC but also on those due to the underlying disease. In addition, the intensity and duration of activation of blood coagulation and the consequent thrombin formation, the state of natural clotting inhibitors, the fibrinolytic system activation, the level of the liver function, the capacity of bone marrow to produce platelets, the activity of the macrophage system, the rate of blood flow and many other variables markedly influence the clinical picture and laboratory findings.

As a consequence of all the above, it is not surprising that the criteria for the diagnosis of DIC are not well defined. It seems clear that the frequency of diagnosis depends on two factors: the knowledge of the occurrence of DIC in certain clinical settings and the laboratory criteria used to make the diagnosis. These criteria are extremely arbitrary and the analysis should always take into account both the patient's underlying disease and the functional state of several organs.

Tests which are useful in assessing patients with possible DIC can be divided into two categories (Table 2): screening tests, which allow a rapid diagnosis, and thus being those really useful in the acute forms, and more complex laboratory tests, highly sensitive but time-consuming and not always available in routine clinical laboratories, which are not, therefore, of immediate clinical relevance, at least in the acute forms. In fact, these latter tests should be restricted to specialized laboratories and to clinical situations allowing closer laboratory monitoring.

### Screening Tests

If DIC is present, the global coagulation tests which measure the capacity of thrombin generation, such as the prothrombin time and the activated partial thromboplastin time (APTT), should show prolonged coagulation times because of the decrease of fibrinogen and factors II, V, VII, IX and X as a consequence of consumption and plasmin-induced prote-

**Table 2. Laboratory diagnostic criteria of DIC.**

1. Screening tests:
Thrombocytopenia
Hypofibrinogenemia
Elevated FDP and D-dimer
Decreased ATIII
Prolonged clotting times
Presence of schistocytes in peripheral blood smear
Positive tests for circulating soluble fibrin monomers
2. Other tests:
Decreased level of various clotting factors
Decreased protein C
Elevated F1+2, TAT and FPA
Decreased plasminogen and $\alpha_2$ -antiplasmin
Elevated PAP, B $\beta$ 1-42 and B $\beta$ 15-42 peptides
Elevated PF4 and $\beta$ -TG

olysis of these factors as well as the presence of FDP which inhibit fibrin polymerization. However, both tests may be demonstrate normal or fast rate coagulation in a percentage of patients with DIC,<sup>5,6,8,9,53</sup> due to the presence of circulating activated clotting factors or early fibrin degradation products rapidly clottable by thrombin.<sup>6</sup> This is the reason why both tests are of little use in evaluating DIC. The thrombin time may also be prolonged due to hypofibrinogenemia and interference of circulating FDP.<sup>54</sup> However, it may be sometimes normal or shortened and is in any case difficult to standardize, so that this, too, is also of little use in the diagnosis of DIC.

Thrombocytopenia is a constant feature in patients with DIC and is related to shortened platelet survival.<sup>7,9,53</sup> DIC also causes a qualitative defect in platelets.<sup>55</sup> The thrombocytopenia may also be related to the underlying disorder, such as in acute promyelocytic leukemia (APL) and sepsis.<sup>56,57</sup> These factors explain why a fall in platelet count is neither sensitive nor specific for DIC.

Fibrinogen concentration is reduced in approximately 50% of patients,<sup>7,9</sup> but since it increases in situations such as after operations, in infection and during pregnancy, the measured fibrinogen levels may be *normal* in the presence of DIC.

FDP are elevated in 85 to 100% of patients with DIC,<sup>3,5,7,9</sup> although their levels are not always related to the clinical course of DIC since they are influenced by the degree of procoagulant activity, the fibrinolytic response and other factors such as the activity of the macrophage system and renal clearance. The D-dimer, which is specific for fibrin degradation products, is more specific but less sensitive than the latex agglutination assays for FDP which measure the plasmin degradation of fibrinogen and fibrin.<sup>58,59</sup> Two additional advantages of the D-dimer test over FDP assays are the possibility of it being performed on both plasma and serum and its lower susceptibility to



artifacts caused by incomplete clotting of plasma samples.<sup>58</sup> Of the common tests used in assessing DIC in patients, the D-dimer assay appears to be the most abnormal in a high proportion of patients.<sup>6,60-62</sup> It is worthwhile noting that the increase of D-dimer is not specific to DIC, since it can also occur in deep venous thrombosis and pulmonary embolism, post-operatively and in many other clinical conditions.<sup>63-66</sup>

Protamine sulfate or ethanol gel tests for circulating soluble fibrin monomers were commonly used in the diagnosis of DIC some years ago. However, although specific they are not sensitive and are poorly standardized.<sup>8,9,67</sup> More recently, new sensitive assays to detect fibrin monomers have been incorporated which can be useful in supporting a diagnosis of DIC, although complex for routine use.<sup>68-71</sup>

Measurement of ATIII activity is considered another screening test in patients with DIC since its value markedly declines over time due to consumption.<sup>9,72,73</sup> There is one exception, the DIC associated with APL, where the functional level of ATIII remains normal,<sup>6</sup> supporting the hypothesis that the coagulopathy in APL is not caused by DIC but by primary fibrinolysis.<sup>74</sup>

Examination of the peripheral blood smear often reveals schistocytes, but this finding is non-specific, and the absence of schistocytes does not exclude DIC.<sup>9,75,76</sup> Differential diagnosis from TTP should be made in the presence of a marked schistocytosis.

At present, no single laboratory test can be used to confirm or exclude the diagnosis of DIC, but the combination of a low platelet count, a decrease of fibrinogen and ATIII and an increase of FDP – and especially D-dimer – viewed in the context of the patient's underlying disease, appears to be the most useful indicator. Less useful are the presence of schistocytes in the blood smear, the prolongation of prothrombin, APTT and thrombin times and the positivity of protamine sulfate or ethanol tests.

### **Other tests for the diagnosis of DIC**

Coagulation factor assays, previously considered to be useful, provide little information useful to the diagnosis of DIC. The interpretation of results is difficult partly because many underlying diseases result in increases and decreases in coagulation factors, and partly because of the presence of activated clotting factors in DIC which interfere with routine coagulation assays.<sup>3,6</sup> In particular, activities of factors II, V, VII and X are likely to be low, whereas levels of factor VIII are often normal in DIC, probably because the factor VIII/von Willebrand released by endothelial cells forms a complex which stabilizes factor VIII.<sup>77</sup> A decrease in circulating levels of protein C has also been found in patients with DIC.<sup>31,34</sup>

The conversion of prothrombin to thrombin results in the release of an inactive prothrombin fragment 1.2 (F1+2). Once thrombin is produced it can either combine with ATIII to form a stable thrombin-antithrombin (TAT) complex or induce fibrinogen

proteolysis with the liberation of fibrinopeptides A and B (FPA and FPB). ELISA assays are now commercially available to quantify the plasma levels of F1+2, TAT and FPA in order to provide evidence of activation of coagulation. Although there are numerous reports showing a significant increase in these molecular markers in patients with DIC,<sup>13,71,78-83</sup> none of these tests are widely used routinely for diagnosis.

Fibrinolytic system assays may provide useful information in DIC. The global tests, such as the euglobulin lysis time and fibrin plate assays provide little information. However, in many cases there is a decrease in plasminogen and  $\alpha$ 2-antiplasmin, due to consumption, as well as a significant increase in plasmin-antiplasmin (PAP) complexes, providing direct evidence of *in vivo* plasmin generation, and in peptides B $\beta$  15-42 and B $\beta$  1-42 derived from the proteolytic action of plasmin on fibrin and fibrinogen respectively.<sup>5,6,84-89</sup> A significant increase of PAI-1, which was related to a poor prognosis in some cases of DIC associated with sepsis or trauma, has also been reported.<sup>28,29,90</sup>

Finally, increased platelet turnover and decreased platelet survival is common in patients with DIC; platelet factor 4 and  $\beta$ -thromboglobulin levels are markers of platelet reactivity and release and are usually elevated in patients with DIC.<sup>91</sup>

At present, none of the mentioned tests are routinely used in patients with a suspicion of DIC and there are not enough data regarding their clinical reliability compared to the screening tests which are cheaper, easier to perform and more readily available in clinical laboratories.

### **Differential diagnosis**

Whereas there are few causes of acute, early onset, massive and generalized hemorrhage in a patient without a previous bleeding history and the cause is frequently known in acquired coagulopathies, there are some processes in which either the laboratory or clinical manifestations resemble those occurring in DIC. Septic patients may develop vitamin K deficiency or thrombocytopenia in the absence of DIC,<sup>56,57,92,93</sup> but the differential diagnosis is relatively simple since these conditions do not cause generation of FDP or D-dimer, depletion of fibrinogen or consumption of ATIII. Significant bleeding due to reduced platelets and coagulation factors and inhibitors rather than DIC may be observed after massive transfusion or cardiopulmonary bypass surgery as a result of hemodilution;<sup>94-96</sup> the absence of D-dimer and FDP generation may be useful in the differential diagnosis.

The coagulopathy associated with hepatic failure may be very difficult to distinguish from DIC. The former's characteristics include thrombocytopenia due to platelet sequestration in the spleen, reduction of fibrinogen and other coagulation factors and inhibitors by abnormal synthesis, and elevated levels of FDP and D-dimer due to delayed hepatic clearance

and hyperfibrinolysis.<sup>97-100</sup> In the cases in which diagnosis is difficult,<sup>101</sup> the only way to differentiate DIC in the presence of liver disease is to perform serial measurements which, in the event of acute DIC, usually reveal a rapidly changing coagulopathy.<sup>58</sup>

TTP may be confused with DIC since it produces acute illness with multiorgan dysfunction and disseminated thrombotic and hemorrhagic phenomena. Ischemic symptoms are related to intraluminal platelet thrombi and the hemorrhagic manifestations depend on the degree of secondary thrombocytopenia due to platelet consumption. However, as shown in Table 3, TTP does not usually cause consumption of clotting factors or hyperfibrinolysis,<sup>102-104</sup> making the differential diagnosis from DIC easy. TTP patients show an increase in thrombin generation and reduced fibrinolysis probably related to an increase in PAI-1.<sup>105</sup> Although the etiology of TTP is not fully understood, two hypotheses have been proposed to explain the pathophysiology of this disease. For some authors, the platelet aggregation is due to the lack of a normally occurring platelet inhibitor<sup>106</sup> or to a platelet agglutinating protein,<sup>107</sup> whereas for others an abnormally large plasma von Willebrand factor molecule would cause excessive platelet agglutination,<sup>108,109</sup> although this multimeric pattern is not always present.<sup>110</sup> The prognosis of TTP has changed dramatically in the last years with the combination of plasmapheresis and plasma infusions to provide the absent factor and to remove platelet-aggregating substances.<sup>111-113</sup>

Finally, the possibility of unusual primary hyperfibrinolysis should also be taken into account in the differential diagnosis of an acute, massive hemorrhagic disorder. The distinction from DIC may be very difficult because the same underlying disease can cause both processes, the bleeding symptoms may be similar, high concentrations of D-dimer and FDP can be present in both conditions, and lastly because DIC and hyperfibrinolysis may coexist in patients. The distinction is that in DIC the lysis is a physiologic response to fibrin deposition in the microcirculation,

whereas in primary hyperfibrinolysis lysis occurs in the macrocirculation, perhaps as a result of activators released by endothelial cells, or as a consequence of the exogenous administration of plasminogen activators after thrombolytic therapy. That having been said, the distinction between DIC and systemic hyperfibrinolysis may be extremely difficult (Table 3), even when well-equipped laboratory facilities are available. The simplest laboratory evaluation for the diagnosis of hyperfibrinolysis is a shortened euglobulin lysis time in the absence of thrombocytopenia and schistocytosis.<sup>42</sup> A correct differential diagnosis is very important since the treatment of choice in hyperfibrinolysis is administration of fibrinolysis inhibitors, such as  $\epsilon$ -aminocaproic acid (EACA) or tranexamic acid, which can be dangerous in the presence of DIC.<sup>114</sup> Primary hyperfibrinolysis may appear in the course of trauma, cardiopulmonary bypass surgery, liver transplantation, liver cirrhosis, prostatic carcinoma or congenital deficiencies of  $\alpha_2$ -antiplasmin and PAI-1.<sup>2,5,42,100,115-117</sup> On the other hand, in other conditions such as APL-associated DIC, fibrinolysis predominates over activation of coagulation leading to a marked risk of bleeding in these patients.<sup>118</sup>

### Management of DIC

The treatment of DIC is even more controversial than the other aspects of this pathology. Very different attitudes to this condition have been adopted in clinical practice, mainly as a consequence of the lack of studies conclusively showing the most efficient treatment. Although large series from which to draw definitive conclusions are not available, there is some evidence to support a few currently held opinions.

In the past DIC was associated with high mortality rates: the fact that the diseases underlying the DIC are themselves often fatal must, however, be kept in mind. This means that the cause of death in many patients is due more to the progression of the underlying disease than to the progression of the DIC.<sup>119</sup> Nevertheless, more reasonable and effective therapeutic strategies have favored longer patient survival. The treatment of DIC must be logical and sequential, and should include four different strategies: treatment of the underlying disease or etiology treatment, supportive therapy, replacement therapy and arrest of the coagulation mechanism by heparin or other thrombin inhibitors.

### Treatment of the underlying cause

The most important approach to DIC is the suppression or attenuation of the trigger mechanism through fast and vigorous treatment of the underlying disease.<sup>3,4,6,120-122</sup> This crucial point is more important than the remaining therapeutic alternatives to be described. We may not be able to arrest the mechanism which leads to the activation of the coagulative pathways in some cases (e.g. neoplasia), but in other instances appropriate treatment reduces the

**Table 3. Differential laboratory diagnosis of DIC, primary hyperfibrinolysis and TTP.**

	DIC	Primary hyperfibrinolysis	TTP
Platelet count	Low	Normal	Low
Fibrinogen	Low	Low	Normal
FDP	Elevated	Elevated	Normal
D-dimer	Elevated	Elevated	Normal
ATIII	Decreased	Normal	Normal
Schistocytosis	Present	Absent	Present
Clotting times	Prolonged	Prolonged	Normal
Lysis times	Short	Short	Normal

stimulus which induces coagulation activation. It seems clear that there are no useful therapies while the underlying cause persists as illustrated by DIC complicating obstetric disorders or sepsis. In the former cases, with the exception of amniotic fluid embolism, evacuation of the uterus or, much less frequently, hysterectomy, stop the DIC process; many times a serious problem arises to convince the gynecologist to operate on a patient who is bleeding. As far as sepsis is concerned, adequate antibiotic often succeeds in stopping DIC.

Other therapeutic approaches to treating the DIC directly are needed when the patient keeps on bleeding after a reasonable period of time, although it is not easy to establish what this period is since it depends heavily on the location and severity of the hemorrhagic episodes.

### **Supportive therapy**

Supportive therapy must be started at the same time as treatment of the underlying disease. Hypervolemia and hypoxia should be compensated, acidosis should be controlled and a good electrolytic balance should be achieved. The supportive treatment must be adjusted to each specific clinical situation and each individual patient. In patients with DIC and shock the measures to restore hydroelectrolytic balance, increase the volume of the vascular compartment, and improve the cardiac deficit and hypotension can sometimes in themselves be enough to stop DIC but more often they help to establish the conditions needed to make the subsequent treatment efficient.

### **Replacement therapy**

The aim of the blood replacement in DIC is to correct the consumption of platelets, coagulation factors and inhibitors in order to prevent or arrest the hemorrhagic episodes. However, it has been hypothesized that this treatment might *feed the fire* and cause thrombosis in patients with active DIC, although this issue has not been demonstrated in clinical practice<sup>123</sup> or shown to be only marginal.<sup>124</sup> Therefore, the usefulness of replacement therapy in some situations is, at present, beyond all doubt. Whether replacement therapy should start before or after the anticoagulant treatment has been initiated remains controversial, except for the cases in which the stimulus has been totally eliminated. In our opinion, replacement therapy is probably not necessary when the patient is not bleeding and does not require surgery or other invasive methods. In contrast, if the patient is bleeding or requires an invasive procedure, replacement therapy with cryoprecipitate, fresh-frozen plasma (FFP) and platelet concentrates will probably be needed. Replacement therapy is particularly important in patients with DIC and underlying hepatic disease, because in these conditions faster and more pronounced reduction of factors can take place due to

the combination of increased consumption and decreased synthesis caused by the liver disease. A problem frequently arises when correcting thrombocytopenia and a defect of coagulation factors in the presence of severe hemorrhages and active DIC. In such cases, although this sounds paradoxical, application of the replacement therapy while under continuous heparin infusion cover can be useful.

When replacement therapy is going to be used, it is important to elucidate which factors are deficient and which could contribute to the persistence of hemorrhage. Only the necessary products should be administered; in other words, replacement therapy must be as specific as possible.

When the use of replacement therapy has been decided, the best choice is to infuse FFP, provided that all coagulation factors and inhibitors are present,<sup>125</sup> at a dose of 10-15 mL/kg weight. When FFP alone does not give a fibrinogen level above 0.5 g/L, cryoprecipitate can then be infused at a ratio of 10 U for every 2 or 3 U of plasma. Transfusing platelet concentrates at 1-2 U/kg weight is appropriate when the platelet count is less than 20,000/ $\mu$ L or if there is major bleeding and the platelet count is less than 50,000/ $\mu$ L.

Neither factor VIII nor factor IX concentrates should be infused in these patients provided that factor VIII levels are not reduced in DIC.<sup>9,77</sup> Factor IX concentrate is potentially thrombogenic and may itself cause DIC because it contains activated clotting factors.<sup>126</sup> Infusing hemoderivatives such as cryoprecipitates, which are fibronectin-rich,<sup>127</sup> has been suggested to be useful because a decrease in fibronectin levels has been shown in patients with DIC<sup>128</sup> which could subsequently reduce the clearance of activated coagulation factors.<sup>129</sup>

### **Heparin and other thrombin inhibitor therapy**

The role of heparin in the treatment of DIC is very controversial: while some physicians consider that heparin can contribute to an increase in severe hemorrhagic complications, others claim this drug is useful because of its ability to prevent the formation of thrombi and subsequent organ dysfunction caused by the ischemia. Heparin could also attenuate hemorrhagic complications by diminishing consumption of factors and the secondary fibrinolysis.

There are no objective data demonstrating that heparin reduces morbidity and mortality in acute DIC. Controlled prospective studies have not been performed and one should be cautious when drawing conclusions from retrospective analyses. In fact, contradictory results have been obtained from such analyses: while some reports in the literature support the claim that heparin reduces the incidence of hemorrhage and increases survival in patients with DIC,<sup>8</sup> others show that the use of heparin has no beneficial effects.<sup>119,120</sup>

It is now, however, beyond all doubt that heparin

can be useful in the treatment of the acute DIC caused by some specific diseases. The most typical example is purpura fulminans, in which heparin prevents tissue damage due to thrombosis.<sup>46-49</sup> The usefulness of heparin is also well established in patients with DIC caused by cancer, especially in chronic DIC associated with recurrent thrombosis<sup>45,130</sup> but also when it is associated with hyperfibrinolysis and hemorrhage.<sup>131</sup> Chronic DIC secondary to other causes such as large aneurysms,<sup>132</sup> Kasabach-Merritt syndrome<sup>133</sup> and a retained dead fetus<sup>134,135</sup> may also improve with heparin. A few studies have shown that heparin is useful in controlling the DIC associated with APL,<sup>136-139</sup> although two other large retrospective studies were not able to demonstrate that treatment with heparin improves results in this condition.<sup>127,140</sup> Heparin does not seem to exert beneficial effects in other situations such as sepsis, obstetric complications (except in retained dead fetus syndrome) or liver disease.

Even when there is agreement over the usefulness of heparin, there is still controversy about the best dose to give and the way to give it. It seems that low doses, in the range of 5-10 U/kg/h given by continuous intravenous infusion, should be enough to reverse the coagulopathy in patients with acute DIC.<sup>72,121,141,142</sup> Some authors claim that the subcutaneous route is as efficient as intravenous infusion.<sup>3,6</sup> Finally, the use of low molecular weight heparins has been shown to be useful in experimental models of endotoxin-induced DIC in rabbits,<sup>143</sup> although it has only been evaluated in one clinical study which showed that 50% of the treated patients improved.<sup>144</sup>

Since heparin requires ATIII to exert its anticoagulant activity and ATIII levels can be low in DIC, heparin therapy could sometimes be inefficient in these patients. The use of direct thrombin inhibitors could give better results because their activity is unrelated to ATIII levels. The direct thrombin inhibitor hirudin has been experimentally tested with good results in a few animal models,<sup>145-148</sup> although its clinical benefit has only been evaluated in two small studies which cannot be considered conclusive.<sup>149,150</sup>

The infusion of ATIII concentrates, with or without heparin, has been shown to be useful in experimental models of DIC in rabbits<sup>27</sup> and dogs.<sup>30</sup> Moreover, some clinical studies have described a reduction in mortality together with disappearance of the DIC. However, the number of patients included in these studies is small which makes it difficult to draw definitive conclusions, although the available data support the efficacy of this treatment.<sup>151-158</sup> A large, prospective and randomized clinical trial should, therefore, be performed to demonstrate clearly whether the use of AT-III concentrates is appropriate as a treatment of patients with DIC.

The infusion of activated protein C concentrates has been shown to prevent DIC and mortality in an animal model of sepsis;<sup>35</sup> moreover, an anti-protein C monoclonal antibody previously administered pro-

voked a more severe DIC pattern.<sup>159</sup> It has been proposed that the presence of activated protein C not only serves as an anticoagulant but also protects against the lethal effect of endotoxin shock.<sup>160</sup> These studies strongly suggest a beneficial role for protein C replacement therapy in patients with DIC. There is very little clinical experience with the use of protein C concentrates in patients with DIC so far, but the preliminary results appear promising.<sup>161-162</sup>

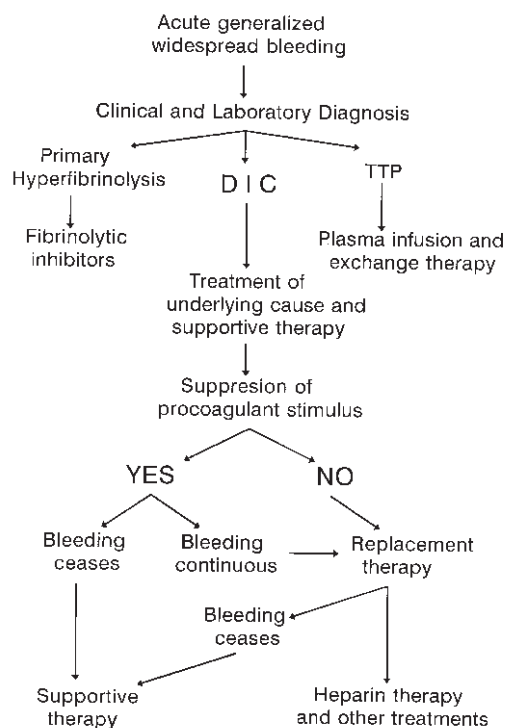
### Other treatment modalities

Antifibrinolytic drugs such as EACA and tranexamic acid can diminish bleeding caused by hyperfibrinolysis. However, they may also unmask underlying coagulation and convert a bleeding disorder into a thrombotic condition, which have made many authors consider their use contraindicated in DIC.<sup>163-164</sup> Nevertheless, the beneficial effects of antifibrinolytic drugs can be greater than the risks when DIC is associated with hyperfibrinolysis and intense hemorrhagic episodes, especially when there is not much thrombin formation, as frequently happens in patients with APL. Some reports describe that these patients can be successfully treated with EACA or tranexamic acid to reduce hemorrhage with no increase in the risk of thrombosis.<sup>165-167</sup> Antifibrinolytic drugs have also been successfully used in patients with DIC associated with Kasabach-Merritt syndrome<sup>168-170</sup> and in patients who have laboratory evidence of hyperfibrinolysis with depletion of physiologic plasmin inhibitors but who bleed despite aggressive replacement therapy.<sup>84</sup> When used to treat DIC, antifibrinolytic drugs are usually given in conjunction with heparin to minimize the risk of thrombosis. Doses of 10-15 mg/kg/h of EACA are appropriate.<sup>165</sup> In the case of patients with giant hemangiomas the treatment with antifibrinolytic drugs is not associated with heparin.

Products such as gabexate, aprotinin, DDAVP, t-PA or a genetically engineered mutant,  $\alpha_1$ -antitrypsin Pittsburgh, a mutant serpin that inhibits thrombin, factor XIIa, factor XIa, and kallikrein have been used, but in purely experimental animal models; their usefulness in DIC patients has only been tested in very occasional anecdotally reported cases.<sup>171-175</sup>

It has recently been suggested that intervention at the level of endotoxins or cytokines (e.g. by specific monoclonal antibodies) may result in treatment or prevention of DIC, specially in patients with sepsis. There are some studies, both experimental and clinical, in which anti-endotoxin polyclonal or monoclonal antibodies, anti-TNF- $\alpha$  antibodies, TNF- $\alpha$  receptor:Fc recombinant fusion protein, recombinant IL-1 receptor antagonist, anti-interleukin-6 antibodies, pentoxifylline or ibuprofen have been used. The results, although not totally conclusive, are quite promising in some cases, which is leading many researchers to focus on the potential beneficial role of these agents.<sup>176-192</sup> New more specific strategies





**Figure 2.** Algorithm for management of acute generalized, widespread bleeding.

aimed at the treatment or prevention of DIC may include inhibition of the extrinsic pathway of blood coagulation; to this end anti-tissue factor and anti-factor VIIa antibodies have been used and the effect of immunodepletion of TFPI or administration of recombinant TFPI have been studied in a variety of experimental models, with promising results which suggest that these strategies could also be successful when applied to human DIC.<sup>14,15,25,192-194</sup>

To conclude, until these new strategies clearly show their efficacy, the treatment of acute generalized, widespread bleeding in general and the specific treatment of DIC must be decided according to a scheme similar to that given in Figure 2.

### Contributions and Acknowledgments

ER was responsible for the conception of this review article and for the writing of the paper. All the authors contributed equally to the writing of the paper and revising it critically.

### Funding

This work was partially supported by a grant from the DGI-CYT of the Ministerio de Educación y Ciencia, Spain, n. PM94-1553.

### Disclosures

*Conflict of interest: none.*

*Redundant publications: no substantial overlapping with previous papers.*

### Manuscript processing

*Manuscript received April 24, 1998; accepted August 12, 1998.*

### References

- McKay DG. Disseminated intravascular coagulation. New York: Harper-Hoeber; 1965.
- Bick RL. Disseminated intravascular coagulation and related syndromes. Boca Raton: Harper-Hoeber; 1983.
- Bick RL. Disseminated intravascular coagulation and related syndromes: a clinical review. *Semin Thromb Hemostas* 1988; 14:299-388.
- Baker WF Jr. Clinical aspects of disseminated intravascular coagulation: a clinician's point of view. *Semin Thromb Hemost* 1989; 15:1-57.
- Williams EC, Mosher DF. Disseminated intravascular coagulation. In: Hoffman R, Benz EJ, Shattil SJ, Furie B, Dohen HJ eds. *Hematology. Basic principles and practice*. New York: Churchill Livingstone; 1991. p. 1394-405.
- Bick RL. Disseminated intravascular coagulation: objective clinical and laboratory diagnosis, treatment, and assessment of therapeutic response. *Semin Thromb Haemostas* 1996; 22:69-88.
- Siegal T, Seligsohn V, Aghal E, Modan M. Clinical and laboratory aspects of disseminated intravascular coagulation (DIC): a study of 118 cases. *Thromb Haemostas* 1978; 39:122-34.
- Colman RW, Robboy SJ, Minna JD. Disseminated intravascular coagulation: a reappraisal. *Annu Rev Med* 1979; 30:359-74.
- Spero JA, Lewis JH, Hasiba V. Disseminated intravascular coagulation. Findings in 346 patients. *Thromb Haemostas* 1980; 43:28-33.
- Gimbrone M. Vascular endothelium in hemostasis and thrombosis. New York: Churchill Livingstone; 1986.
- Moore KL, Andreoli SP, Esmon NL, Esmon CT, Bang UN. Endotoxin enhances tissue factor and suppresses thrombomodulin expression of human vascular endothelium *in vitro*. *J Clin Invest* 1987; 79:124-30.
- Bauer K, ten Cate H, Barzegar S, Spriggs DR, Sherman ML, Rosenberg RD. Tumor necrosis factor infusions have a procoagulant effect on the hemostatic mechanism of humans. *Blood* 1989; 74:165-72.
- van der Poll T, Buller HR, ten Cate H, et al. Activation of coagulation after administration of tumor necrosis factor to normal subjects. *N Engl J Med* 1990; 322:1622-7.
- Warr TA, Rao LV, Rapaport SI. DIC in rabbits induced by administration of endotoxin or tissue factor: effect of anti-tissue factor antibodies and measurement of plasma extrinsic pathway inhibitor activity. *Blood* 1990; 75:1481-9.
- Taylor FB Jr, Chang A, Ruf W, et al. Lethal E coli septic shock is prevented by blocking tissue factor with monoclonal antibody. *Cir Shock* 1991; 33:127-34.
- Pixley RA, de la Cadena R, Page JD, et al. Activation of the contact system in lethal hypotensive bacteremia in a baboon model. *Am J Pathol* 1992; 140:897-906.
- Pixley RA, De la Cadena R, Page JD, et al. The contact system contributes to hypotension but not disseminated

- nated intravascular coagulation in lethal bacteremia: in vivo use of a monoclonal anti-factor XII antibody to block contact activation in baboons. *J Clin Invest* 1993; 91:61-8.
18. Levi M, Hack CE, de Boer JP, Brandjes DPM, Buller HR, ten Cate JW. Reduction of contact activation related fibrinolytic activity in factor XII deficient patients: further evidence for the role of the contact system in fibrinolysis in vivo. *J Clin Invest* 1991; 88: 1155-60.
  19. Martínez Brotons F, Oncins JR, Mesres J, Amargós V, Reynaldo C. Plasma kallikrein-kinin system in patients with uncomplicated sepsis and septic shock. Comparison with cardiogenic shock. *Thromb Haemostas* 1987; 58:709-13.
  20. Beutler B, Cerami A. Cachectin, more than a tumor necrosis factor. *N Engl J Med* 1987; 316:379-85.
  21. Michie HR, Manogue KR, Spriggs DR, et al. Detection of circulating tumor necrosis factor after endotoxin administration. *N Engl J Med* 1988; 318:1481-6.
  22. Van Deventer SSH, Buller HR, ten Cate JW, Aarden LA, Hack CE, Sturk A. Experimental endotoxemia in humans: analysis of cytokine release and coagulation, fibrinolytic, and complement pathways. *Blood* 1990; 76:2520-6.
  23. Van Deventer SSH, Hart M, van der Poll T, Hack CE, Aarden LA. Endotoxin and tumor necrosis factor- $\alpha$ -induced interleukin-8 release in humans. *J Infect Dis* 1993; 167:461-4.
  24. Bone RC. Modulators of coagulation. A critical appraisal of their role in sepsis. *Arch Intern Med* 1992; 152:1381-9.
  25. Billiau A, Vandekerckhove F. Cytokines and their reactions with other inflammatory mediators in the pathogenesis of sepsis and septic shock. *Eur J Clin Invest* 1991; 21:559-73.
  26. Colucci M, Páramo JA, Collen D. Generation in plasma of a fast-acting inhibitor of plasminogen activator in response to endotoxin stimulation. *J Clin Invest* 1985; 75:818-24.
  27. Gómez C, Páramo JA, Colucci M, Rocha E. Effect of heparin and/or antithrombin III on the generation of endotoxin-induced plasminogen activator inhibitor. *Thromb Haemostas* 1989; 62:694-8.
  28. Páramo JA, Fernández FJ, Rocha E. Plasminogen activator inhibitor activity in bacterial infection. *Thromb Haemostas* 1988; 59:451-4.
  29. Páramo JA, Pérez JL, Serrano M, Rocha E. Types 1 and 2 plasminogen activator inhibitor and tumor necrosis factor alpha in patients with sepsis. *Thromb Haemostas* 1990; 64:3-6.
  30. Mammen EF, Miyakama T, Phillips TF, et al. Human antithrombin concentrates and experimental DIC. *Semin Thromb Hemostas* 1985; 11:373-83.
  31. Fourrier F, Chopin C, Goudemand J, et al. Septic shock, multiple organ failure and disseminated intravascular coagulation. Compared patterns of antithrombin III, protein C, and protein S deficiencies. *Chest* 1992; 101:816-23.
  32. Vicente V, España F, Tavernero D, et al. Evidence of activation of the protein C pathway during acute vascular damage induced by Mediterranean spotted fever. *Bood* 1991; 78:416-22.
  33. Madden RM, Ward M, Marlar RA. Protein C activity levels in endotoxin-induced DIC in a dog model. *Thromb Res* 1989; 55:297-307.
  34. Marlar RA, Endres-Brooks J, Mille C. Serial studies of protein C and its plasma inhibitor in patients with DIC. *Blood* 1985; 66:59-63.
  35. Taylor FB, Chang A, Esmon CT, D'Angelo A, Vignano D'Angelo S, Blick KE. Protein C prevents the coagulopathic and lethal effects of *Escherichia coli* infusion in the baboon. *J Clin Invest* 1987; 79:918-25.
  36. Taylor FB, Chang A, Ferrel G, et al. C4b-binding protein exacerbates the host response to *Escherichia coli*. *Blood* 1991; 78:357-63.
  37. Sandset M, Roise O, Aasen AO, Abildgaard V. Extrinsic pathway inhibitor (EPI) in post-operative/post-traumatic septicemia. Increased levels in fatal cases. *Haemostasis* 1989; 19:189-95.
  38. Warr TA, Rao LV, Rapaport SI. Human plasma extrinsic pathway inhibitor activity: II. Plasma levels in DIC and hepatocellular disease. *Blood* 1989; 74:994-8.
  39. Bajaj MS, Rana SV, Wysolmerski RB, Bajaj SP. Inhibitor of the Factor VIIa-tissue factor complex is reduced in patients with DIC but not in patients with severe hepatocellular disease. *J Clin Invest* 1987; 79: 1874-8.
  40. Sandset PM, Warn-Cramer BJ, Maki SL, Rapaport SI. Immunodepletion of extrinsic pathway inhibitor sensitizes rabbits to endotoxin-induced intravascular coagulation and the generalized Shwartzman reaction. *Blood* 1991; 78:1496-502.
  41. Baglin T. Disseminated intravascular coagulation: diagnosis and treatment. *Br Med J* 1996; 312:683-7.
  42. Marder VJ, Feinstein DI, Francis CW, Coman RW. Consumptive thrombohemorrhagic disorders. In: Colman RW, Hirsh J, Marder VJ, Salzman EW, eds. Hemostasis and thrombosis: basic principles and clinical practice. 3<sup>rd</sup> ed. Philadelphia: Lippincott Co, 1994. p. 1023-63.
  43. Bick RL. Disseminated intravascular coagulation. Objective criteria for diagnosis and management. *Med Clin North Am* 1994; 78:511-43.
  44. Robboy SJ, Minna DJ, Colman RW, et al. Pulmonary hemorrhage syndrome as a manifestation of DIC: Analysis of 10 cases. *Chest* 1973; 63:718-21.
  45. Sack G, Levin J, Bell W. Trusseau's syndrome and other manifestations of chronic disseminated coagulopathy in patients with neoplasms: clinical, pathophysiologic, and therapeutic features. *Medicine* 1977; 56:1-37.
  46. Francis RB. Acquired purpura fulminans. *Semin Thromb Hemostas* 1990; 16:310-25.
  47. Giraud T, Dhainaut JF, Schremmer B, et al. Adult overwhelming meningococcal purpura. A study of 35 cases; 1977-1989. *Arch Intern Med* 1991; 151:310-6.
  48. Spicer T, Rau J. Purpura fulminans. *Am J Med* 1976; 61:566-71.
  49. Molos M, Hall J. Symmetrical peripheral gangrene and disseminated intravascular coagulation. *Arch Dermatol* 1985; 121:1057-61.
  50. Powars D, Rodgers Z, Pateh M, McGehee W, Francis R. Purpura fulminans in meningococemia: association with acquired deficiencies of proteins C and S. *N Engl J Med* 1987; 317:571-2.
  51. Margaretten W, Nakai H, Landing B. Septicemic adrenal hemorrhage. *Am J Dis Child* 1963; 105:64-9.
  52. Maltin RA, Gary EN. Acute cortical necrosis. Case report and review of the literature. *Am J Med* 1974; 56:110-8.
  53. Colman R, Robboy S, Minna J. Disseminated intravascular coagulation; an approach. *Am J Med* 1972; 52: 679-87.
  54. Alkaersig N, Fletcher A, Sherry S. Pathogenesis of the coagulation defect developing during pathological plasma proteolytic ("fibrinolytic") states. II. The significance, mechanism and consequences of defective fibrin polymerization. *J Clin Invest* 1962; 41:917-34.
  55. Pareti FI, Capitanio A, Mannucci PM. Acquired storage-pool disease in platelets during DIC. *Blood* 1976; 48:511-5.
  56. Neame P, Kelton J, Walker I, Stewart I, Nossel H, Hirsh J. Thrombocytopenia in septicemia: the role of dis-

- seminated intravascular coagulation. *Blood* 1980; 56:88-92.
57. Poskitt T, Poskitt P. Thrombocytopenia of sepsis. The role of circulating IgG-containing immune complexes. *Arch Intern Med* 1985; 145:891-4.
  58. Carr J, McKinney M, McDonagh J. Diagnosis of disseminated intravascular coagulation. Role of D-dimer. *Am J Clin Pathol* 1989; 91:280-7.
  59. Prisco D, Paniccia R, Bonechi F, et al. Evaluation of a new method for the selective measurement of fibrin and fibrinogen products. *Thromb Res* 1989; 56:547-51.
  60. Bick RL, Baker W. Diagnostic efficacy of the D-dimer assay in DIC and related disorders. *Thromb Res* 1992; 65:785-90.
  61. Lane DA, Preston FE, Van Ross ME, Kakkar VV. Characterization of serum fibrinogen and fibrin fragments produced during disseminated intravascular coagulation. *Br J Haematol* 1978; 40:609-15.
  62. Elms MJ, Bunce IH, Bundesen PG, et al. Measurement of cross-linked fibrin degradation products - an immunoassay using monoclonal antibodies. *Thromb Haemostas* 1983; 50:591-4.
  63. Goldhaber SZ, Vaughan DE, Tumei SS, Loscalzo J. Utility of cross-linked FDP in the diagnosis of pulmonary embolism. *Am Heart J* 1988; 116:505-8.
  64. Bounameaux H, Schneider PA, Reber G, et al. Measurement of plasma D-dimer for diagnosis of deep venous thrombosis. *Am J Clin Pathol* 1989; 91:82-5.
  65. Lopez Y, Páramo JA, Valentí JR, Pardo F, Montes R, Rocha E. Hemostatic markers in surgery: a different fibrinolytic activity may be of pathophysiological significance in orthopedic versus abdominal surgery. *Int J Clin Lab Res* 1997; 27:233-7.
  66. Rocha E, Páramo JA, Fernández FJ, et al. Clotting activation and impairment of fibrinolysis in malignancy. *Thromb Res* 1989; 54:699-707.
  67. Gurewich W, Hutchinson E. Detection of intravascular coagulation by a serial-dilution protamine sulphate test. *Ann Intern Med* 1971; 75:895-902.
  68. Mattias FR, Reinicke R, Heene DL. Affinity chromatography and quantitation of soluble fibrin from plasma. *Thromb Res* 1977; 10:365-84.
  69. Wiman B, Ranby M. Determination of soluble fibrin in plasma by a rapid and quantitative spectrophotometric assay. *Thromb Haemostas* 1986; 55:189-93.
  70. Francis CW, Connaghan DG, Scott WL, Marder VJ. Increased plasma concentration of cross-linked fibrin polymers in acute myocardial infarction. *Circulation* 1987; 75:1170-7.
  71. Bredbacka S, Blomback M, Wiman B, Pelzer H. Laboratory methods for detecting disseminated intravascular coagulation (DIC): new aspects. *Acta Anaesthesiol Scand* 1993; 37:125-30.
  72. Bick RL, Bick M, Fekete L. Antithrombin III patterns in disseminated intravascular coagulation. *Am J Clin Pathol* 1980; 73:577-83.
  73. Bick RL. Clinical relevance of antithrombin III. *Semin Thromb Haemostas* 1982; 8:276-87.
  74. Asakura H, Saito M, Ito K, et al. Levels of thrombin-antithrombin III complex in plasma in cases of acute promyelocytic-leukemia. *Thromb Res* 1988; 50:895-9.
  75. Visudhipan S, Piankijagum A, Sathayapraser P, Mittrachai N. Erythrocyte fragmentation in disseminated intravascular coagulation and other diseases. *N Engl J Med* 1983; 309:113.
  76. Rodeghiero S, Castaman G, Tonellato L, Dini E. Erythrocyte fragmentation in disseminated intravascular coagulation (DIC) in acute leukemia. *Br J Haematol* 1985; 61:593-4.
  77. Lombardi R, Mannucci PM, Seghatchian M, Garcia V, Coppola R. Alterations of factor VIII von Willebrand factor in clinical conditions associated with an increase in its plasma concentration. *Br J Haematol* 1981; 46:61-8.
  78. Bauer K, Rosenberg G. Thrombin generation in acute promyelocytic leukemia. *Blood* 1984; 64:791-6.
  79. Okamoto K, Tahaki A, Takeda H, Katoh K, Ohsato K. Coagulopathy in disseminated intravascular coagulation due to abdominal sepsis: Determination of prothrombin fragment 1+2 and other markers. *Haemostasis* 1992; 22:17-24.
  80. Takahashi H, Tatewaki W, Wada K, Hanano M, Shibato A. Thrombin vs. Plasmin generation in disseminated intravascular coagulation associated with various underlying disorders. *Am J Hematol* 1990; 33:90-5.
  81. Cronlund M, Hardin J, Burton J, Lee L, Haber I, Bloch KJ. Fibrinopeptide A in plasma of normal subjects and patients with disseminated intravascular coagulation in systemic lupus erythematosus. *J Clin Invest* 1976; 58:142-51.
  82. Douglas JT, Shah M, Lowe GDO, Belch JJ, Forbes CD, Prentice CRM. Plasma fibrinopeptide A and beta-thromboglobulin in pre-eclampsia and pregnancy hypertension. *Thromb Haemostas* 1982; 47:54-5.
  83. Nossel HL. Radioimmunoassay of fibrinopeptides in relation to intravascular coagulation and thrombosis. *N Engl J Med* 1976; 295:428-32.
  84. Williams E. Plasma  $\alpha$ 2 antiplasmin activity: role in the evaluation and management of fibrinolytic states and other bleeding disorders. *Arch Intern Med* 1989; 149:1769-72.
  85. Booth N, Bennett B. Plasmin- $\alpha$ 2 antiplasmin complexes in bleeding disorders characterized by primary or secondary fibrinolysis. *Br J Haematol* 1984; 56:545-56.
  86. Harpel P.  $\alpha$ 2-plasmin inhibitor and  $\alpha$ 2-macroglobulin-plasmin complexes in plasma. *J Clin Invest* 1981; 68:46-55.
  87. Takahashi H, Hanano M, Takizawa S, Shibata A. Plasmin- $\alpha$ 2-plasmin inhibitor complex in plasma of patients with disseminated intravascular coagulation. *Am J Hematol* 1988; 28:162-6.
  88. Weitz J, Koehn J, Canfield R, et al. Development of a radioimmunoassay for the fibrinogen-derived peptide B $\beta$  1-42. *Blood* 1986; 67:1014-22.
  89. Nossel H. Fibrinogen proteolysis by thrombin, plasmin and platelet release in relation to disseminated intravascular coagulation. *Bibl Haematol* 1983; 49:151-62.
  90. García Frade LJ, Landin L, García Avello A, Lorente JA, Torrado MC. PAI and D-D dimer levels are related to severity of injury in trauma patients. *Fibrinolysis* 1991; 5:253-6.
  91. Zahavi J, Kakkar VV. B-Thromboglobulin a specific marker of *in vivo* platelet release reaction. *Thromb Haemostas* 1980; 44:23-9.
  92. Alperin J. Coagulopathy caused by vitamin K deficiency in critically ill patients. *JAMA* 1987; 258:1916-9.
  93. Corrigan J. Vitamin K-dependent coagulation factors in Gram-negative septicemia. *Am J Dis Child* 1984; 138:240-2.
  94. Mammen EF, Koets MH, Wolk LW, et al. Hemostasis changes during cardiopulmonary bypass surgery. *Semin Thromb Hemostas* 1985; 11:281-92.
  95. Hewson JR, Neame PB, Kumar N, et al. Coagulopathy related to dilution and hypertension during massive transfusion. *Crit Care Med* 1985; 13:387-91.
  96. Clavarella D, Reed R, Counts R, et al. Clotting factor levels and the risk of diffuse microvascular bleeding in the massively transfused patients. *Br J Haematol* 1987; 67:165-8.
  97. Rocha E, Marín J, López Borrasca A. Cirrosis hepática

- ca y aclaramiento de activadores de la fibrinólisis. *Rev Clin Esp* 1976; 142:144-6.
98. Rocha E, Marín J, López Borrasca A. Factores de tromboplastinoformación y cirrosis hepática. *Sangre* 1975; 20:38-42.
  99. Páramo JA, Rifón J, Fernández J, Cuesta B, Rocha E. Thrombin activation and increased fibrinolysis in patients with chronic liver disease. *Blood Coagul Fibrinol* 1991; 2:227-30.
  100. Páramo JA, Rocha E. Hemostasis in advanced liver disease. *Semin Thromb Hemostas* 1993; 19:184-90.
  101. Straub PW. Diffuse intravascular coagulation in liver disease? *Semin Thromb Hemostas* 1977; 4:29-39.
  102. Jaffe E, Nachman R, Merskey C. Thrombotic thrombocytopenic purpura - coagulation parameters in twelve patients. *Blood* 1973; 42:499-507.
  103. Takahashi H, Tatewaki W, Wada K, Shibata A. Thrombin generation in patients with thrombotic thrombocytopenic purpura. *Am J Hematol* 1989; 32:255-7.
  104. Harker L, Slichter S. Platelet and fibrinogen consumption in man. *N Engl J Med* 1972; 287:999-1005.
  105. Monteagudo J, Pereira A, Reverter JC, et al. Thrombin generation and fibrinolysis in the thrombotic thrombocytopenic purpura and the hemolytic-uremic syndrome. *Thromb Haemostas* 1991; 66:515-9.
  106. Lian EC-Y, Miu PTK, Siddiqui FA. Inhibition of platelet-aggregating activity in TTP plasma by normal adult immunoglobulin G. *J Clin Invest* 1984; 73:548-55.
  107. Siddiqui FA, Lian EC. Novel platelet-agglutinating protein from TTP plasma. *J Clin Invest* 1985; 76:1330-7.
  108. Moake JL, Rudy CK, Troll JH, et al. Unusually large plasma Factor VIII: von Willebrand factor multimers in chronic relapsing TTP. *N Engl J Med* 1982; 307:1432-5.
  109. Moake JL, Byrnes JL, Troll JH, et al. Abnormal VIII: von Willebrand factor patterns in the plasma of patients with HUS. *Blood* 1984; 64:592-8.
  110. Pereira A, Monteagudo J, Bono A, López-Guillermo A, Ordinas A. Effect of splenectomy on von Willebrand factor multimeric structure in thrombotic thrombocytopenic purpura refractory to plasma exchange. *Blood Coagul Fibrinol* 1993; 4:783-6.
  111. Byrnes JJ, Khurana M. Treatment of TTP with plasma. *N Engl J Med* 1977; 297:1386-9.
  112. Bukowski RM, King JW, Hewlett JS. Plasmapheresis in the treatment of TTP. *Blood* 1977; 50:413-7.
  113. Aster RH. Plasma therapy for TTP: sometimes it works, but why? *N Engl J Med* 1985; 312:985-7.
  114. Gralnick HR, Greipp P. Thrombosis with epsilon-aminocaproic acid therapy. *Am J Clin Pathol* 1971; 56:151-4.
  115. Suarez M, Sangro B, Herrero JI, et al. Effectiveness of aprotinin in orthotopic liver transplantation. *Semin Thromb Hemostas* 1993; 19:292-6.
  116. Aoki N, Sakata Y, Matsuda M, Tateno K. Fibrinolytic states in a patient with congenital deficiency of  $\alpha$ 2-plasmin inhibitor. *Blood* 1980; 55:483-8.
  117. Schleaf RR, Higgins DL, Pillemer E, Lewitt J. Bleeding diathesis due to decreased functional activity of type 1 plasminogen activator inhibitor. *J Clin Invest* 1989; 83:1747-52.
  118. Bennett B, Booth N, Croll A, Dawson A. The bleeding disorder in acute promyelocytic leukemia: fibrinolysis due to u-PA rather than defibrination. *Br J Haematol* 1989; 71:511-7.
  119. Mant M, King E. Severe, acute disseminated intravascular coagulation. A reappraisal of its pathophysiology, clinical significance and therapy based on 47 patients. *Am J Med* 1979; 67:557-63.
  120. Al-Mondhiry H. Disseminated intravascular coagulation. Experience in a major cancer center. *Thromb Diath Haemorrh* 1975; 34:181-93.
  121. Feinstein DI. Treatment of disseminated intravascular coagulation. *Semin Thromb Hemostas* 1988; 14:351-62.
  122. Bick RL. Disseminated intravascular coagulation: A clinical/laboratory study of 48 patients. *Ann NY Acad Sci* 1981; 370:843-50.
  123. Goldberg M, Ginsburg D, Mayer R, et al. Is heparin necessary during induction chemotherapy for patients with acute promyelocytic leukemia? *Blood* 1987; 69:187-91.
  124. Wong VK, Hitchcock W, Mason WH. Meningococcal infections in children: a review of 100 cases. *Pediatr Infect Dis* 1989; 8:224-7.
  125. NIH consensus conference. Fresh-frozen plasma. Indications and risks. *JAMA* 1985; 253:551-3.
  126. Conlan MG, Hoets WK. Disseminated intravascular coagulation and hemorrhage in hemophilia B following elective surgery. *Am J Hematol* 1990; 35:203-7.
  127. Saba TM, Blumenstock FA, Scovill WA, et al. Cryoprecipitate reversal of opsonic alpha-2-surface binding glycoprotein deficiency in septic surgical and trauma patients. *Science* 1978; 201:622-4.
  128. Cembrowski GS, Mosher DF. Plasma fibronectin concentration in patients with acquired consumptive coagulopathies. *Thromb Res* 1984; 36:437-45.
  129. Mosesson MW, Amrani DL. The structure and biologic activities of plasma fibronectin. *Blood* 1980; 56:145-58.
  130. Bell W, Starksen N, Tong S, Porterfield J. Trousseau's syndrome: devastating coagulopathy in the absence of heparin. *Am J Med* 1985; 79:423-30.
  131. Straub P, Riedler G, Frick P. Hypofibrinogenemia in metastatic carcinoma of the prostate: suppression of systemic fibrinolysis by heparin. *J Clin Pathol* 1967; 20:152-7.
  132. Diskin CJ, Weitberg AB. Minidose heparin therapy. Treatment of chronic intravascular coagulation syndrome. *Arch Intern Med* 1980; 140:263-6.
  133. Mewes T, Moldenhauer H, Pfeifer J, Pavenberg J. The Kasabach-Merrit syndrome: severe bleeding disorder caused by celiac arteriography - reversal by heparin treatment. *Am J Gastroenterol* 1989; 84:965-71.
  134. Romero R, Duffy TP, Berkowitz RL, Chang E, Hobbs JC. Prolongation of a preterm pregnancy complicated by death of a single twin in utero and disseminated intravascular coagulation. *N Engl J Med* 1984; 310:772-4.
  135. Lerner R, Margolin M, Slate WG, Rosenfeld H. Heparin in the treatment of hypofibrinogenemia complicating fetal death in utero. *Am J Obstet Gynecol* 1967; 97:373-8.
  136. Hoyle CF, Swisky DM, Freedman L, Hayhoe FGJ. Beneficial effect of heparin in the management of patients with APL. *Br J Haematol* 1988; 68:283-9.
  137. Kantarjian H, Keating M, Walters R, et al. Acute promyelocytic leukemia. M.D. Anderson Hospital experience. *Am J Med* 1986; 80:789-97.
  138. Gralnick H, Bagley J, Abrell E. Heparin treatment for the hemorrhagic diathesis of acute promyelocytic leukemia. *Am J Med* 1982; 52:167-74.
  139. Collins A, Bloomfield C, Petersen B, McKenna R, Edson E. Acute promyelocytic leukemia. Management of the coagulopathy during daunorubicin-prednisone remission induction. *Arch Intern Med* 1978; 138:1677-80.
  140. Rodeghiero F, Avisati G, Castaman G, Barbui T, Mandelli F. Early deaths and anti-hemorrhagic treatments in acute promyelocytic leukemia. A GIMEMA retrospective study in 268 consecutive patients. *Blood* 1990; 75:2112-7.
  141. Gurewicz V, Lipinski B. Low-dose heparin in the treat-



- ment of disseminated intravascular coagulation. *Am J Med Sci* 1977; 274:83-6.
142. Feinstein D. Diagnosis and management of disseminated intravascular coagulation: the role of heparin therapy. *Blood* 1982; 6:284-7.
  143. Hermida J, Montes R, Páramo JA, Rifón J, Muñoz C, Rocha E. Effect of low molecular weight heparin (LMWH) with and without antithrombin III (ATIII) on endotoxin-induced intravascular coagulation in rabbits [abstract]. *Haemostasis* 1996; 26(Suppl 3):406.
  144. Oguma Y, Sakuragawa N, Maki M, Hasegawa H, Nakagawa M. Treatment of disseminated intravascular coagulation with low molecular weight heparin. *Semin Thromb Hemostas* 1990; 16:34-40.
  145. Dickneite G, Czech J, Keuper H. Formation of fibrin monomers in experimental disseminated intravascular coagulation and its inhibition by recombinant hirudin. *Cir Shock* 1994; 42:183-9.
  146. Dickneite G, Czech J. Combination of antibiotic treatment with the thrombin inhibitor recombinant hirudin for the therapy of experimental *Klebsiella pneumoniae* sepsis. *Thromb Haemostas* 1994; 71:768-72.
  147. Zawilska K, Zozulinska M, Turowiecka Z, et al. The effects of a long-acting recombinant hirudin (PEG-hirudin) on experimental disseminated intravascular cephalothin (DIC) in rabbits. *Thromb Res* 1993; 69: 315-20.
  148. Hermida J, Montes R, Páramo JA, Rocha E. Endotoxin-induced disseminated intravascular coagulation in rabbits: Effect of recombinant hirudin on hemostatic parameters, fibrin deposits, and mortality. *J Clin Lab Med* 1998; 131:77-83.
  149. Saito M, Asakura H, Jokaji H, et al. Recombinant hirudin for the treatment of disseminated intravascular coagulation in patients with haematological malignancy. *Blood Coagul Fibrinolysis* 1995; 6:60-4.
  150. Breddin HK, Markwardt F. Clinical experience with hirudin in disseminated intravascular coagulation [abstract]. *Thromb Haemostas* 1993; 69:1299.
  151. Schipper H, Jenkins C, Kahle T, ten Cate J. Antithrombin III transfusion in disseminated intravascular coagulation. *Lancet* 1978; 1:854-6.
  152. Fourrier F, Lestavel P, Chopin C, et al. Meningococemia and purpura fulminans in adults: acute deficiencies of proteins C and S and early treatment with antithrombin III concentrates. *Intensive Care Med* 1990; 16:121-4.
  153. Blauhut B, Kramar H, Vinazzer H, Bergmann H. Substitution of ATIII in shock and DIC: A randomized study. *Thromb Res* 1985; 39:81-9.
  154. Hanada T, Abe T, Takita H. ATIII concentrates for treatment of DIC in children. *Am J Pediatr Hematol Oncol* 1985; 7:3-8.
  155. von Kries R, Stannigel H, Gobel U. Anticoagulant therapy by continuous heparin-ATIII infusion in newborns with DIC. *Eur J Pediatr* 1985; 144:191-4.
  156. Harper P. The clinical use of antithrombin concentrate in septicemia. *Br J Hosp Med* 1994; 52:571-4.
  157. Fourrier F, Chopin C, Huart J, Ruge I, Caron C, Goudemand J. Double-blind, placebo-controlled trial of antithrombin III concentrates in septic shock with disseminated intravascular coagulation. *Chest* 1993; 104:882-8.
  158. Vinazzer HA. Antithrombin III in shock and disseminated intravascular coagulation. *Clin Appl Thromb Hemostas* 1995; 1:62-5.
  159. Taylor FB, Hoogendoorn H, Chang ACK, et al. Anticoagulant and fibrinolytic activities are promoted not retarded *in vivo* following thrombin generation in the presence of a monoclonal antibody that inhibits activation of protein C. *Blood* 1992; 79:1720-8.
  160. Esmon CT, Taylor FB, Snow TR. Inflammation and coagulation: linked processes potentially regulated through a common pathway mediated by protein C. *Thromb Haemostas* 1991; 66:160-4.
  161. Okajima K, Imamura H, Koga S, et al. Treatment of patients with disseminated intravascular coagulation by protein C. *Am J Hematol* 1990; 33:277-8.
  162. Gerson WT, Dickerman JD, Bowill EG, Golden E. Severe acquired protein C deficiency in purpura fulminans associated with disseminated intravascular coagulation: treatment with protein C concentrate. *Pediatrics* 1993; 91:418-22.
  163. Charytan C, Purtilio D. Glomerular capillary thrombosis and acute renal failure after epsilon-aminocaproic acid therapy. *N Engl J Med* 1969; 280:1102-4.
  164. Ratnoff OD. Epsilon aminocaproic acid - a dangerous weapon. *N Engl J Med* 1969; 280:1124-5.
  165. Schwartz B, Williams E, Conlan M, Mosher D. Epsilon-aminocaproic acid in the treatment of patients with acute promyelocytic leukemia and acquired alpha-2-plasmin inhibitor deficiency. *Ann Intern Med* 1986; 105:873-7.
  166. Awisati G, ten Cate JW, Buller HR, Mandelli F. Tranexamic acid for control of hemorrhage in acute promyelocytic leukemia. *Lancet* 1989; 2:122-4.
  167. Keane T, Gorman A, O'Connell L, Fennelly J. Epsilon-aminocaproic acid in the management of acute promyelocytic leukemia. *Acta Haematol* 1976; 56: 202-4.
  168. Warrel R, Kempin S. Treatment of severe coagulopathy in the Kasabach-Merrit syndrome with aminocaproic acid and cryoprecipitate. *N Engl J Med* 1985; 313:309-12.
  169. Poon M-C, Kloiber R, Birdsell DC. Epsilon-aminocaproic acid in the reversal of consumptive coagulopathy with platelet sequestration in a vascular malformation of Klipel-Trenaunay syndrome. *Am J Med* 1989; 87:211-3.
  170. Ortel T, Onorato J, Bedrosian C, Kaufman R. Antifibrinolytic therapy in the management of the Kasabach-Merrit syndrome. *Am J Hematol* 1988; 29:44-8.
  171. Umeki S, Adachi M, Watanabe M, Yaji S, Soejima R. Gabexate as a therapy for disseminated intravascular coagulation. *Arch Intern Med* 1988; 148:1409-12.
  172. Neuhaus P, Bechstein W, Lefebvre B, Blumhardt G, Slama K. Effect of aprotinin on intraoperative bleeding and fibrinolysis in liver transplantation. *Lancet* 1989; 2:924-5.
  173. Paloma MJ, Páramo JA, Rocha E. Effects of DDAVP on endotoxin-induced intravascular coagulation in rabbits. *Thromb Haemostas* 1992; 68:306-9.
  174. Paloma MJ, Páramo JA, Rocha E. Endotoxin-induced intravascular coagulation in rabbits: effect of tissue plasminogen activator vs. urokinase on PAI generation, fibrin deposits, and mortality. *Thromb Haemostas* 1995; 74:1578-82.
  175. Colman R, Flores D, de la Cadena R, et al. Recombinant  $\alpha$ 1-antitrypsin Pittsburgh attenuates experimental Gram-negative septicemia. *Am J Pathol* 1988; 130: 418-26.
  176. Ziegler EJ, McCutchan JA, Fierer J, et al. Treatment of gram-negative bacteremia and shock with human antiserum to a mutant *Escherichia coli*. *N Engl J Med* 1982; 307:1225-30.
  177. Calandra T, Glauser MP, Schellekens J, Verhoef J. Treatment of gram-negative septic shock with human IgG antibody to *Escherichia coli* J5: a prospective, double-blind, randomized trial. *J Infect Dis* 1988; 158:312-9.
  178. Baumgartner JD, Glauser MP, McCutchan JA, et al. Prevention of gram-negative shock and death in surgical patients by antibody to endotoxin core glycolipid. *Lancet* 1985; 2:59-63.

179. The Intravenous Immunoglobulin Collaborative Study Group. Prophylactic intravenous administration of standard globulin as compared with core-lipoplysaccharide immune globulin in patients at high risk of postsurgical infection. *N Engl J Med* 1992; 327:234-40.
180. Greenman RL, Schein RM, Martin MA, et al. A controlled clinical trial of E5 murine monoclonal IgM antibody to endotoxin in the treatment of gram-negative sepsis. The XOMA Sepsis Study Group. *JAMA* 1991; 266:1097-102.
181. Ziegler EJ, Fisher CJ Jr, Sprung CL, et al. Treatment of gram-negative bacteremia and septic shock with HA-1A human monoclonal antibody against endotoxin. A randomized, double-blind, placebo-controlled trial. The HA-1A Sepsis Study Group. *N Engl J Med* 1991; 324:429-36.
182. Quezado ZM, Natanson C, Alling DW, et al. A controlled trial of HA-1<sup>a</sup> in a canine model of gram-negative septic shock. *JAMA* 1993; 269:2221-7.
183. Luce JM. Introduction of new technology into critical care practice: a history of HA-1A human monoclonal antibody against endotoxin. *Crit Care Med* 1993; 21:1233-41.
184. Fisher CJ Jr, Opal SM, Dhainaut JF, et al. Influence of anti-tumor necrosis factor monoclonal antibody on cytokine levels in patients with sepsis. *Crit Care Med* 1993; 21:318-27.
185. Fischer E, Marano MA, Van Zee KJ, et al. Interleukin-1 receptor blockade improves survival and hemodynamic performance in *Escherichia coli* septic shock, but fails to alter host responses to sublethal endotoxemia. *J Clin Invest* 1992; 89:1551-7.
186. Fischer CJ Jr, Slotner CJ, Opal SM, et al. Initial evaluation of human recombinant interleukin-1 receptor antagonist in the treatment of sepsis syndrome: a randomized, open-label, placebo-controlled multicenter trial. *Crit Care Med* 1994; 22:12-21.
187. Knauss WA, Harrell FE, Fisher CJ Jr, et al. The clinical evaluation of new drugs for sepsis: a prospective study design based on survival analysis. *JAMA* 1993; 270:1233-41.
188. Fisher CJ, Agosti JM, Opal SM, et al. Treatment of septic shock with the tumor necrosis factor receptor:Fc fusion protein. *N Engl J Med* 1996; 334:1697-702.
189. van der Poll T, Levi M, Hack CE, et al. Elimination of interleukin 6 attenuates coagulation activation in experimental endotoxemia in chimpanzees. *J Exp Med* 1994; 179:1253-9.
190. Abraham E, Wunderink R, Silverman H, et al. Efficacy and safety of monoclonal antibody to human tumor necrosis factor- $\alpha$  in patients with sepsis syndrome. A randomized, controlled, double-blind, multicenter clinical trial. *JAMA* 1995; 273:934-41.
191. Fisher CJ, Dhainaut JFA, Opal SM, et al. Recombinant human interleukin 1 receptor antagonist in the treatment of patients with sepsis syndrome. Results from a randomized, double-blind, placebo-controlled trial. *JAMA* 1994; 271:1836-43.
192. Levi M, ten Cate H, Bauer K, et al. Inhibition of endotoxin-induced activation of coagulation and fibrinolysis by pentoxifylline or by a monoclonal anti-tissue factor antibody in chimpanzees. *J Clin Invest* 1994; 93:114-20.
193. Biemond BJ, Levi M, ten Cate H, et al. Complete inhibition of endotoxin induced coagulation activation in chimpanzees with a monoclonal Fab fragment against Factor VII/VIIa. *Thromb Haemostas* 1995; 73:223-30.
194. Creasey AA, Chang ACK, Feigen L, Wun TC, Taylor FB, Hinshaw LB. Tissue factor pathway inhibitor reduces mortality from *Escherichia coli* septic shock. *J Clin Invest* 1993; 91:2850-60.