

7. Östlund L, Biberfeld P, Robèrt K-H, Christensson B, Einhorn S. Induction of proliferation and blast transformation by Interferon in human malignant and non-malignant lymph node B cells. *Blood* 1989; 73:2171-81.
8. Robèrt K-H, Einhorn S, Östlund L, Juliusson G, Biberfeld P. Interferon induces proliferation in leukemic and normal B-cell subsets. *Hematol Oncol* 1986; 4:113-20.
9. Bladé J, López Guillermo A, Tassies D, Montserrat E, Rozman C. Development of aggressive plasma cell leukemia under interferon- α therapy. *Br J Haematol* 1991; 79:523-5.

***bcr-abl* rearrangement in adult T-lineage acute lymphoblastic leukemia**

FRANCESCO FABBIANO, ALESSANDRA SANTORO, ROSARIA FELICE, PATRIZIA CATANIA, SONIA CANNELLA, IGNAZIO MAJOLINO

Divisione di Ematologia e Unità Trapianti di Midollo Osseo, Azienda Ospedaliera "V. Cervello", Palermo, Italy

The *bcr-abl* rearrangement in T-lineage ALL has been rarely described. In the last three years we studied all new patients with ALL at diagnosis by cytogenetic and molecular analysis. Three out of eleven T-lineage ALL patients presented the rearrangement and only one was Philadelphia positive.

The Philadelphia (Ph) chromosome, t(9;22)(q34;q11), is present in more than 95% of patients with chronic myelogenous leukemia (CML) and in 15-25% of adults with acute B-lineage lymphoblastic leukemia (ALL).^{1,2} In T-lineage ALL it has rarely been reported^{3,4} and singular cases of T-lineage adult ALL carrying the *bcr-abl* rearrangement have been recently described.⁵⁻⁸ *bcr-abl* rearrangement in T lineage ALL is thus a rare event and the clinical relevance of this translocation is currently unknown.

In the last three years we studied 25 new consecutive cases of ALL (14 B-lineage and 11 T-lineage). We present here the clinical, immunologic, cytogenetic and molecular features of three out of the eleven T-lineage ALL patients presenting *bcr-abl* rearrangement at diagnosis.

Patient #1. A 15-year-old male was referred with a recent history of cough and fatigue. He was treated with daunomicin, vincristine, asparaginase, and prednisone and obtained a complete remission. He relapsed 7 months later, did not obtain a second remission and died 4 months later.

Patient #2. A 32-year-old male was admitted with acute leukemia. He was treated with idarubicin, cytarabine, vincristine and prednisone and obtained complete remission. He was later submitted to allogeneic peripheral blood transplantation from his HLA-identical sister while in first CR. The patient developed acute but not chronic GVHD. He relapsed 18 months later. He is actually in second CR after reinduction treatment.

Table 1. Clinical and biological characteristics of the patients.

Patients	#1	#2	#3
Age/Sex	15/M	32/M	47/M
Hb g/dL	13.7	6.9	12.9
WBC x 10 ⁹ /L	59.4	19.6	9.6
Plt x 10 ⁹ /L	329.	39.	436.
LDH U/L	1575	2290	711
Splenomegaly	-	+	-
Mediastinal enlargement	++	-	+++
Lymph-node enlargement	+	+	-
Phenotype	TdT,CD34,cCD3,CD4,CD5,CD7,CD13	TdT,cCD3,CD1,CD2,CD4,CD5,CD7,CD8	TdT,CD1,CD2,CD4,CD5,CD7,CD8
Karyotype	46,XY,t(9;22)(q34;q11)	46,XY	46,XY,6q-,7-,9-,+2mar
BCR type	M	M	M
Response to induction	CR	CR	CR
Survival (months)	11	24+	5

Patient #3. A 47 year-old male was admitted with acute pericarditis. The chest X-ray and chest CT scan showed massive mediastinal enlargement and pleural and pericardial effusion. Blood counts were normal, but differential counts showed 20% blast cells. Bone marrow aspiration revealed 50% blast cells with cerebroid nucleus. Pleural fluid contained 117.0x10⁹/L blast cells. The patient was treated with daunoblastin, vincristine, asparaginase and prednisone and obtained complete remission. He was submitted to autologous peripheral stem cell transplantation, but died of adult respiratory distress syndrome two weeks later.

Clinical and biological data are shown in Table 1. *bcr-abl* transcript was detected by RT-PCR and the rearrangements occur in all patients within the 5.8-kb M-*bcr* region associated with P210 *bcr-abl* expression; monoclonal rearrangement of the TCR γ gene, but not of the IGH locus was also detected by PCR (Figure 1).

Ph+ CML is known to arise in a multipotent hematopoietic stem cell.⁹ This is also shown by the fact that Ph translocation and/or *bcr-abl* expression can be simultaneously found in cells of myeloid and lymphoid lineage. Occasional reports of Ph+ T-cell blast crisis of CML provide evidence that T-cell precursors can be involved in Ph+ leukemic transformation.¹⁰ Single cases of T-lineage ALL with Ph translocation or *bcr-abl* rearrangement have also been reported.³⁻⁸

The characteristics of our three *bcr-abl* T-ALL cases are indistinguishable from other T-lineage ALL. Two presented with mediastinal enlargement and one patient had intermediate characteristics between T-ALL and T mediastinal lymphoblastic lymphoma.

We do not know whether the presence of *bcr-abl* gene rearrangement makes the prognosis of T-lineage ALL worse, but two out of three patients had bad prognosis characteristics such as early T phenotype,

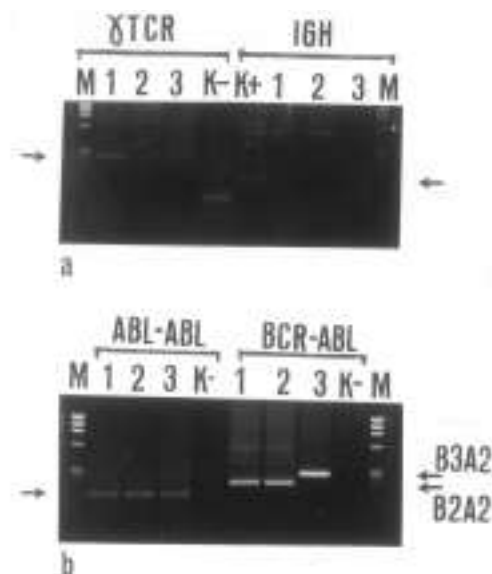


Figure 1. Molecular characteristics of our cases. A) PCR amplification of γ TCR and IGH locus. B) RT-PCR detection of BCR-ABL mRNA. Lane numbers refer to patients listed in table 1. Arrows indicate the products of amplification. M = size markers, K- = negative control, K+ = positive control. The samples were electrophoresed through agarose and DNA visualized by staining in ethidium bromide.

high WBC count and extranodal involvement. The presence of *bcr-abl* rearrangement in T-ALL is a rare event. Our cases are probably an occasional series. Nevertheless the real incidence and the significance of *bcr-abl* rearrangement in T-lineage ALL is not known. We think that further studies on the molecular biology of T-ALL could be useful.

Funding

This work is in part supported by a grant from the Associazione Italiana per la Ricerca sul Cancro (AIRC) and by a grant from the Associazione Italiana contro le Leucemie (AIL).

Correspondence

Francesco Fabbiano, MD, Divisione di Ematologia, Azienda Ospedaliera "V. Cervello", via Trabucco 180, 90146 Palermo, Italy. Phone: international +39-091-6802962 • Fax: international +39-091-6883145 • E-mail: francesco.fabbiano@schering-pl.it

References

1. Bloomfield CD, Goldman AI, Alimena G, et al. Chromosomal abnormalities identify high-risk and low-risk patients with acute lymphoblastic leukemia. *Blood* 1986; 67:415-20.
2. Secker-Walker LM, Craig JM, Hawkins JM, Hoffbrand AV. Philadelphia positive acute lymphoblastic leukemia in adults, BCR breakpoint and prognostic significance. *Leukemia* 1991; 5:196-9.

3. Dankbaar H, Willemze R, Spaander PJ, Geraedts JP. Philadelphia chromosome positive T-ALL. *Br J Haematol* 1982; 50:543.
4. Louwagie A, Criel A, Verfaillie CM, et al. Philadelphia positive T-acute lymphoblastic leukemia. *Cancer Genet Cytogenet* 1985; 16:297-300.
5. Radich JP, Kopecky KJ, Boldt DH, et al. Detection of *bcr-abl* fusion genes in adult acute lymphoblastic leukemia by the polymerase chain reaction. *Leukemia* 1994; 8:1688-95.
6. Miller BA, Reid MM, Nell M., et al. T-cell acute lymphoblastic leukaemia with late developing Philadelphia chromosome. *Br J Haematol* 1984; 56:139-46.
7. Coad JE, Arthur DC, Gajl-Peczalska HJ, Litz CE. Developing Philadelphia chromosome positive in a case of T-cell acute lymphoblastic leukemia. *Leukemia* 1994; 8:889-94.
8. Fizzotti M, Chen EY, Link MP, et al. Simultaneous expression of RBTN-2 and *bcr-abl* oncogenes in a T-ALL with t(11;14)(p13;q11) and a late-appearing Philadelphia chromosome. *Leukemia* 1994; 8:1124-30.
9. Fialkow PJ, Jacobson RJ, Panayannopolou T. Chronic myelocytic leukemia. Clonal origin in a stem cell common to the granulocyte, erythrocyte, platelet and monocyte/macrophage. *Am J Med* 1977; 63:125-30.
10. Griffin JD, Tantravahi R, Canellos GP, et al. T cell surface antigens in a patient with blast crisis of chronic myeloid leukemia. *Blood* 1983; 61:640-4.

AIDS-related non-Hodgkin's lymphomas from an Italian area

ROBERTO FERRETTO, ROBERTO LUZZATI, DINO VENERI*, PIERANGELO ROVERE°, MAURIZIO SOLBIATI, ERCOLE CONCIA

*Institute of Immunology and Infectious Diseases; *Department of Hematology, University of Verona, Italy; °Section of Infectious Diseases, Hospital of Legnago (Verona), Italy*

In a retrospective study, 42 (7.7%) of 545 patients with AIDS from a single area of Italy had non-Hodgkin's lymphoma (28 systemic and 14 primary central nervous system lymphomas). The improved outcome and survival of treated patients outlines the clinical benefit of antineoplastic treatment in selected cases.

It has been widely recognized that patients with HIV-related immunosuppression are at increased risk of developing non-Hodgkin's lymphomas (NHL) that include systemic, primary central nervous system (P-CNS-L) and body cavity-based lymphomas.¹ At present in Italy the incidence of NHL is 3.5% according to the Centro Operativo AIDS.² However, this figure represents only the first AIDS-defining condition, potentially missing lymphomas occurring at a later stage.

We have retrospectively evaluated the epidemiological and clinical characteristics of 42 cases (7.7%) of NHL among 545 patients with AIDS admitted to the Infectious Diseases Departments of the Verona area up to June 1997. Baseline characteristics of patients are shown in Table 1. Systemic-NHL were of B-cell type and classified as follows: 18 large cell, 4