



## Prevalence of phenotypic activated protein C resistance (APCR) in venous thromboembolic patients

CRISTINA MARZO, CARMEN ARAGUÁS, JAVIER GÓMEZ-ARBONÉS, SONIA RAMÍREZ

Department of Hematology, Arnau de Vilanova University Hospital, University of Lleida, Lleida, Spain

Until the discovery of activated protein C resistance (APCR),<sup>1</sup> less than 10% of patients with venous thromboembolism (VT) showed defects in proteins involved in the inhibition of coagulation. APCR is caused by a single point mutation in the factor V gene,<sup>2</sup> and it is accepted that APCR is associated with an increased risk for VT.<sup>3,4</sup> In this work, we studied the prevalence of APCR in venous thromboembolic patients and found it to be 10.5% compared with 4.5% in controls (p=0.105).

We prospectively studied 172 consecutive patients with VT (Table 1). Thrombophilia assay was performed one month after the end of oral anticoagulant therapy. We studied: platelet number, prothrombin, activated-partial-thromboplastin and thrombin time, fibrinogen, antithrombin III, plasminogen, functional C and S proteins, lupus anticoagulant, anticardiolipin antibodies and APCR-test

**Table 1. Association between APC resistance and risk factors for thrombosis at the moment of the thrombotic episode**

risk factors for thrombosis		patients				p=*
		poor APC response (n=18)		normal APC response (n=154)		
		num	(%)	num	(%)	
age	< 40	3	(16.7)	21	(13.6)	0.702
	> 40	15	(83.3)	133	(86.4)	
immobility	no	13	(72.3)	121	(78.6)	0.539
	yes	5	(27.7)	33	(21.4)	
previous surgery	no	18	(100)	129	(83.8)	0.051
	yes	0	(0)	25	(16.2)	
thrombotic antecedents	no	18	(100)	151	(98.1)	0.716
	yes	0	(0)	3	(1.9)	
coronary disease	no	18	(100)	145	(94.2)	0.361
	yes	0	(0)	9	(5.8)	
thrombophilia	no	18	(100)	139	(90.3)	0.177
	yes	0	(0)	15	(9.7)	
malignant disease	no	18	(100)	136	(88.3)	0.120
	yes	0	(0)	18	(11.7)	
pregnancy and puerperium	no	16	(88.9)	136	(88.7)	0.059
	yes	2	(11.1)	18	(1.3)	
oral contraceptives	no	18	(100)	153	(99.4)	0.895
	yes	0	(0)	1	(0.6)	
obesity	no	18	(100)	140	(90.9)	0.199
	yes	0	(0)	14	(9.1)	
varicose veins	no	15	(83.4)	134	(87.0)	0.640
	yes	3	(16.6)	20	(13.0)	
myeloproliferative syndrome	no	18	(100)	150	(97.4)	0.640
	yes	0	(0)	4	(2.6)	
nephrotic syndrome	no	18	(100)	152	(98.7)	0.801
	yes	0	(0)	2	(1.3)	

\*Fisher's exact test.

**Table 2. Association between APC resistance and age, sex, venous thromboembolism-type, deficiencies of protein C or S, and recurrent venous thromboembolism.**

		APC resistance test results		p=^
		poor APC response (n=18) mean±SD	normal APC response (n=154) mean±SD	
age		59±14	61±15	0.377
sex	male	6 (33.3)	85 (55.2)	0.087
	female	12 (66.7)	69 (44.8)	
venous thromboembolism-type	DVT	7 (43.7)	85 (57.4)	0.311
	PE	9 (56.3)	63 (42.6)	
	others*	2	6	
protein C deficiency	no	18 (100)	147 (95.5)	0.540
	yes	0 (0)	7 (4.5)	
protein S deficiency	no	18 (100)	148 (96.1)	0.490
	yes	0 (0)	6 (3.9)	
recurrent venous thromboembolism	no	13 (72.2)	134 (87.0)	0.124
	yes	5 (27.8)	20 (13.0)	

\*group not included in the statistic analysis because of the reduced number of cases; \*\* Mann-Whitney test; \*\*\* Fischer exact test.

(APCR Coatest, Chromogenix, Sweden). APCR-test values lower than 2.05 were considered positives. We drew new blood samples from all positive APCR patients to confirm the presence of APCR. We studied the APCR prevalence on healthy people in a control group of 88 subjects. Fifty-three percent of the patients with VT were male (mean age: 60) and 47% female (mean age: 62); 14.5% manifested recurrent VT and 80% showed risk factors for VT. Only 4.1% and 3.5% of patients showed protein C or S deficiency in the thrombophilia study. One patient presented lupus anticoagulant and anticardiolipin antibodies. APCR-test was positive for 13.9% of the patients. Five of them failed to be confirmed on the second extraction and one incorrect positive APCR test was discarded due to the presence of lupus anticoagulant. Thus, 10.5% of the patients were considered positive. 4.5% of the healthy controls presented APCR.

As shown in Table 2, no significant association was found between a positive APCR-test and age, sex, VT-type or appearance of recurrent episodes of VT. None of the patients with positive APCR-test manifested other protein deficiencies involved in the inhibition of coagulation. No association between positive APCR and risk factors for VT was found. We therefore think that positivity for the APCR test is not influenced by risk factors for VT.

In our study, prevalence of APCR in venous thromboembolic patients is 10.5%, whereas in the controls it is 4.5% (p=0.105). As reported by Legnani,<sup>5</sup> our patients manifested a decrease in the APCR frequency when a second sample was drawn. This prevalence of positive APCR tests is lower than that reported by other groups.<sup>6-8</sup> An adequate selection of patients, confirmation of positive APCR tests and

consideration of those factors that may interfere with the results should be of the utmost importance when studying APCR prevalence in venous thromboembolic patients and its association with other variables.

Also, we screened 15 families of positive APCR patients; 26.6% of the relatives revealed positive APCR-test and none of them presented VT. All the affected family members were first degree relatives to the propositus. As reported by Svensson<sup>9</sup> our results suggest the existence of an autosomal dominant mode of inheritance.

VT appears as a consequence of a series of environmental and genetic factors.<sup>10</sup> APCR is one of the factors associated to high risk of thrombosis and it is widely accepted that its frequency is higher than other genetic disorders involved in VT.

### Key words

Venous thromboembolism, PCR

### Correspondence

Carmen Araguás Arasanz, MD, Department of Haematology, Arnau de Vilanova University Hospital, Rovira Roure 80, 25198 Lleida, Spain. Phone: international +34-73-248100 ext. 359 • Fax: international +34-73-248754 • e-mail: xga@medicina.udl.es

### References

1. Dahlbäck B, Carlsson M, Svensson P. Familial thrombophilia due to a previously unrecognized mechanism characterized by poor anticoagulant response to activated protein C. *Proc Natl Acad Sci USA* 1993; 90: 1004-8.
2. Bertina RM, Koелеmen BPC, Koster T, et al. Mutation in blood coagulation factor V associated with resistance to activated protein C. *Nature* 1994; 369:64-7.
3. Dahlbäck B. Factor V and protein S as cofactors to activated protein C. *Haematologica* 1997; 82:91-5.
4. Dahlbäck B. Inherited thrombophilia: resistance to activated protein C as a pathogenic factor of venous thromboembolism. *Blood* 1995; 3:607-14.
5. Legnani C, Palareti G, Biagi R, Coccheri S. Activated protein C resistance in deep-vein thrombosis [letter]. *Lancet* 1994; 343:541-2.
6. Griffin JH, Evatt B, Wideman C, Fernández JA. Anticoagulant protein C pathway defective in majority of thrombophilic patients. *Blood* 1993; 82:1989-93.
7. Koster T, Rosendaal FR, de Ronde H, Briët E, Vanderbroucke JP, Bertina RM. Venous thrombosis due to poor anticoagulant response to activated proteic C: Leiden thrombophilic study. *Lancet* 1993; 342: 1503-6.
8. Dahlbäck B. Inherited resistance to activated protein C, a major cause of venous thrombosis is due to a mutation in the factor V gene. *Haemostasis* 1994; 24:139-51.
9. Svensson PJ, Dahlbäck B. Resistance to activated protein C as a basis for venous thrombosis. *N Engl J Med* 1994; 330:517-22.
10. D'Angelo A, Mazzola G, Crippa L, Fermo I, Viganò D'Angelo S. Hyperhomocysteinemia and venous thromboembolic disease. *Haematologica* 1997; 82: 211-9.

## Incidence and clinical manifestations of activated protein C resistance and factor V Leiden in young patients with venous thromboembolic disease in Spain

TERESA OLAVE, ROSA CORNUDELLA, CARLOS HOMS,\*  
GEMMA AZACETA, ISABEL TIRADO,° MARTIN GUTIERREZ

Hematology Department, Hospital Clínico Universitario, Zaragoza; \*Intensive Care Unit, Hospital San Jorge, Huesca; °Hemostasis and Thrombosis Unit, Hematology Department, Hospital de la Santa Creu i Sant Pau, Barcelona, Spain

**In order to evaluate the actual incidence and clinical repercussion of activated protein C resistance (APCR) in our area, we performed a coagulation and thrombophilic study on 65 young patients diagnosed with deep vein thrombosis and 53 controls. Family and genetic study was carried out in APC-resistant patients. We found APCR in 26.15% of patients and the 77.7% of these and their relatives were heterozygous for factor V Leiden. There's a clear relationship between phenotype APCR and thrombosis, and also between factor V Leiden and thrombosis.**

In 1993 Dahlbäck<sup>1</sup> described a new cause of inherited thrombophilia. The activated protein C resistance (APCR) was identified as the main risk factor of venous thromboembolic disease (VTED) because it was found in 20-60% of the patients with venous thrombosis and in 2-10% of normal population.<sup>2,3</sup> The molecular background for the APCR is a single point mutation in the factor V gene, which predicts substitution of an arginine at position 506 by a glutamine.<sup>4</sup> Mutated factor V (also called factor V Leiden) is activated by thrombin or factor Xa in the normal way, but impaired inactivation of mutated factor Va by activated protein C results in a life-long, hypercoagulability.<sup>2</sup> Nevertheless, the role of factor V as a cofactor of activated protein C is still far from clear.<sup>5</sup>

The incidence and clinical manifestations of APCR are very heterogeneous,<sup>6,9</sup> and the clotting assays used as screening tests are subjected to large variability.<sup>9,10</sup> For this reason, we wanted to evaluate the actual incidence and clinical repercussion of APCR in our area in order to establish our own normal range and to determine in which cases it's necessary to complete the study with the analysis of factor V Leiden.

We studied 65 young patients, 27 females and 38 males, aged between 18 and 50 years old, diagnosed of VTED in the Zaragoza University Hospital, Spain between January, 1993 and December, 1995. Patients taking oral anticoagulants were excluded from this study and all the plasma samples were taken at least one month after suppressing coumarins. The control group was comprised of 53 healthy subjects, with a sex and age distribution similar to the patients' group.

The coagulation and thrombophilia study in patients and controls was performed as follows:

functional antithrombin III by chromogenic assay (AT III, Isaza), antigenic protein C by ELISA (Asserachrom P.C., Boheringer Mannheim), functional protein C by clotting assay (Proclot, Isaza), functional protein C by chromogenic assay (Stachrom, Boheringer Mannheim), antigenic free and total protein S by ELISA (Stachrom, Boheringer Mannheim), plasminogen by chromogenic assay (Plasminogen, Boheringer Mannheim), Exner test or clotting test with kaolin (lupus anticoagulant assay) results were expressed as *APC-ratio*.

Table 1. Thrombosis risk for strata of *APC-ratios*.

<i>APC-ratio</i>	Odds ratio	95% confidence interval
< 2.1	13.00	1.64-103.02
< 2.2	7.65	1.66-35.19
< 2.4	2.51	0.96-6.59
< 2.6	1.82	0.78-4.23
< 3.0	1.44	0.69-3.00

Family and genetic study was carried out in *APC*-resistant patients. The genomic fragment containing 1691 G/A was amplified by PCR using the primers described by Bertina<sup>4</sup> (primer 5'- TGCCCAGTGCT-TAACAAAGACCA-3', primer Y: 5'-TGTTATCACACTG-GTGCTAA-3'). The 267-bp fragment was digested with 2 U of the restriction enzyme Mnl I (Biolabs) to establish whether the allele was normal or mutated.

According to the anticoagulant response to *APC* in controls and patients, we defined three categories: normal (*APC-ratio* >2.4), borderline (2.04-2.4) and resistant (< 2.04) subjects.

Some inherited known causes of thrombophilia in 40% of patients was detected. The most frequent was *APCR* (26.15%, with 12.3% resistants and 13.8% borderlines), followed by *PC* (7.69%) and *PS* (4.61%) deficiency and, finally, *ATIII* deficiency (1.53%). Although *APCR* is the most prevalent risk factor for venous thrombosis, the clinical manifestations are less severe than antithrombin III and protein C deficiency.

The relative risk of venous thrombosis for *APC-ratio*, estimated by the odds ratio, is very variable, as summarized in Table 1, where confidence intervals of 95% are shown. When the *APC* ratio is lower than 2.1, the risk of thrombosis is increased 13-fold; lower than 2.2 it's increased almost 8-fold, and when ratio is lower than 2.4, the risk doubles. This means that there's a clear relationship between phenotype and thrombosis, because the lower the anticoagulant response to *APC*, the higher thrombotic risk is.

The 77.7% of resistant and 40% of borderline patients and relatives are heterozygous for factor V Leiden. So, we think it's justified to perform a genetic study of the patients with *APC* ratios in the lower

limits of normal. The risk of deep vein thrombosis, calculated with the odds ratio (10.8) and its confidence interval of 95% (1.64-70.9) in the contingency table (thrombosis/G1691A mutation), is increased 10-fold in those heterozygous for factor V Leiden. That is, there's a relationship between genotype and thrombosis, although additional genetic factors may play a role.<sup>12</sup>

### Acknowledgments

The authors wish to thank José Antonio Cristóbal, Professor of statistics at Zaragoza University, for his help with the statistical evaluation.

### Key words

*APC* resistance, thrombophilia, factor V Leiden.

### Correspondence

Dra. Maria Teresa Olave, Servicio de Hematología, Hospital Clínico Universitario, San Juan Bosco 15, 50009 Zaragoza, Spain Phone: international +34-76-556400 • Fax: international + 34-76-565995.

### References

- Dahlbäck B, Carlsson M, Svensson PJ. Familial thrombophilia due to a previously unrecognized mechanism characterized by poor anticoagulant response to activated protein C prediction of a cofactor to activated protein C. *Proc Natl Acad Sci USA* 1993; 90:1004-8.
- Hillarp A, Dahlbäck B, Zöller B. Activated protein C resistance, from Phenotype to genotype and clinical practice. *Blood Rev* 1995; 9:201-12.
- Svensson PJ, Dahlbäck B. Resistance to activated protein C as a basis for venous thrombosis. *N Engl J Med* 1994; 330:517-22.
- Bertina RM, Koeleman BPC, Koster T, et al. Mutation in blood coagulation factor V associated with resistance to activated protein C. *Nature* 1994; 369:64-7.
- Dahlbäck B. Factor V and protein S as cofactors to activated protein C. *Haematologica* 1997; 82:91-5.
- Koster T, Rosendaal FR, de Ronde H, Briët E, Vandenbroucke JP, Bertina RM. Venous thrombosis due to poor anticoagulant response to activated protein C: Leiden Thrombophilia Study. *Lancet* 1993; 342:512-22.
- Griffin JH, Evatt B, Wideman C, Fernandez JA. Anticoagulant protein C pathway defective in majority of thrombophilic patients. *Blood* 1993; 81:1989-93.
- Rosendaal FR, Koster T, Vandenbroucke JP, Reitsma PH. High risk of thrombosis in patients homozygous for factor V Leiden (activated protein C resistance). *Blood* 1995; 85:1504-8.
- Greengard JS, Eichinger S, Griffin JH, Bauer KA. Brief report - variability of thrombosis among homozygous siblings with resistance to activated protein C due to an Arg->Gln mutation in the gene for factor V. *N Engl J Med* 1994; 33 1:1559-62.
- de Ronde H, Bertina RM. Laboratory diagnosis of *APC*-resistance: a critical evaluation of the test and the development of diagnostic criteria. *Thromb Haemost* 1994; 72:880-6.

11. Freyburger G, Bilhou-Nabera C, Dief S, et al. Technical and biological conditions influencing the functional APC resistance test. *Thromb Haemost* 1996; 75:460-5.
12. D'Angelo A, Mazzola G, Crippa L, Fermo I, Viganò D'Angelo S. Hyperhomocystenemia and venous thromboembolic disease. *Haematologica* 1997; 82: 211-9.

### Atypical microangiopathy in a patient treated with ticlopidine

PEDRO M. ALBA, JOSÉ M. BÁEZ,\* ANTONIO PAZ,  
MERCEDES MONGE, CÉSAR MENDOZA

*Departments of Hematology and \*Pathology, University Hospital of Puerto Real, Cádiz, Spain*

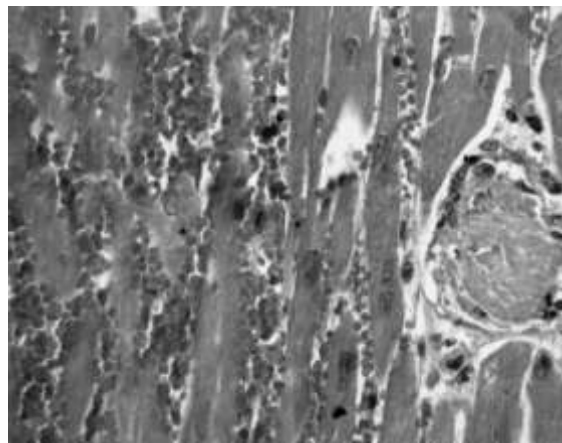
**Microangiopathies are rare complications during treatments with ticlopidine. We describe an atypical microangiopathy, affecting almost exclusively myocardium, and thrombocytopenia, shortly after onset of ticlopidine. The patient died a few days after. Autopsy showed no bleedings or large thrombi in most organs, but were compatible with microangiopathy in myocardial small vessels.**

Ticlopidine is an inhibitor of platelet aggregation frequently being used in stroke prevention and other thromboembolic events. Its probable association with the appearance of microangiopathies, especially thrombotic thrombocytopenic purpura (TTP) has been described by several authors.<sup>1-5</sup> We present the case of a patient that developed atypical characteristics and deadly evolution microangiopathy in the course of treatment with ticlopidine.

The patient was a male of 46 years, without personal antecedent of interest. Three weeks before admission, he was diagnosed with left eye acute anterior ischemic neuropathy, beginning treatment with ticlopidine at usual doses (250 mg a day). At this time, blood cell count, coagulation tests and routine study of hypercoagulability were normal.

Seven days after beginning treatment, the patient presented skin rash, with pruritus and febricula, being treated with antihistaminic drugs, which improved the symptoms. In the following days, and in a progressive way, the patient complained of general discomfort, nausea and vomiting. Analytical study showed intensive thrombocytopenia ( $6 \times 10^9$  platelets/L) and moderate anemia, so he was referred to our Hospital.

On admission, the patient appeared ill, showing dry mucosae and injuries from scratching. No petechial purpura, evident hemorrhages or neurological abnormalities were found. Spleen and liver were not palpable. No thoracic abnormal murmurs were detected. Laboratory tests confirmed the existence of intensive thrombopenia and anemia (hemoglobin of 8.8 g/dL); leukocytes and formula were normal; schistocytes were not found in blood smears. Biochemical study showed



**Figure 1. Thrombi and hemorrhages in myocardium.**

high levels of lactodehydrogenase (LDH) (3.873 U/L) and creatinine (2 mg/dL). Bilirubin, transaminases, proteinogram, ions, glycemia and coagulation tests were normal. D-Dimers were in low levels (0,5-1 mg/L). Urine was of normal aspect; urinary sediment showed microhematuria (200 erythrocytes/ $\mu$ L). Coombs test was negative. Bone marrow aspirate showed megakaryocytic hyperplasia and mild eosinophilia.

After fluid replacement and discontinuation of ticlopidine, treatment with prednisone was administered (1 mg/kg/d). On the first day after admission the general condition improved and the urine was clear. On the second day, LDH and creatinine values were slightly lower (2.454 U/L and 1.2 mg/dL). Anemia and great thrombocytopenia persisted. On the third day, the patient entered into a sudden confusion status; urgent cranial scanner was reported as absence of hemorrhage. Few hours later, he developed intense agitation, and died by cardiorespiratory arrest. Necropsy was performed. Hemorrhagic effusions were found only in myocardium. Macroscopic findings were irrelevant, except the presence of hemorrhages in a stripped pattern in myocardium. The microscopic examination showed the existence of multiple fibrinous thrombi in myocardial small vessels (Figure 1), and in a reduced number of small vessels in adrenal glands, liver, kidneys and pancreas.

The temporal relationship suggests that this microangiopathy was due to ticlopidine treatment.

#### Acknowledgments

*The authors wish to thank Dr. J. Galiana and Dr. M. Saldaña for critical reading of the manuscript.*

#### Key words

*Ticlopidine, microangiopathy, Moskowitz, purpura, thrombosis.*

### Correspondence

Pedro M. Alba García, MD, Servicio de Hematología, Hospital Universitario de Puerto Real, C.N. IV, km 665, Cádiz, Spain. Phone: international +34-56-470100 • Fax: international + 34-56-470282 • E-mail: pedromanuel.alba@uca.es

### References

1. Page Y. Thrombotic thrombocytopenic purpura related to ticlopidine. *Lancet* 1991; 337:774-6.
2. Jiménez FJ. Púrpura trombótica trombocitopénica asociada a la ticlopidina. *An Med Interna* 1996; 13:46-7.
3. Franchimont D. Moskowitz syndrome in a patient treated with ticlopidine. *Rev Med Liege* 1996; 51:214-6.
4. Kovacs MJ. Thrombotic thrombocytopenic purpura associated with ticlopidine. *Ann Pharmacother* 1993; 27:1060-1.
5. Falezza G. Thrombotic thrombocytopenic purpura developed during ticlopidine therapy. *Haematologica* 1992; 77:525.

### Pulmonary mucosa-associated lymphoid tissue lymphoma and myasthenia gravis.

#### A case report

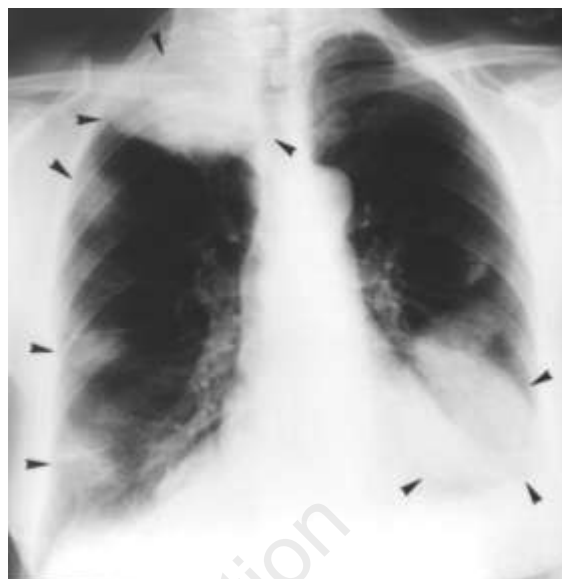GIOVANNI B. GABRIELLI, ORAZIO CODELLA, FRANCO CAPRA, GIORGIO DE SANDRE

*Istituto di Clinica Medica Generale, Università di Verona, Italy*

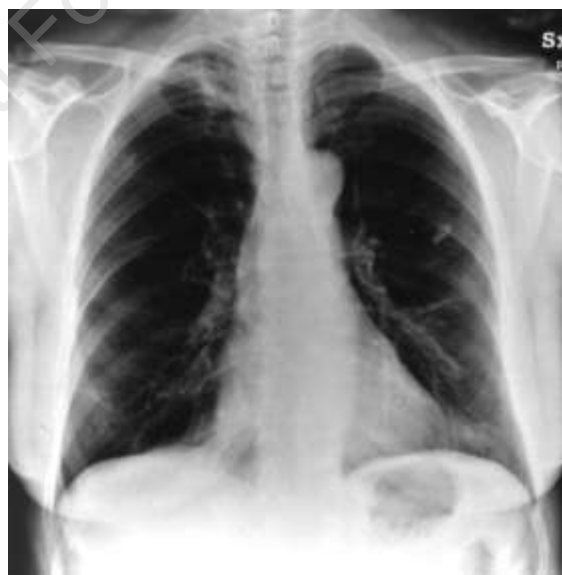**We describe a low-grade, MALT-lymphoma with multiple, unusually large opacities involving both the lungs in a woman suffering from myasthenia gravis. Unlike other autoimmune diseases, myasthenia gravis has never been associated with MALT-lymphoma thus far. After cyclophosphamide treatment, a complete detersion of the pulmonary opacities was obtained.**

Although not frequent, pulmonary mucosa-associated lymphoid tissue (MALT) lymphomas are well-recognized.<sup>1,2</sup> However, the case we describe here presents some aspects that render it noteworthy.

In June 1995, a 55-year-old woman began complaining of great-joint arthritis and erythema nodosum. Her chest radiography showed multiple, large opacities involving both the lungs (Figure 1). Myasthenia gravis had been diagnosed 20 years before and pyridostigmine was continuously taken thereafter, with good control of the neuromuscular symptoms. Laboratory analyses included elevated ESR; monoclonal M- $\gamma$ -globulin; antiacetylcholine receptor antibodies; absence of serum markers of cancer; normal values for hemochrome and other routine tests. Total CT-scan showed multiple, solid opacities with diameter up to 8 cm within both the lungs; liver, spleen and lymph nodes were normal. Fiberoptic bronchoscopy showed a pervious bronchial tree. Transbronchial biopsy was not diagnostic, whereas a surgical biopsy of the large, apical, right-sided lesion led to the diagnosis of *low-grade pulmonary MALT-lymphoma* according to well-recognized



**Figure 1. Chest radiography before the treatment. Multiple pulmonary opacities (arrows) are evident in both pulmonary fields. Very large lesions, 8 cm in diameter, are localized in the upper right lobe and in the lower left one.**



**Figure 2. Chest radiography after cyclophosphamide treatment. Complete detersion of the pulmonary opacities.**

histological, immunohistochemical and genetic findings.<sup>3,4</sup> Finally, a bone marrow biopsy showed normal hematopoiesis, without lymphoma localization.

In September 1995, the patient started oral cyclophosphamide treatment (100 mg/die), initially associated with oral prednisone. Both great-joint arthritis and erythema nodosum resolved within a few days; ESR normalized after a few weeks; and monthly monitoring by chest X-ray showed a progressive

shrinking of the pulmonary opacities, a complete radiological detersion having been achieved in September 1996 (Figure 2). At this time, just one year after starting it, cyclophosphamide was stopped. At the last control, in April 1997, the patient continued to be well, having normal routine laboratory analyses and negative chest radiography.

In the present case, both the lungs were affected by multiple neoformations, two of which were about 8 cm in diameter; to our knowledge, pulmonary masses of similar size have never been reported so far in a case of low-grade MALT-lymphoma, which is most often restricted to only one lung.<sup>5,6</sup>

It has been suggested that autoimmune diseases may play a pathogenetic role in the development of MALT-lymphoma.<sup>2,7</sup> Myasthenia gravis is also an autoimmune disease, characterized by an autoaggressive process directed against the acetylcholine receptors; however, an association between MALT-lymphomas and myasthenia gravis has never been reported so far. Whether a long-lasting myasthenia gravis may be considered an autoimmune disorder predisposing *per se* to the development of MALT-lymphoma remains an open question. However, a merely casual occurrence of two independent diseases cannot be excluded at present.

Optimal management of MALT-lymphoma is not well standardized yet. In spite of the extent of lung involvement, cyclophosphamide induced, in our patient, a progressive decrease of the pulmonary opacities, up to a complete radiological detersion one year thereafter. Clinical and radiological remission have now lasted for about seven months since the cessation of treatment.

### Key words

MALT-lymphoma, myasthenia gravis, autoimmune disorders

### Correspondence:

Prof. Giovanni B. Gabrielli, Istituto di Clinica Medica, Ospedale Policlinico, via delle Menegone, 37134 Verona, Italy. Phone: international + 39-45-509134 • Fax international +39-45-509913.

### References

1. Isaacson P, Wright DH. Malignant lymphoma of mucosa-associated lymphoid tissue; a distinctive type of B-cell lymphoma. *Cancer* 1983; 52:1410-6.
2. Nicholson AG, Wotherspoon AC, Jones AL, Sheppard MN, Isaacson PG, Corrin B. Pulmonary B-cell non-Hodgkin's lymphoma associated with autoimmune disorders: a clinicopathological review of six cases. *Eur Respir J* 1996; 9:2022-5.
3. Isaacson PG. Gastrointestinal lymphoma. *Hum Pathol* 1994; 25:1020-9.
4. Papadaki L, Wotherspoon AC, Isaacson PG. The lymphoepithelial lesion of a gastric low-grade B-cell lymphoma of mucosa-associated lymphoid tissue (MALT): an ultrastructural study. *Histopathology* 1992; 21:415-21.
5. Thieblemont C, Berger F, Coiffier B. Mucosa-associated lymphoid tissue lymphomas. *Curr Opin Oncol* 1995; 7:415-20.
6. Cordier JF, Chailleux E, Lauque D, et al. Primary pulmonary lymphomas: a clinical study of 70 cases in nonimmunocompromised patients. *Chest* 1993; 103: 201-8.
7. Hyjek E, Isaacson PG. Primary B-cell lymphoma of the thyroid and its relationship to Hashimoto's thyroiditis. *Hum Pathol* 1988; 19:1315-26.

### Mantle cell lymphoma with amyotrophic lateral sclerosis (motor neuron disease)

SONIA HERRERO,\* ALBERTO CANTALAPIEDRA,\* JAIME PÉREZ-OTEYZA,\* CARMEN BELLAS,° JOSÉ GOBERNADO,# JESÚS ODRIOZOLA\*

\*Departments of Hematology, °Pathology, #Neurology, Ramón y Cajal Hospital, Madrid, Spain

**We describe a previously unreported case of mantle cell lymphoma (MCL) associated to amyotrophic lateral sclerosis (ALS) in a 63-year-old woman with a 1-year history of weakness of arm and leg muscles. The both molecular-genetic and flow cytometry analysis of lymphocytes of peripheral blood (PB) demonstrated leukemic phase of MCL.**

A 63-year-old woman was admitted to our hospital for one-year progressive weakness in her extremities. Tendon reflexes were overactive in the legs with widespread reflexing area, bilateral Babinski and both ankle and patellar clonus. There was no sensory defect. Brain magnetic resonance imaging showed cortico-subcortical atrophy and multiple small lesions of white matter. Electromyographic studies revealed severe multisegmentary denervation with preserved peripheral nerve conduction. A lumbar puncture showed cerebrospinal fluid protein content and biochemical profile were normal, Gram's stain and cultures were negatives. PB examination showed a white cell count of  $19.5 \times 10^9/L$  with an absolute lymphocyte count of  $11 \times 10^9/L$ . Hemoglobin level and platelet count were normal. The lymphocytes were medium to large in size, with scanty to moderate cytoplasm, and indented nuclei. The chromatin was moderately coarse with nucleoli in some cells. Serum immunoglobulin (IG) were normal, without monoclonal component. The immunophenotypic features of lymphoid cells were: CD19<sup>+</sup>, CD5<sup>+</sup>, CD20<sup>+</sup>, kappa ( $\kappa$ )<sup>+</sup>, lambda ( $\lambda$ )<sup>-</sup>, CD23<sup>-</sup>, CD10<sup>-</sup> and FMC7<sup>-</sup>, with clonal expression of  $\kappa$  light chain on 64% of mononuclear cells. The bone marrow (BM) aspirate showed 37% mature-appearing lymphocytes. BM biopsy revealed reactive changes. Immunohistochemical study of BM specimen showed expression of both  $\kappa$  and  $\lambda$  chains of immunoglobulins. Cytogenetic analysis of BM showed no chromosomal abnormalities.

The body CT did not show hepatosplenomegaly, adenopathies or extranodal involvement. The endo-

scopy and gastric biopsy was normal. No viral infection was detected. The molecular study of the PB lymphocytes by polymerase chain reaction detected a monoclonal pattern.

Corticosteroid therapy was started with prednisone at 120 mg/day dose. After 2 weeks of treatment, no improvement was observed. Chlorambucil was initiated at dose of 12 mg/day, reaching normal values ( $2.58 \times 10^9/L$  lymphocytes) after 7 days of chlorambucil therapy. Flow cytometry analysis showed disappearance of the previous clonal population. Nevertheless, the patient experienced a progressive worsening of her neurological symptoms.

Our case was a MCL in leukemic phase. MCL has been proposed as a new specific clinicopathologic entity.<sup>1</sup> Leukemic manifestation of this lymphoma seems fairly uncommon, perhaps because some of these cases are misdiagnosed as chronic lymphocytic leukemia (CLL).<sup>2,3</sup> Some authors postulate that leukemic phase of MCL is indicative of aggressive disease and predicts poor prognosis, although, in some cases leukemic MCL can be an indolent condition and was classified as atypical CLL. The prognosis does not appear as ominous in those patients in whom a leukemic phase appears at diagnosis, as compared with development during the clinical course.<sup>4</sup> In our patient, leukemic phase of MCL was identified at diagnosis, but the course appeared to be indolent, since it was well controlled with therapy. The association of combined motor neuron diseases and lymphoma has been recognized<sup>5-7</sup> and a common origin has also been hypothesized.<sup>8</sup>

### Acknowledgments

The authors wish to thank Dr. E. Roldán for the cytometry analysis.

### Key words

Lymphocytic lymphoma of intermediate differentiation, mantle cell lymphoma, motor neuron disease, amyotrophic lateral disease.

### Correspondence

Sonia Herrero Martín, M.D., Dept. of Hematology, Hospital Ramón y Cajal, Carretera Colmenar Viejo, km. 9, 100, 28034 Madrid, Spain.  
Phone/Fax international +34.1.3368037.

### References

1. Harris NL, Jaffe ES, Stein H, et al. A revised European-American classification of lymphoid neoplasm: a proposal from the international lymphoma study group. *Blood* 1994; 84:1361-92.
2. Pombo de Oliveira MS, Jaffe ES, Catovsky D. Leukaemic phase of mantle zone (intermediate) lymphoma: its characterization in 11 cases. *J Clin Pathol* 42:962-72.
3. Vadlamudi G, Lionetti KA, Greenberg S, Metha K. Leukemic phase of mantle cell lymphoma two case reports and review of the literature. *Arch Pathol Lab*

*Med* 1996; 120:35-40.

4. Campo E, Jaffe E. Leukemic mantle cell lymphoma can behave in an indolent fashion-reply [letter]. *Arch Pathol Lab Med* 1996; 120:905.
5. Rowland LP, Sherman WH, Latov N, et al. Amyotrophic lateral sclerosis and lymphoma: bone marrow examination and other diagnostic test. *Neurology* 1992; 42:1101-2.
6. Younger DS, Rowland LP, Latov N, et al. Lymphoma, motor neuron disease and amyotrophic lateral sclerosis: relation of high CSF protein content to paraproteinemia and clinical syndromes. *Neurology* 1990; 40:595-9.
7. Younger DS, Rowland LP, Larov NR, et al. Lymphoma, motor neuron diseases, and amyotrophic lateral sclerosis. *Ann Neurol* 1991; 29:78-86.
8. Jubelt B. Motor neuron diseases and viruses: poliovirus, retrovirus, and lymphomas. *Curr Opin Neurol Neurosurg* 1992; 5:655-8.

### Pathologic rupture of the spleen as the initial manifestation of acute lymphoblastic leukemia: an additional case

MARTA RODRÍGUEZ-LUACES, CARMEN JIMÉNEZ HERRAINZ, ANA LAFUENTE GUIJOSA, PABLO MATEOS RUBIO, JOSÉ MARÍA HERNÁNDEZ-BAYO,\* FERNANDO HERNÁNDEZ-NAVARRO

*Servicio de Hematología, \*Servicio de Radiología, Hospital "La Paz", Madrid, Spain*

**Pathological rupture of the spleen (PRS) is a rare, but well known complication of some hematological malignancies. In a recent review of the literature, Giagounidis et al.<sup>1</sup> identified 136 cases of pathologic rupture of the spleen since 1861. This number gives an idea of how seldom it occurs. In this review, 34% of the cases had occurred in acute leukemias, and 13% in acute lymphoblastic leukemias. In most cases, PRS occurs on the course of the disease. PRS as initial manifestation of ALL is a very rare feature: only six cases have been reported in the literature.<sup>2-6</sup> Before now, in our hospital, we had only seen one case of a patient suffering from chronic myelomonocytic leukemia who presented splenic rupture as the initial manifestation of this disease.<sup>7</sup> We now describe the seventh case, to our knowledge, of acute lymphoblastic leukemia presenting as pathologic splenic rupture.**

A 47-year-old man was admitted to our hospital in April of 1997 complaining of sudden onset of pain in the left upper abdomen, which radiated to the left shoulder (Kehr's sign). The patient had been well until the previous week of admission, when he began to have fever, malaise, sweats and fatigue. No previous trauma had occurred. On admission, his blood pressure was 110/80 mmHg and there was tachycardia of 110/min. His abdomen was tender and widely distended, and there were nausea and vomiting. Two nodes, 1.5 cm in diameter, were found in the left supraclavicular region. Laboratory analyses showed a leukocyte count of  $14.3 \times 10^9/L$  with 34% neutrophils, 60% lymphocytes,

5% monocytes, 0.3% eosinophils; hemoglobin was 8.1 g/dL and platelet count  $190 \times 10^9/L$ . Lactate dehydrogenase was 1978 U/L (range, 80-480 U/L). Coagulation tests were normal. The ultrasonographic findings were a spleen of 19 cm of longitudinal diameter with a heteroechoic lesion in upper pole. The abdominal computed tomography with contrast showed one zone of heterogeneous density in the spleen besides hemorrhagic liquid in peritoneal cavity, which confirmed the splenic rupture.

Splenectomy and a liver biopsy were performed. The patient's postoperative course was unremarkable. Pathologic examination of the spleen showed the splenic parenchyma densely infiltrated by lymphoid blasts; the normal architecture of the spleen had completely disappeared. Spleen blasts were positive for CD19 and CD20 monoclonal antibodies; liver biopsy showed leukemic infiltration of portal areas, with the blasts sharing the same immunophenotype.

A myelogram was performed concomitantly and acute lymphoblastic leukemia was diagnosed, L2 type, according to the FAB classification. The immunophenotype showed that bone marrow blasts were positive for CD19, CD20, CD22, CD10, CD34 and HLA-DR, and negative for CD3, CD4, CD5, CD7, CD13, CD14, CD15 and CD33. Bcr/abl translocation was not found. No central nervous system involvement was found. The patient has completed induction of a polychemotherapy regimen, BFM protocol,<sup>8</sup> with initially good response, and he has achieved complete remission after the induction therapy.

Giagounidis *et al.*,<sup>1</sup> have found that, apart from the three previously described pathogenic factors leading to rupture (splenic infiltration, splenic infarcts and coagulation disorders), male sex, adulthood, severe splenomegaly, and cytoreductive chemotherapy may be of relevance to the development of splenic rupture. The major pathogenic factor in this case seems to be splenic infiltration, since splenic infarcts and coagulation disorders were not found.

Altés *et al.*<sup>2</sup> tried to identify a possible association between pathologic spleen rupture with a particular genetic or phenotypic pattern. The findings encountered in their patient did not have any relevant diagnostic features. We have not either found any special immunophenotypic findings that could explain this particular form of presentation either.

In view of the results of Giagounidis series, splenectomy is advocated as the safest therapy. Nevertheless, Guth *et al.*<sup>9</sup> have recently proposed that a subset of hemodynamically stable patients can be successfully managed nonoperatively.

We present a further case of pathologic rupture of the spleen that warrants the need for differential diagnosis of hematological malignancies,<sup>10</sup> even though patient previous history do not suggest a hematological disorder.

### Correspondence

*Dra. Marta Rodríguez Luaces, Paseo del Prado 14, 3º Madrid, E-28014, Spain. Fax: international +34-1-7293898.*

### References

1. Giagounidis A, Burk M, Meckenstock G, Koch A, Schneider W. Pathologic rupture of the spleen in hematologic malignancies: two additional cases. *Ann Hematol* 1996; 73:297-302.
2. Altés A, Brunet S, Martínez C, et al. Spontaneous splenic rupture as the initial manifestation of acute lymphoblastic leukaemia: immunophenotype and cytogenetics. *Ann Hematol* 1994; 68:143-4.
3. Banerjee PK, Bhansali A, Dash S, Dash RJ. Acute lymphoblastic leukaemia manifesting with splenic rupture. *J Assoc Physicians India* 1990; 38:434-5.
4. Gorosquieta A, Pérez-Esquiiza E, Gastearena J. Rotura patológica de bazo asintomática como forma de presentación de leucemia linfoblástica aguda [letter]. *Sangre (Barc)* 1996; 41:261-2.
5. Johnson CS, Rosen PJ, Sheeham WW. Acute lymphocytic leukemia manifesting as splenic rupture. *Am J Clin Pathol* 1979; 72:118-21.
6. Wolfson IN, Croce EJ, Fite FK. Acute leukemia with rupture of the spleen as the initial symptom. *N Engl J Med* 1954; 251:735-7.
7. Jiménez MC, Larrocha C, Fernández de Castro M, Vilorio A. Rotura patológica del bazo en un caso de leucemia mielomonocítica crónica [letter]. *Sangre* 1991; 36:168.
8. Hoelzer D, Thiel E, Ludwig WD, et al. The German multicenter trials for treatment of acute lymphoblastic leukemia in adults. *Leukemia* 1992; 6(Suppl 2):175.
9. Guth A, Patcher H, Jacobowitz G. Rupture of the pathologic spleen: is there a role for nonoperative therapy? *J Trauma* 1996; 41:214-8.
10. Lerede T, Bassan R, Rossi A, et al. Therapeutic impact of adult-type acute lymphoblastic leukemia regimens in B-cell/L3 acute leukemia and advanced-stage Burkitt's lymphoma. *Haematologica* 1996; 81:442-9.