

Simultaneous ischemic and hemorrhagic lesions of the brain detected by CT scan in a patient with thrombotic thrombocytopenic purpura

FABIO GUZZINI, ADELE CONTI,* FABIO ESPOSITO^o

Department of Emergency Medicine, *Radiology Service, ^o2nd Division of Surgery, Ospedale di Saronno (VA), Italy

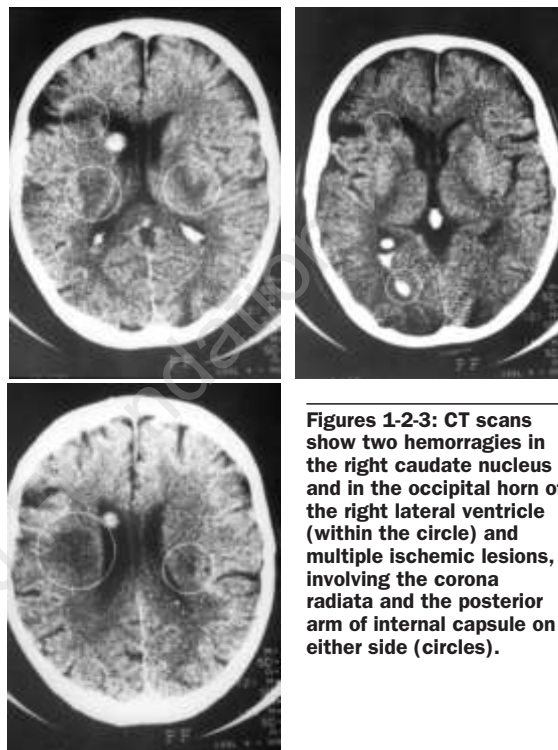
Although overt clinical abnormalities are present, brain CT scans may be normal in patients with thrombotic thrombocytopenic purpura (TTP). Nonetheless a study from a large series at the Mayo Clinic showed that CT can predict outcome, since abnormal findings are related with more severe and nonreversible neurological defects and with a significant higher mortality.¹

A 45-year-old man was admitted because of intense pain in the neck and left shoulder. His remote clinical history included a right hemicolectomy, performed 4 months earlier for adenocarcinoma, and followed by cyclic chemotherapy with 5-fluorouracil and folinic acid. At the time of surgery no metastatic involvement was found.

Four days after admission the patient manifested confusion, behavioral changes and agitation, which rapidly worsened to stupor and coma. A mild left hemiparesis was also noticed. At the same time he became icteric and showed multiple hemorrhages (petechiae and cutaneous hematomas, oral bleeding, hematuria). Blood parameters revealed increasing anemia (Hb from 13.6 to 8.1 g/dL), and thrombocytopenia (till $19 \times 10^9/L$), bilirubin 4 mg/dl (indirect 3.6), lactic dehydrogenase 3.875 U/L, negative Coombs' tests and renal function impairment, while PT, PTT, fibrinogen and antithrombin III levels remained normal and only a slight increase of fibrinogen degradation products was observed (80 mg/L). CT scans were performed on day 5, 6 and 9 from admission. All three detected multiple simultaneous ischemic and hemorrhagic lesions (intraparenchymal and ventricular) in both cerebral hemispheres (Figures 1,2,3) before any treatment.

Starting the 5th day, the patient was treated with plasma-exchange, dexamethasone 8 mg b.i.d. and 250-mg of lysine-acetylsalicylate, but his clinical condition progressively worsened until death on the 11th day. Neither chest and abdominal CT nor skeletal radionuclide scans showed a metastatic lesion, nevertheless the titer of plasma carcinoembryonic antigen (CEA) was elevated (over 70 ng/mL). Autopsy was not performed.

The patient herein described showed the typical features allowing the diagnosis of TTP.^{2,3} CT scans



Figures 1-2-3: CT scans show two hemorrhages in the right caudate nucleus and in the occipital horn of the right lateral ventricle (within the circle) and multiple ischemic lesions, involving the corona radiata and the posterior arm of internal capsule on either side (circles).

detected the presence of both ischemic and hemorrhagic lesions, before any anticoagulant or antiplatelet treatment was started. This finding is extremely rare: to the best of our knowledge it has never been reported in the literature. Ocular involvement has been previously described in this journal.⁴

References

1. Kay AC, Salberg LA, Nichols DA, Pettit RM. Prognostic significance of computed tomography of the brain in thrombotic thrombocytopenic purpura. *Mayo Clin Proc* 1991; 66:602-7.
2. Kwaan HC. Clinicopathological features of thrombotic thrombocytopenic purpura. *Semin Hematol* 1987; 24:71-81.
3. Bobbio-Pallavicini E, Gugliotta L, Centurioni R, et al. Antiplatelet agents in thrombotic thrombocytopenic purpura (TTP). Results of a randomized multicenter trial by the Italian Cooperative Group for TTP. *Haematologica* 1997; 82:429-35.
4. Bobbio-Pallavicini E, Porta C, Brocchieri A, Saporiti A, Tacconi F. Ocular involvement in acute thrombotic thrombocytopenic purpura. *Haematologica* 1995; 80:194-5.