

# Kaposi sarcoma herpesvirus viral load as a biomarker for leptomeningeal involvement by primary effusion lymphoma

Kathryn Lurain,<sup>1</sup> Ramya Ramaswami,<sup>1</sup> Vickie Marshall,<sup>2</sup> Elena M. Cornejo Castro,<sup>2</sup> Nazzarena Labo,<sup>2</sup> Wendell Miley,<sup>2</sup> Kyle Moore,<sup>2</sup> Romin Roshan,<sup>2</sup> Ralph Mangusan,<sup>1</sup> Elaine S. Jaffe,<sup>3</sup> Stefania Pittaluga,<sup>3</sup> Hao-Wei Wang,<sup>3</sup> Mark Roth,<sup>3</sup> Armando C. Filie,<sup>3</sup> Thomas S. Uldrick,<sup>1</sup> Denise Whitby<sup>2</sup> and Robert Yarchoan<sup>1</sup>

<sup>1</sup>HIV & AIDS Malignancy Branch, Center for Cancer Research (CCR), NCI, Bethesda, MD; <sup>2</sup>Viral Oncology Section, AIDS and Cancer Virus Program, Frederick National Laboratory for Cancer Research, Frederick, MD and <sup>3</sup>Laboratory of Pathology, CCR, NCI, Bethesda, MD, USA

Correspondence: K. LURAIN - [kathryn.lurain@nih.gov](mailto:kathryn.lurain@nih.gov)

<https://doi.org/10.3324/haematol.2022.281472>

**Supplementary Table 1.** Characteristics of patients with primary effusion lymphoma at time of first cerebrospinal fluid assessment

Patient	Age (years)	Sex	Race/Ethnicity	PEL Type	EBV tumor status	CSF disease	CSF KSHV copies/mL	CSF EBV copies/mL	PBMC KSHV copies/10 <sup>6</sup> cells	Plasma KSHV copies/mL	HIV copies/mL	CD4 <sup>+</sup> T cells/ $\mu$ L	CSF white blood cells/mm <sup>3</sup>	CSF red blood cells/mm <sup>3</sup>	CSF protein mg/dL
1	55	M	White	cavitary	+	+	391	1	1	11,500	0	363	3	0	39
2	49	M	Black	extracavitary	+	+	222,000	1	0	15,000	0	262	32	2	87
3	35	M	Black	cavitary/ extracavitary	+	+	360,000	1	3,158	200	0	310	6	98	96
4	36	M	White	cavitary	+	+	215,000	70000	5,122	24,500	0	143	2	56	28
5*	56	M	White	extracavitary	-	-	192	0	6,984,127	-	0	466	17	1	57
6	55	M	White	extracavitary	+	-	0	0	186	650	0	48	1	3	33
7	55	M	White	cavitary	unknown	-	0	-	4167	1,100	53	250	2	31	-
8	44	M	White	extracavitary	+	-	0	0	333	6,000	134,527	377	26	3	91
9	33	F	Black	extracavitary	+	-	0	0	10,667	9,500	0	15	0	116	50
10	26	M	Black	extracavitary	+	-	0	800	0	-	245	152	6	2	52

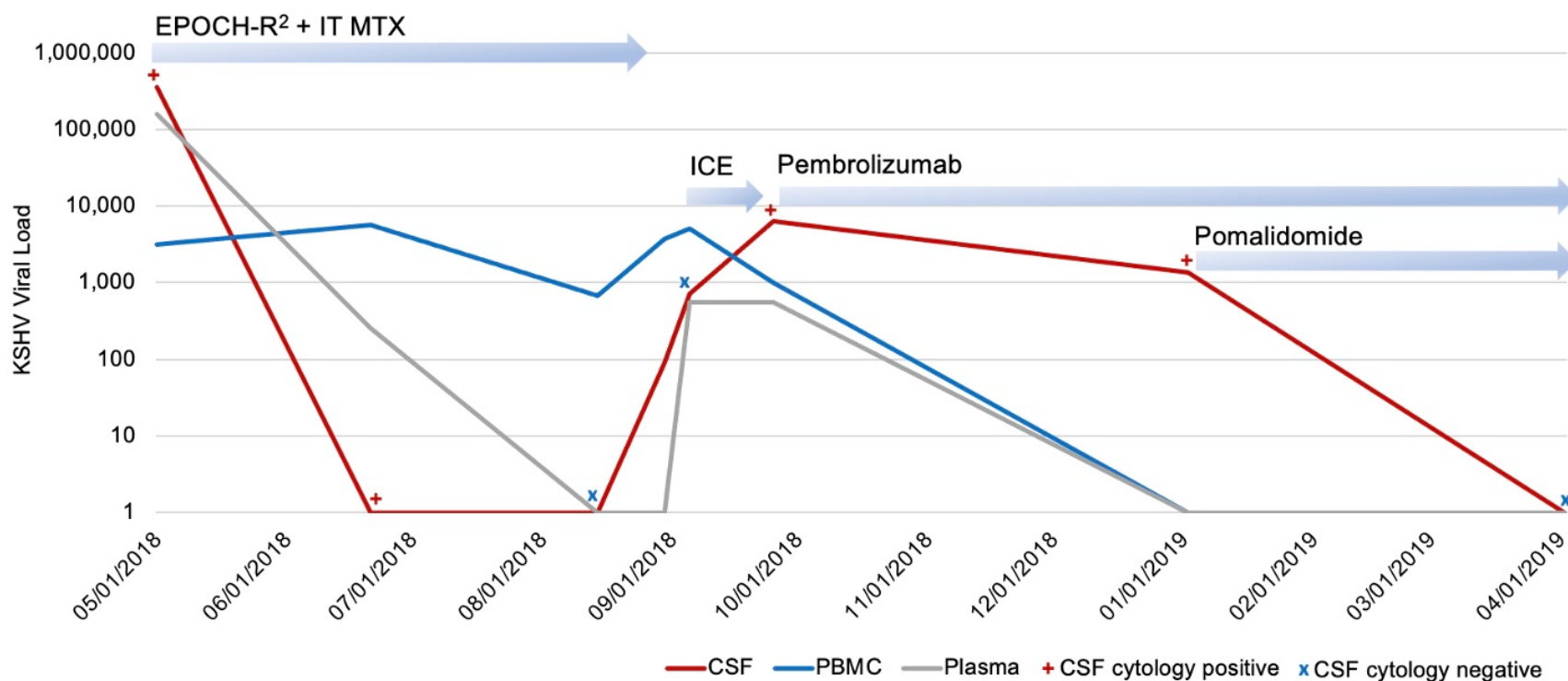
11	70	M	White	cavitory	-	-	0	0	1	34,000	17,064	175	3	5	38
12	38	M	White	cavitory	+	-	0	360	19,551	16,500	10,082	401	1	0	36
13	59	M	White	extracavitory	+	-	0	0	386	8,000	399	358	2	0	29
14	59	M	White	cavitory	unknown	-	0	0	0	1	0	187	0	59	21
15	32	M	White/ Hispanic	extracavitory	+	-	0	1,950	306	2,300	0	170	7	0	56
16	50	M	White	extracavitory	+	-	0	0	1	4,950	3318	200	4	35	63
17	42	M	Black	cavitory	+	-	0	1,200	2,600,000	43,000	0	10	7	0	30
18†	43	M	White/ Hispanic	extracavitory	+	-	960	8,100	1	70,000	20	218	3	7	55
19	27	M	Black	cavitory	+	-	0	930	1,500	650	663	9	33	0	30
20	66	M	White	cavitory	unknown	-	0	0	1	0	0	161	0	14	42
21	29	M	Black	extracavitory	+	-	0	0	381	750	0	867	1	5900	-
22	29	M	Black	cavitory	+	-	0	0	102,857	50,000	186	304	3	0	17
23	36	F	Black	cavitory	+	-	1	500	13,333	1,150	657	52	2	36	30

24	53	M	Black	cavitary	-	-	0	0	125	1,850	0	48	0	0	27
25	32	M	White	cavitary	-	-	0	0	1,833	1	121	4	2	0	48
26	56	M	Black	extracavitary	+	-	0	1	1	150	522	272	1	0	24

\*This patient had negative CSF cytology at first CSF sampling but developed CSF-PEL at the next CSF sampling 2 weeks later.

†This patient had multiply relapsed PEL, and this CSF sampling was not performed at treatment baseline. The patient was subsequently not seen again at our institution after this CSF sampling with negative cytology and therefore no further follow-up of the elevated KSHV VL was performed.

**Supplemental Figure 1.** Changes over time in CSF, PBMC, and plasma KSHV viral load in Patient 17 with cavitory and extracavitary PEL involving the CSF with different treatments targeting both systemic and CSF disease. Times of positive CSF cytology are also indicated. The patient's disease had an initial partial response to EPOCH-R<sup>2</sup> and IT MTX with progression in September 2018 and then partial remission after 1 cycle of ICE, which was discontinued due to severe cytopenias. Pembrolizumab was initiated for systemic therapy with later addition of pomalidomide to treat CSF disease. The patient's systemic disease went into remission in January 2019 and CSF disease went into remission in April 2019 and remains in remission.



CSF indicates cerebrospinal fluid; ICE, ifosfamide, carboplatin, etoposide; IT MTX, intrathecal methotrexate; EPOCH-R<sup>2</sup>, dose-adjusted infusional etoposide, vincristine, doxorubicin with cyclophosphamide, prednisone, rituximab, and lenalidomide; KSHV, Kaposi sarcoma herpesvirus