

Serum vascular endothelial growth factor is associated with cardiovascular involvement and response to therapy in Erdheim-Chester disease

Anaïs Roeser,¹ Marine Bravetti,² Lida Dong,³ Levi-Dan Azoulay,¹ Frederic Charlotte,³ Makoto Miyara,⁴ Pascale Ghillani-Dalbin,⁴ Jean-François Emile,⁵ Fadwa El Kouari,⁶ Hamza Ouni,⁷ Jean-Marc Lacorte,⁷ Isabelle Brocheriou,³ Zahir Amoura,¹ Fleur Cohen-Aubart¹ and Julien Haroche¹

¹Sorbonne Université, Assistance Publique Hôpitaux de Paris, Hôpital de la Pitié-Salpêtrière, Service de Médecine Interne 2, Centre National de Référence des Histiocytoses, Paris;

²Sorbonne Université, Assistance Publique Hôpitaux de Paris, Hôpital de la Pitié-Salpêtrière, Service de Radiologie Cardiovasculaire et Interventionnelle, Paris; ³Sorbonne Université, Assistance Publique Hôpitaux de Paris, Hôpital de la Pitié-Salpêtrière, Service d'Anatomie et Cytologie Pathologiques, Paris; ⁴Sorbonne Université, Assistance Publique Hôpitaux de Paris, Hôpital de la Pitié-Salpêtrière, Département d'Immunochimie, Paris; ⁵EA4340, Université Versailles-Saint Quentin, Assistance Publique Hôpitaux de Paris, Hôpital Ambroise Paré, Département de Pathologie, Boulogne; ⁶Sorbonne Université, Assistance Publique Hôpitaux de Paris, Unité Fonctionnelle de Production des Médicaments et des Anticancéreux Injectables, Hôpital Pitié-Salpêtrière, Paris and ⁷Sorbonne Université, Assistance Publique Hôpitaux de Paris, Service de Biochimie Endocrinienne et Oncologique, Hôpital Pitié-Salpêtrière, Paris, France

Correspondence: J. Haroche
julien.haroche@aphp.fr

Received: January 29, 2022.

Accepted: August 18, 2022.

Prepublished: August 25, 2022.

<https://doi.org/10.3324/haematol.2022.280755>

©2023 Ferrata Storti Foundation

Published under a CC BY-NC license

SUPPLEMENTARY MATERIAL

Table S1. Cardiac involvement of Erdheim-Chester disease patients at initial cardiac MRI and progression on follow-up images

	Initial (n=45)	Follow-up			
		Complete regression	Partial regression	Stability	Progression
Cardiac involvement, n (%)	45/45 (100)	6/45 (13.3)	25/45 (55.6)	12/45 (26.7)	2/45 (4.4)
Pulmonary artery, n (%)	5/45 (11.1)	0/5	2/5	3/5	0/5
Thoracic aorta, n (%)	31/45 (68.9)	0/31	0/31	31/31	0/31
Right atrium pseudotumor, n (%)	30/45 (66.7)	5/30	18/30	7/30	0/30
Right atrioventricular septum, n (%)	37/45 (82.2)	6/37	21/37	9/37	1/37
Right atrium, n (%)	29/45 (64.4)	11/29	9/29	7/29	2/29
Free wall of the right atrium, n (%)	20/45 (44.4)	7/20	6/20	6/20	1/20
Posterior wall of the right atrium, n (%)	22/45 (48.9)	8/22	6/22	7/22	1/22
Inter-atrial septum, n (%)	22/45 (48.9)	9/22	5/22	7/22	1/22
Left atrioventricular septum, n (%)	4/45 (8.9)	2/4	1/4	1/4	0/4
Left atrium, n (%)	6/45 (13.3)	3/6	2/6	1/6	0/6
Late gadolinium enhancement*, n (%)	40/45 (88.9)	29/39		10/39	0/39
Pericardium, n (%)	21/45 (46.7)	4/21	9/21	7/21	1/21
Pericardial effusion, n (%)	20/45 (44.4)	3/20	8/20	6/20	2/20
Pericardial contrast enhancement, n (%)	13/45 (28.9)	2/13	4/13	7/13	1 emergence
Pericardial thickening, n (%)	15/45 (33.3)	3/15	4/15	8/15	1 emergence
Posterior mediastinum, n (%)	22/45 (48.9)	1/22		21/22	0/22
Dyskinesia*, n (%)	14/45 (31.1)	9/13	1/13	3/13	0/14
Decreased tricuspid annular plane systolic excursion (TAPSE)*, n (%)	15/45 (33.3)	8/14	2/14	4/14	0/15

*For one patient, re-evaluation was based on a CT-scan due to pacemaker implantation, and contrast enhancement, dyskinesia and TAPSE could no longer be evaluated.

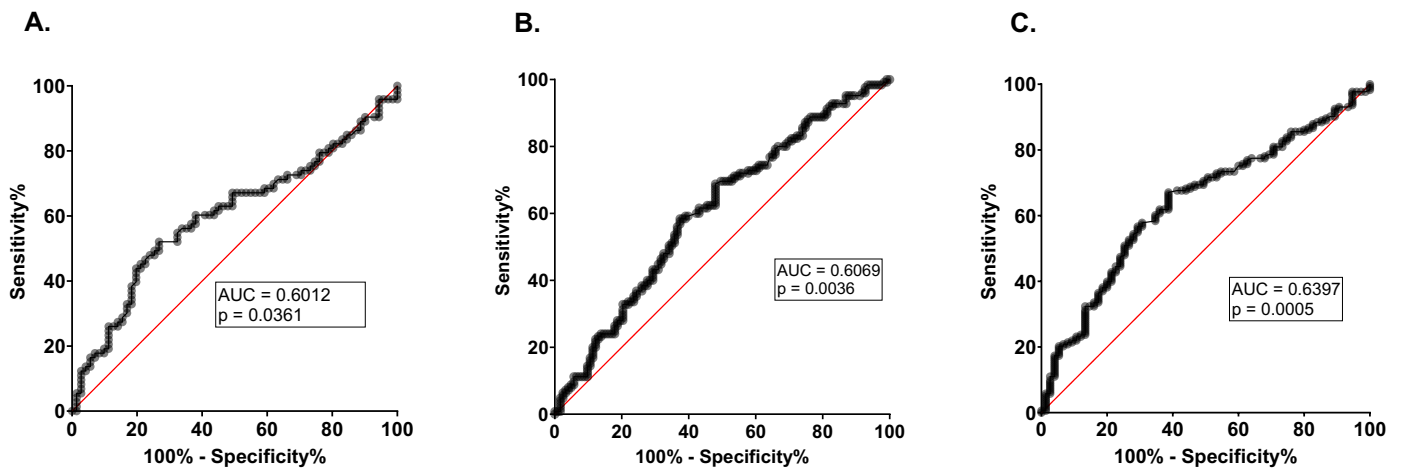


Figure S1. Receiver operating characteristic (ROC) curves for prediction based on serum VEGF concentration at first evaluation: A - vascular involvement (gold standard: vascular imaging); B - cardiac involvement (gold standard: cardiac imaging, preferably MRI, replaced by CT-scan when contraindicated); C - cardiac or vascular involvement in Erdheim-Chester Disease.

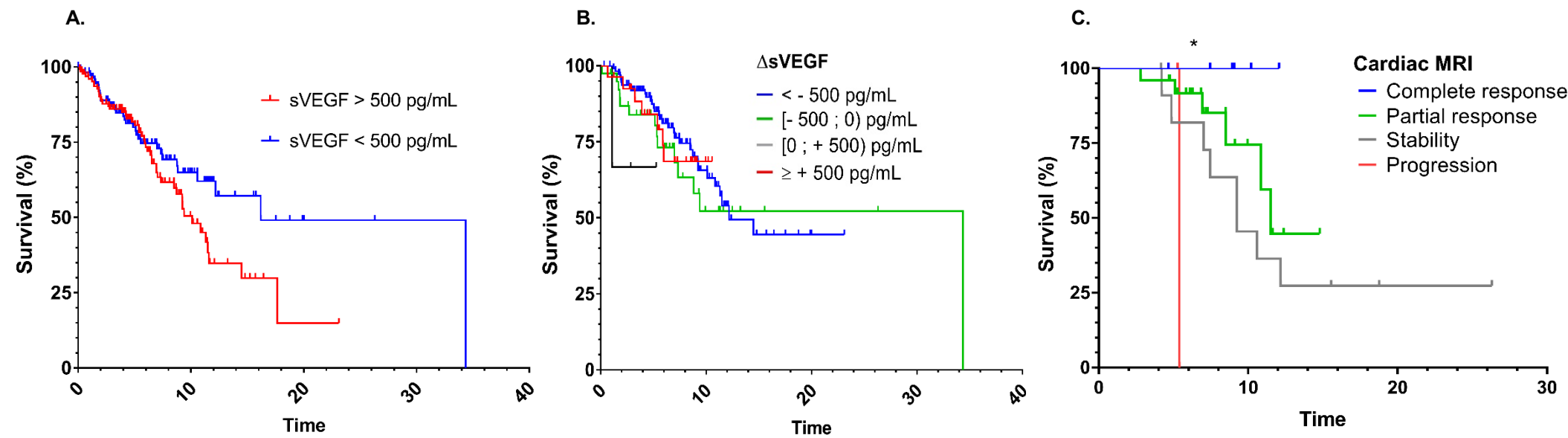


Figure S2. Survival curves of Erdheim-Chester disease patients. A - with and without high (> 500pg/mL) initial serum VEGF concentrations; B - according to the change in serum VEGF concentration (Δ sVEGF) on treatment; C - with cardiac involvement according to response to treatment assessed by cardiac magnetic resonance imaging (MRI).